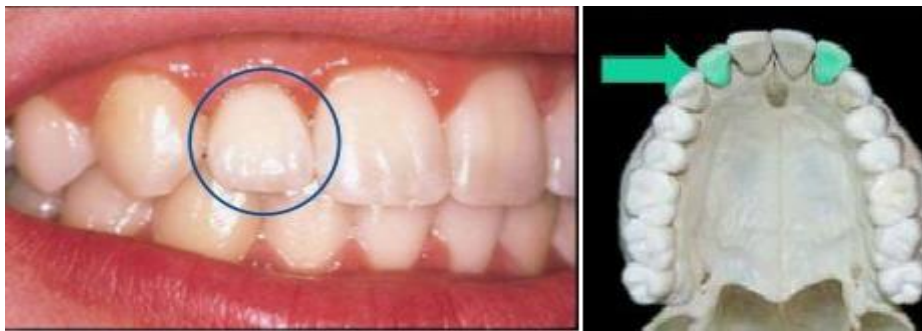

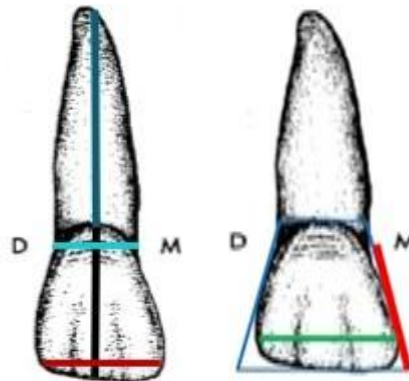
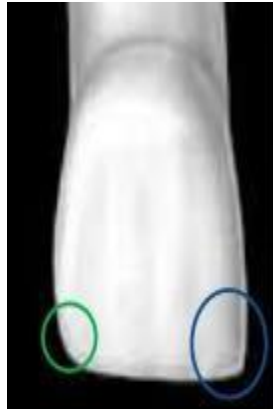
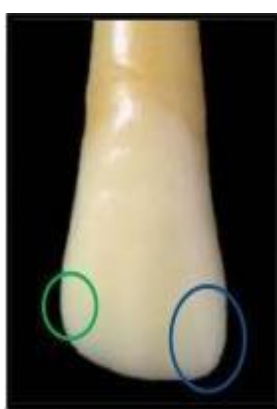Maxillary lateral incisor

The maxillary lateral incisor supplements the central incisor in function, so the crowns bear a close resemblance. The lateral incisor is smaller in all dimensions except root length.



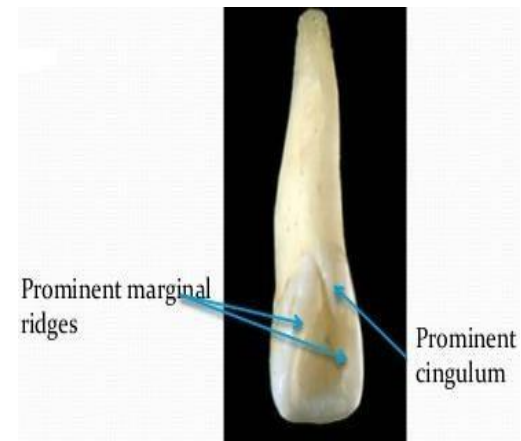
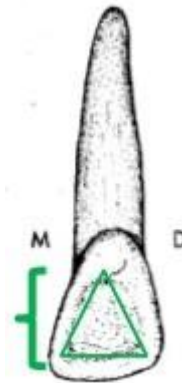
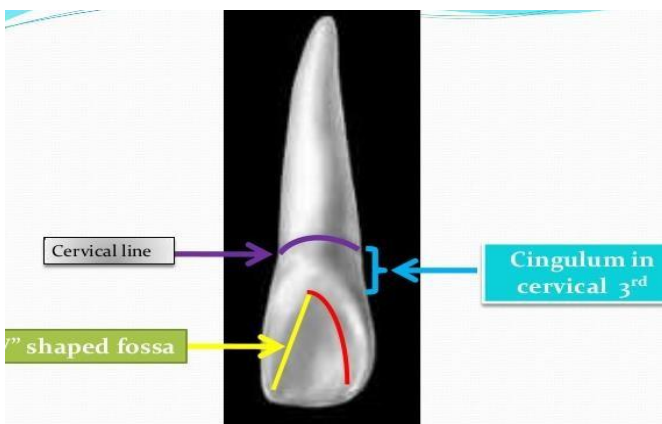
Labial Aspect

- 1- Lateral incisor has more curvature, with a rounded incisal ridge.
- 2- Lateral incisor rounded incisal angle mesially and distally. And it is more rounded distally than the central incisor.
- 3- The crown is smaller in all dimensions than the central incisor.
- 4- The labial surface of the crown is more convex than that of the central incisor.
- 5- Mesio-distally about 2mm narrower than the central incisor, this tooth is relatively narrow.
- 6- This tooth is shorter cervico-incisally.
- 7- Contact point mesially at the junction of the middle third and incisal third while distally at the center of the middle third.



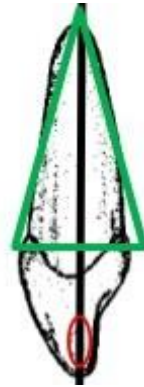Lingual Aspect

1. Mesial and distal marginal ridge is well marked.
2. The cingulum is usually prominent with a tendency toward deep development grooves with the lingual fossa.
3. The lingual fossa is more concave.
4. Tooth tapers toward the lingual.
5. Developmental groove fin at the side of the cingulum, usually on the distal side.



Mesial Aspect


1. The mesial aspect of the maxillary lateral incisor is similar to that of the central incisor except that the root appears longer.
2. The crown is shorter.
3. The curvature of the cervical line is marked in the direction of the incisal ridge and less than of the central incisor.



Distal Aspect

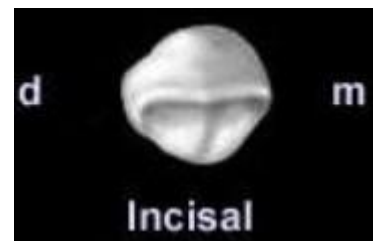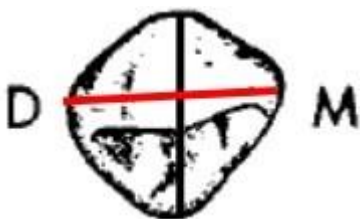1-Width of the crown distally appears thicker than on the mesial aspect from the marginal ridge to the labial face because of the placement of a crown on the arch.

2-cervical line curvature is usually less in-depth than in the mesial Aspect.

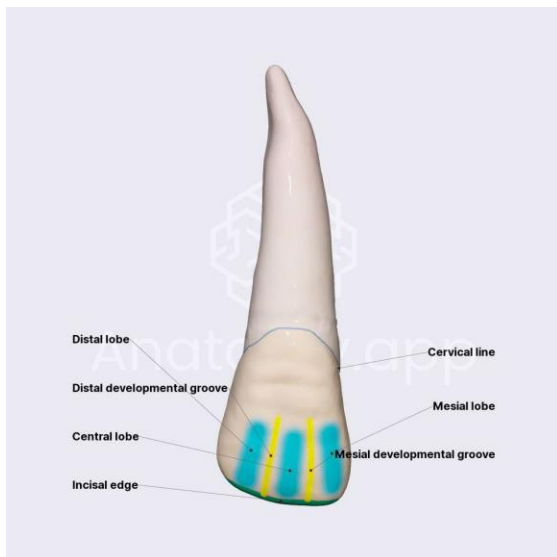


Incisal Aspect

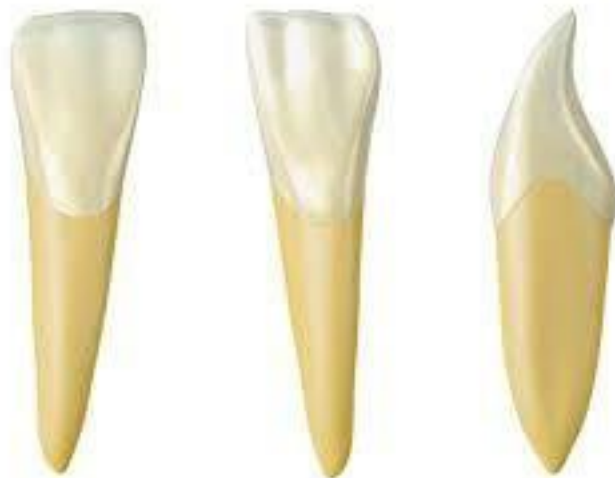- 1- It is similar to that of the incisal aspect of the maxillary central incisor.
- 2- All maxillary lateral incisor exhibits more convexity labially and lingually from the incisor aspect than the maxillary central incisor.



MAXILLARY LATERAL INCISOR	MANDIBULAR LATERAL INCISOR
1. <i>Rectangular, broader crown</i>	1. Long and narrower mesiodistally
2. <i>Mesial and distal out line is convex</i>	2. Long Mesial and distal out line is straight
3. <i>Mesioincisal and distoincisal angle is rounded</i>	3. Mesioincisal and distoincisal angle is straight and sharp
4. <i>Prominent marginal ridge</i>	4. Less prominent marginal ridge
5. <i>Fossa will be deep and 'V' shaped</i>	5. No fossa
6. <i>More prominent cingulum</i>	6. Less prominent cingulum



Maxillary Lateral Incisor



Mandibular Lateral Incisor

THANK YOU