

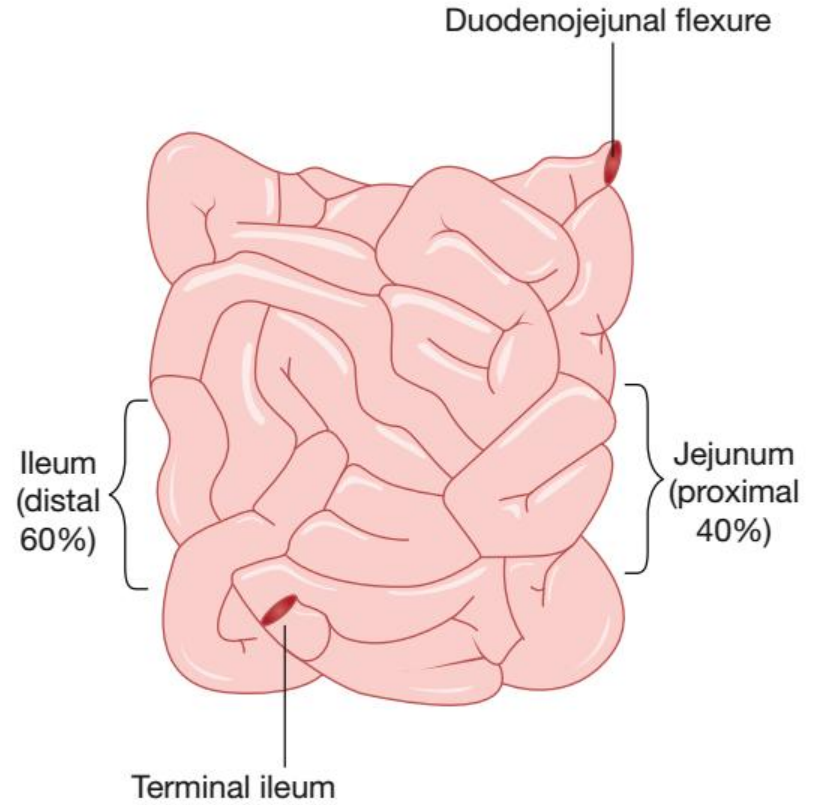
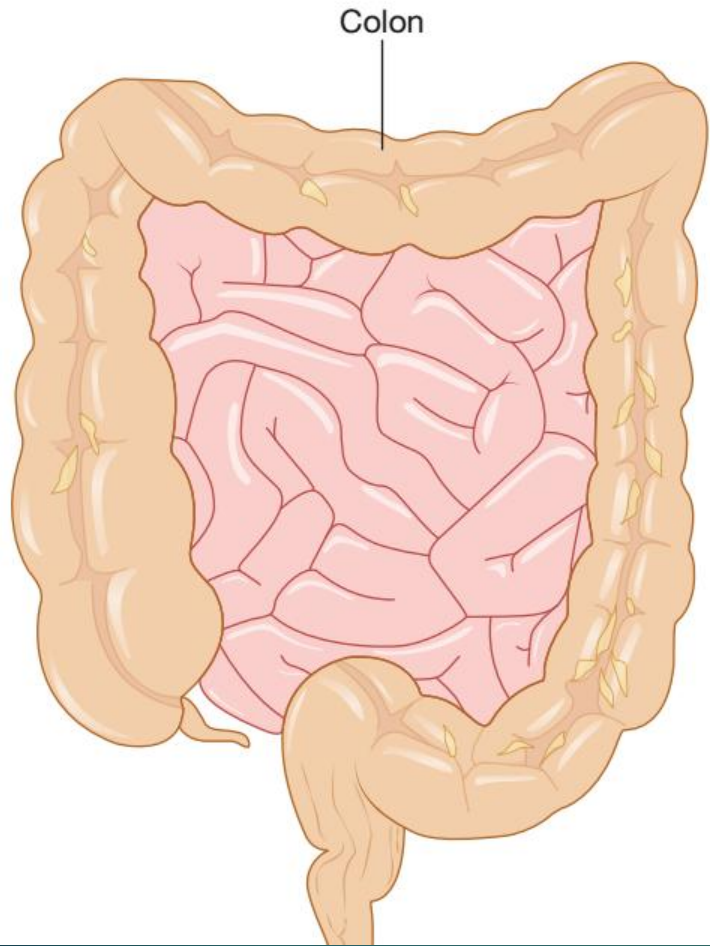



# The small intestine

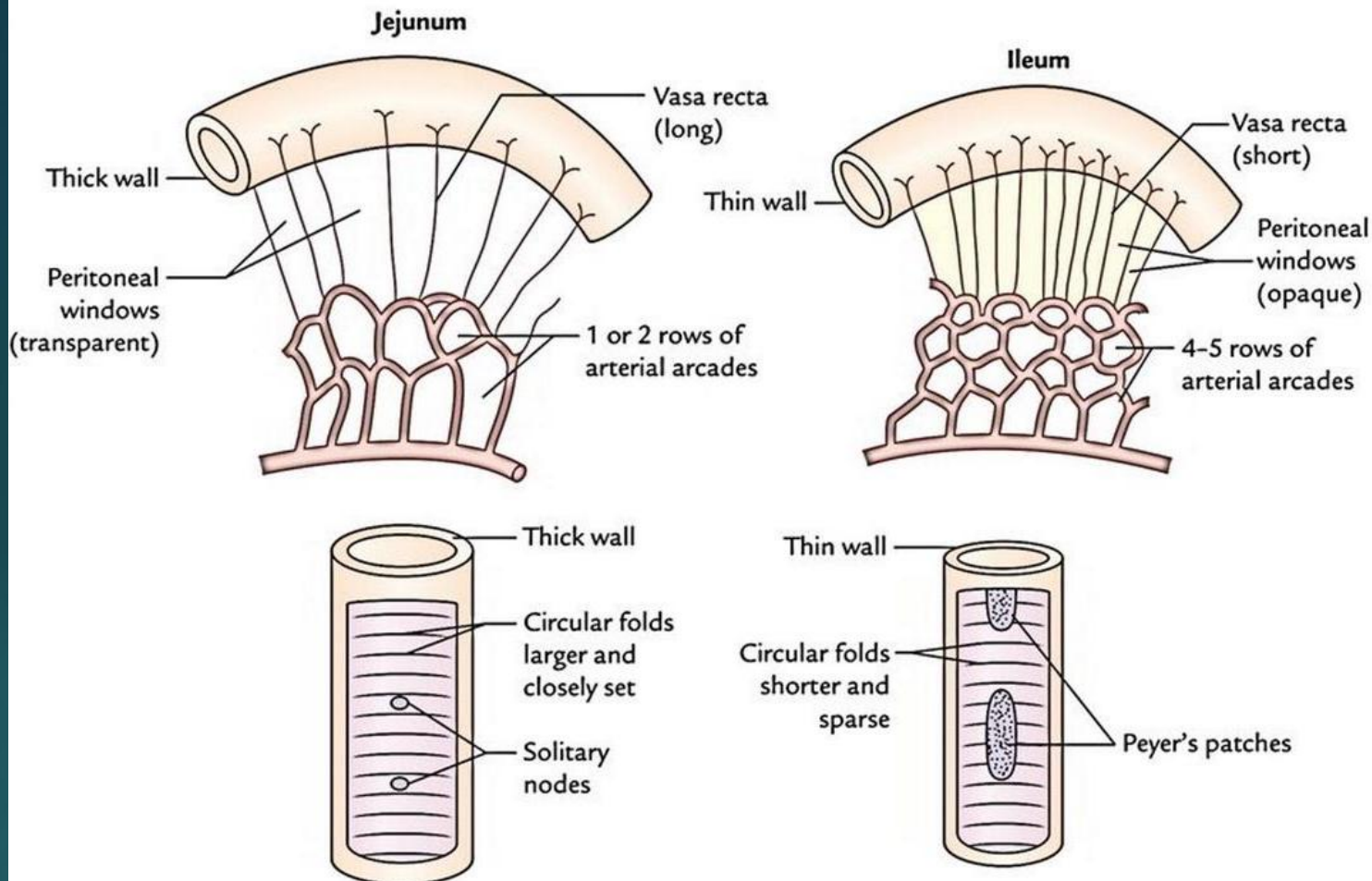
By Dr.Hussein Safaa  
Plastic Surgeon

# ANATOMY OF THE SMALL INTESTINE

- ▶ The length of the small bowel varies from 3 to 8.5 m between the duodenojejunal (DJ) flexure to the ileocaecal valve.
- ▶ It is difficult to establish the length of the small intestine, and estimates at surgery, at postmortem and during radiological investigations may vary widely, even in the same individual.
- ▶ In addition, there is considerable inter-individual variability and the small intestine has been said to be longer in men.



- 
- ▶ The proximal 40% of the small intestine is referred to as the jejunum; the remainder is the ileum.
  - ▶ There is no clear demarcation between jejunum and ileum, but the small bowel does change gradually in character from proximal to distal.



## The jejunum

1. a wider diameter.
2. a thicker wall.
3. more prominent mucosal folds (valvulae conniventes).

## the ileum

1. has a thicker, more fatty mesentery.
2. more complex arterial arcades.
3. contains larger aggregates of lymph nodes (Peyer's patches).

# INFLAMMATORY BOWEL DISEASE

## Crohn's disease (regional enteritis)

- ▶ CD is characterized by a chronic full-thickness inflammatory process that can affect any part of the gastrointestinal tract from the lips to the anal margin.
- ▶ It is slightly more common in women than in men, and is most commonly diagnosed between the ages of 25 and 40 years. There is a second peak of incidence around the age of 70 years.



# Aetiology

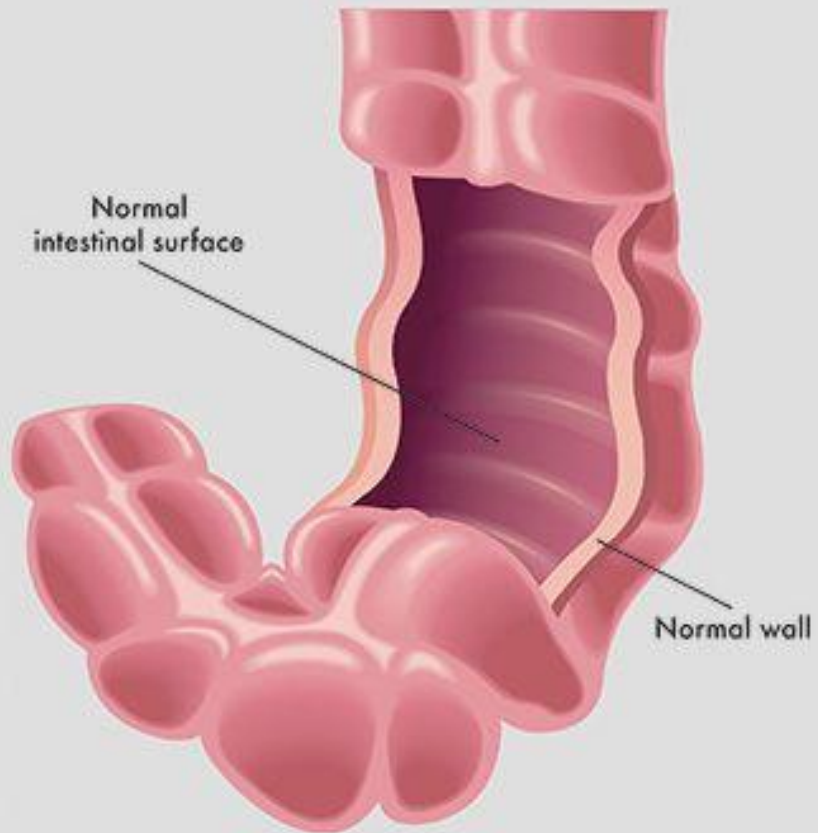
- ▶ It is incompletely understood but is thought to involve a complex interplay of genetic and environmental factors.
- ▶ Although CD shares some features with chronic infection, no causative organism has ever been demonstrated.
- ▶ A wide variety of foods have been implicated, in particular a diet high in refined foodstuffs, but none conclusively.
- ▶ An association with high levels of sanitation in childhood has been suggested.
- ▶ Smoking increases the relative risk of CD three-fold.
- ▶ Genetic factors are also clearly extremely important.
- ▶ Approximately 10% of patients have a first-degree relative with the disease, and concordance has been shown to approach 50% in monozygotic twins.

# Pathology

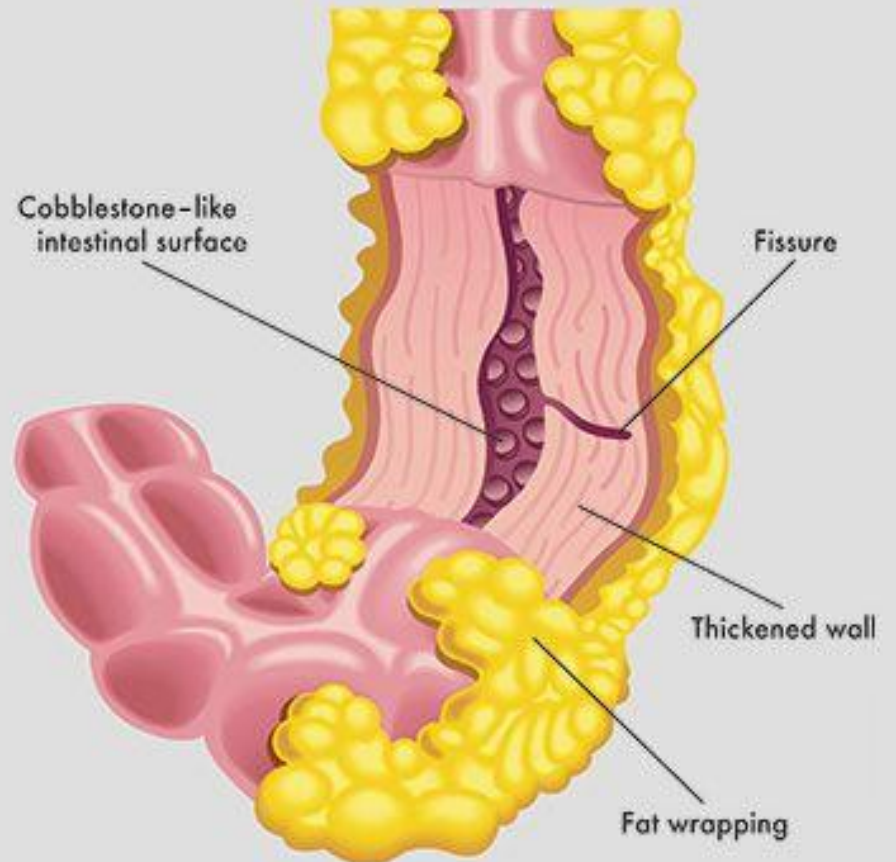
- ▶ The terminal ileum is most commonly involved (65%), either in isolation or in combination with colonic disease.
- ▶ The stomach and duodenum are affected in around 5%.
- ▶ Macroscopically, resection specimens show fibrotic thickening of the intestinal wall with narrowing of the lumen and fat wrapping (encroachment of mesenteric fat around the bowel).
- ▶ There is usually dilated bowel just proximal to the stricture and deep mucosal ulcerations with linear or snake-like patterns in the strictured area itself.
- ▶ Edema in between the ulcers gives rise to a **cobblestone** appearance of the mucosa.



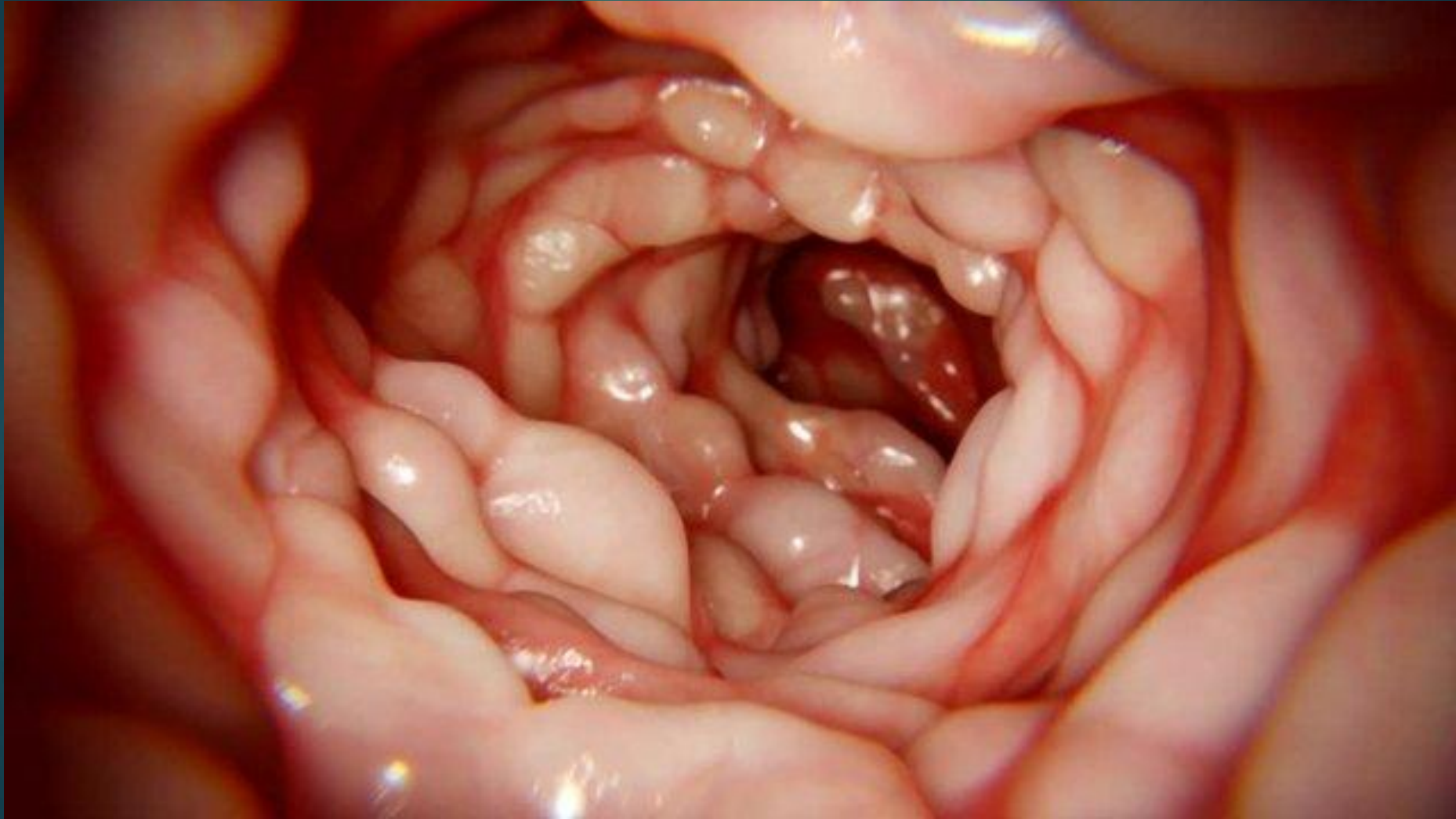## Normal Intestine



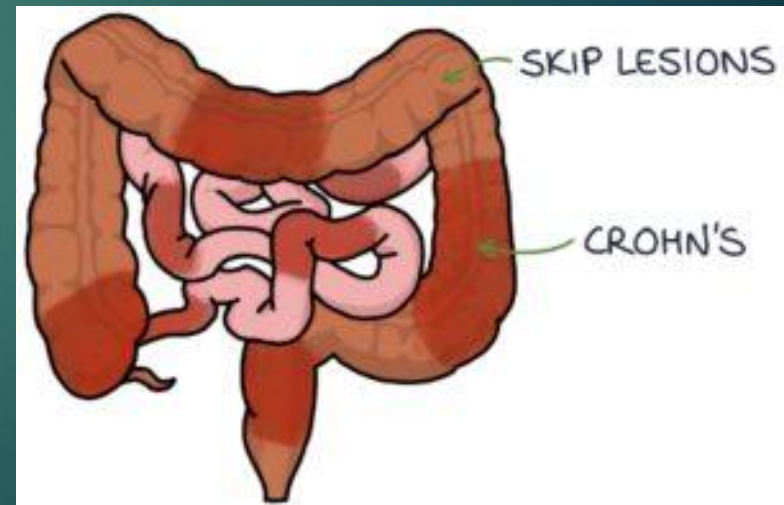
## Crohn's Disease




**COBBLESTONE** APPEARANCE OF THE MUCOSA.



- ▶ The transmural inflammation (which is a characteristic feature of CD) may lead to segments of bowel becoming adherent to each other and to surrounding structures, inflammatory masses with mesenteric abscesses and fistulae into adjacent organs.
- ▶ CD is characteristically discontinuous, with inflamed areas separated by normal intestine, so-called '**skip**' lesions.




- 
- ▶ Microscopically, there are focal areas of chronic inflammation involving all layers of the intestinal wall with lymphoid aggregates.
  - ▶ Non-caseating giant cell granulomas are found in 60% of patients and when present clearly allow a confident diagnosis of CD.
  - ▶ Multifocal arterial occlusions are found in the muscularis propria, which is thickened.
  - ▶ There may be nerve cell hyperplasia and there is deep, fissuring ulceration within affected areas.
  - ▶ Characteristically, and unlike in UC, there may be completely normal areas immediately next to areas of severe inflammation.

# Clinical features

- ▶ Presentation depends on the pattern of disease.
- ▶ signs resembling those of acute appendicitis.
- ▶ free perforation of the small intestine, resulting in a local or diffuse peritonitis.
- ▶ fulminant colitis.
- ▶ CD more commonly presents with features of chronicity.
- ▶ Small bowel CD is often characterized by abdominal colicky pain, may be postprandial, and mild diarrhea extending over many months occurring in bouts.
- ▶ A tender mass may be palpable in the right iliac fossa. Intermittent fevers, secondary anemia and weight loss are common.



- 
- ▶ After months of repeated attacks characterized by acute inflammation, the affected area of intestine begins to narrow with fibrosis, causing more chronic obstructive symptoms.
  - ▶ With progression of the disease, adhesions and transmural fissuring, intra-abdominal abscesses and fistulae may develop.
  - ▶ **Fistulation** may occur into adjacent loops of bowel (enteroenteric or interloop fistulae).
    1. ileosigmoid fistulation.
    2. ileovesical) or the female genital tract.
    3. enterocutaneous fistulation



# EXTRAIESTINAL MANIFESTATIONS

## Extraintestinal manifestations of Crohn's disease

- Related to disease activity
  - Erythema nodosum
  - Pyoderma gangrenosum
  - Arthropathy
  - Eye complications (iritis/uveitis)
  - Aphthous ulceration
  - Amyloidosis
- Unrelated to disease activity
  - Gallstones
  - Renal calculi
  - Primary sclerosing cholangitis
  - Chronic active hepatitis
  - Sacroiliitis

## Principles of management of Crohn's disease (CD)

- Close liaison between physician and surgeon is crucial
- Medical therapy should always be considered as an alternative to surgery, although surgery should not be delayed when a clear indication for surgery exists
- Patients must be optimised as far as possible prior to surgery, and this may require preoperative total parenteral nutrition
- CD is a chronic relapsing disease with a high likelihood of reoperation; the surgeon must take every reasonable effort to preserve bowel length and sphincter function

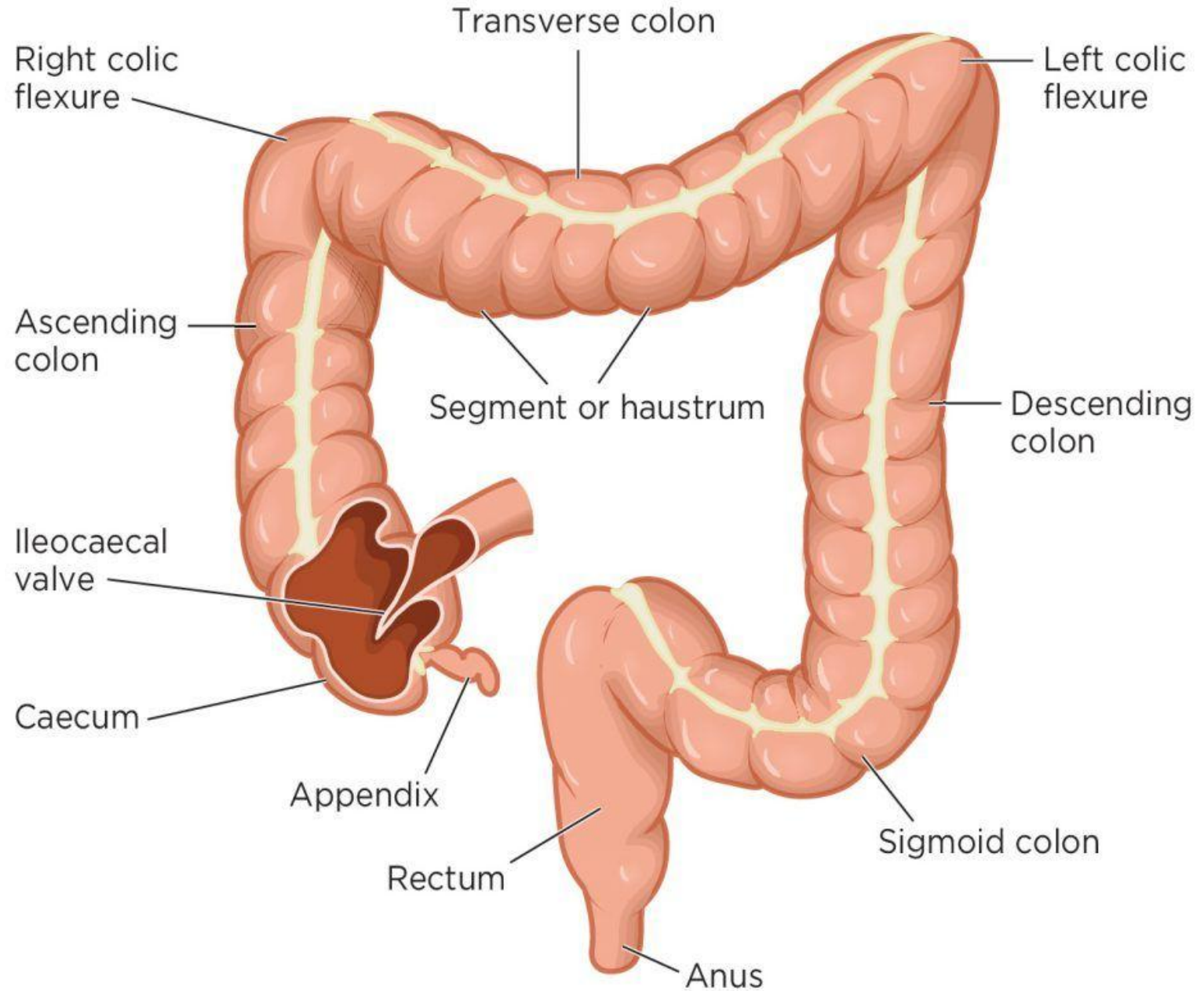
# INDICATIONS FOR SURGERY

- ▶ recurrent intestinal obstruction;
- ▶ persistent or, less commonly, massive acute bleeding;
- ▶ free perforation of the bowel;
- ▶ failure of medical therapy;
- ▶ steroid dependent disease;
- ▶ intestinal fistula;
- ▶ perianal disease (abscess, fistula, stenosis);
- ▶ malignant change (notably in the colon and less commonly as a complication of small bowel disease).

# Large Intestine

- ▶ The large intestine is about 1.5 meters long and is divided into the following regions:
- ▶ **Cecum**
  - ▶ The beginning of the large intestine, located in the right lower quadrant.
  - ▶ Contains the appendix, a narrow, blind-ended tube.
- ▶ **Colon**
  - ▶ **Ascending Colon:** Extends upward from the cecum to the hepatic flexure.
  - ▶ **Transverse Colon:** Crosses the abdomen from right to left.
  - ▶ **Descending Colon:** Runs down the left side of the abdomen.
  - ▶ **Sigmoid Colon:** An S-shaped segment that connects to the rectum.
- ▶ **Rectum and Anal Canal**
  - ▶ The rectum stores feces before defecation.
  - ▶ The anal canal is the terminal part of the gastrointestinal tract.

Fig 1. **Anatomy of the large intestine**



# Blood Supply and Innervation

## ▶ **Arterial Supply:**

- ▶ Superior mesenteric artery (cecum, ascending colon, and proximal transverse colon).
- ▶ Inferior mesenteric artery (distal transverse colon, descending colon, sigmoid colon, and rectum).

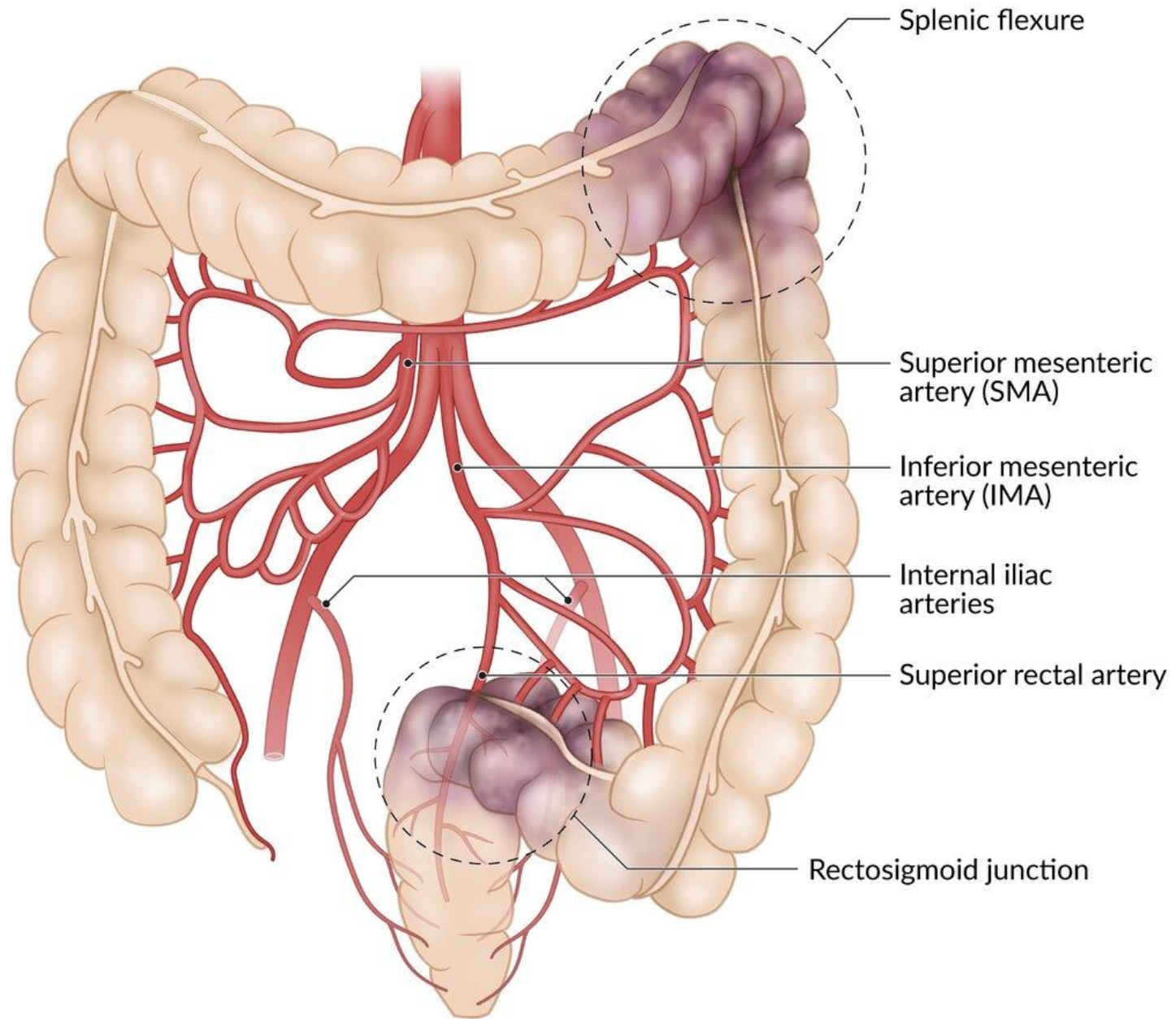
## ▶ **Venous Drainage:** Portal venous system.

## ▶ **Lymphatics:** Follow the arteries and drain into mesenteric lymph nodes.

## ▶ **Innervation:**

- ▶ Parasympathetic (vagus nerve and pelvic splanchnic nerves).
- ▶ Sympathetic (via superior and inferior mesenteric plexuses).





# Surgical Diseases of the Large Intestine

## ▶ Appendicitis

- ▶ **Definition:** Inflammation of the appendix.
- ▶ **Symptoms:** Right lower quadrant pain, fever, nausea.
- ▶ **Surgical Treatment:** Appendectomy (open or laparoscopic).

**We will talk about it in details later**

## ▶ B. Diverticular Disease

- ▶ **Definition:** Formation of diverticula, small pouches in the colon wall.
- ▶ **Complications:** Diverticulitis, perforation, abscess.
- ▶ **Surgical Indications:** Recurrent diverticulitis or complications like fistulas.


## ▶ C. Volvulus

- ▶ **Definition:** Twisting of the colon, commonly the sigmoid.
- ▶ **Symptoms:** Abdominal distension, pain, constipation.
- ▶ **Treatment:**
  - ▶ Non-surgical: Endoscopic detorsion.
  - ▶ Surgical: Resection of the affected segment.

## ▶ D. Intestinal Obstruction

- ▶ **Causes:** Tumors, strictures, or adhesions.
- ▶ **Symptoms:** Abdominal pain, vomiting, and absence of bowel movements.
- ▶ **Surgical Approach:** Relief of obstruction via resection or stoma creation.

**We will talk about it in details later**

- 
- ▶ **Ulcerative Colitis (UC)** is a chronic inflammatory bowel disease (IBD) that primarily affects the colon and rectum. It causes inflammation and ulcers in the lining of the large intestine, leading to symptoms such as abdominal pain, diarrhea (often with blood or mucus), weight loss, and fatigue. UC typically follows a relapsing-remitting course, with periods of flare-ups and remission. The exact cause is unknown, but it involves an abnormal immune response, genetic predisposition, and environmental factors. Treatment focuses on reducing inflammation, managing symptoms, and preventing complications, often through medications, lifestyle changes, or, in severe cases, surgery

# Tumors of the Large Intestine

## ▶ A. Benign Tumors

- ▶ **Adenomas:** Precancerous polyps that can develop into malignancies.
- ▶ **Lipomas:** Fatty tumors that are usually asymptomatic.

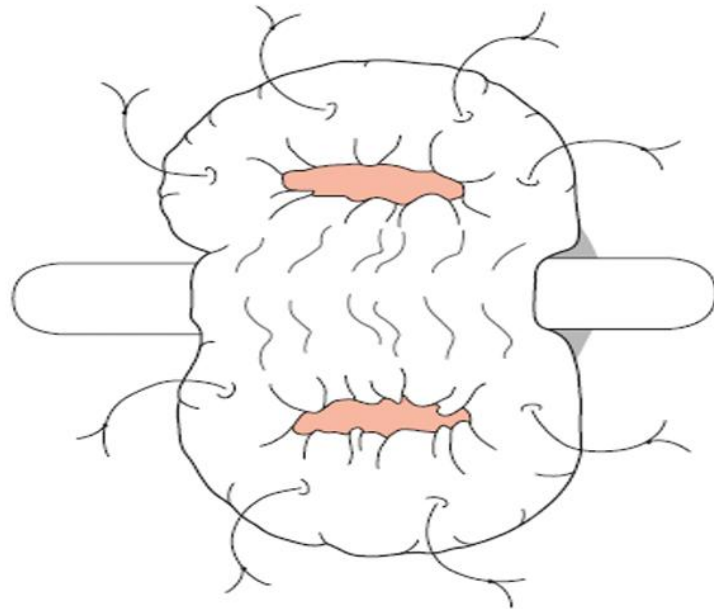
## ▶ B. Malignant Tumors

### ▶ Colorectal Cancer:

- ▶ **Epidemiology:** One of the most common cancers worldwide.
- ▶ **Risk Factors:** Family history, inflammatory bowel disease, diet, smoking.
- ▶ **Symptoms:** Rectal bleeding, change in bowel habits, anemia, weight loss.
- ▶ **Diagnosis:**
  - ▶ Colonoscopy with biopsy.
  - ▶ Imaging: CT scan, MRI, or PET scan for staging.
- ▶ **Treatment:**
  - ▶ Surgical resection with lymphadenectomy.
  - ▶ Adjuvant chemotherapy or radiotherapy depending on stage.

# COLOSTOMIES

- ▶ A colostomy (or ileostomy) stoma is a planned opening made in the colon (or small intestine) to divert feces and flatus to the abdominal wall where they can be collected in an external appliance.



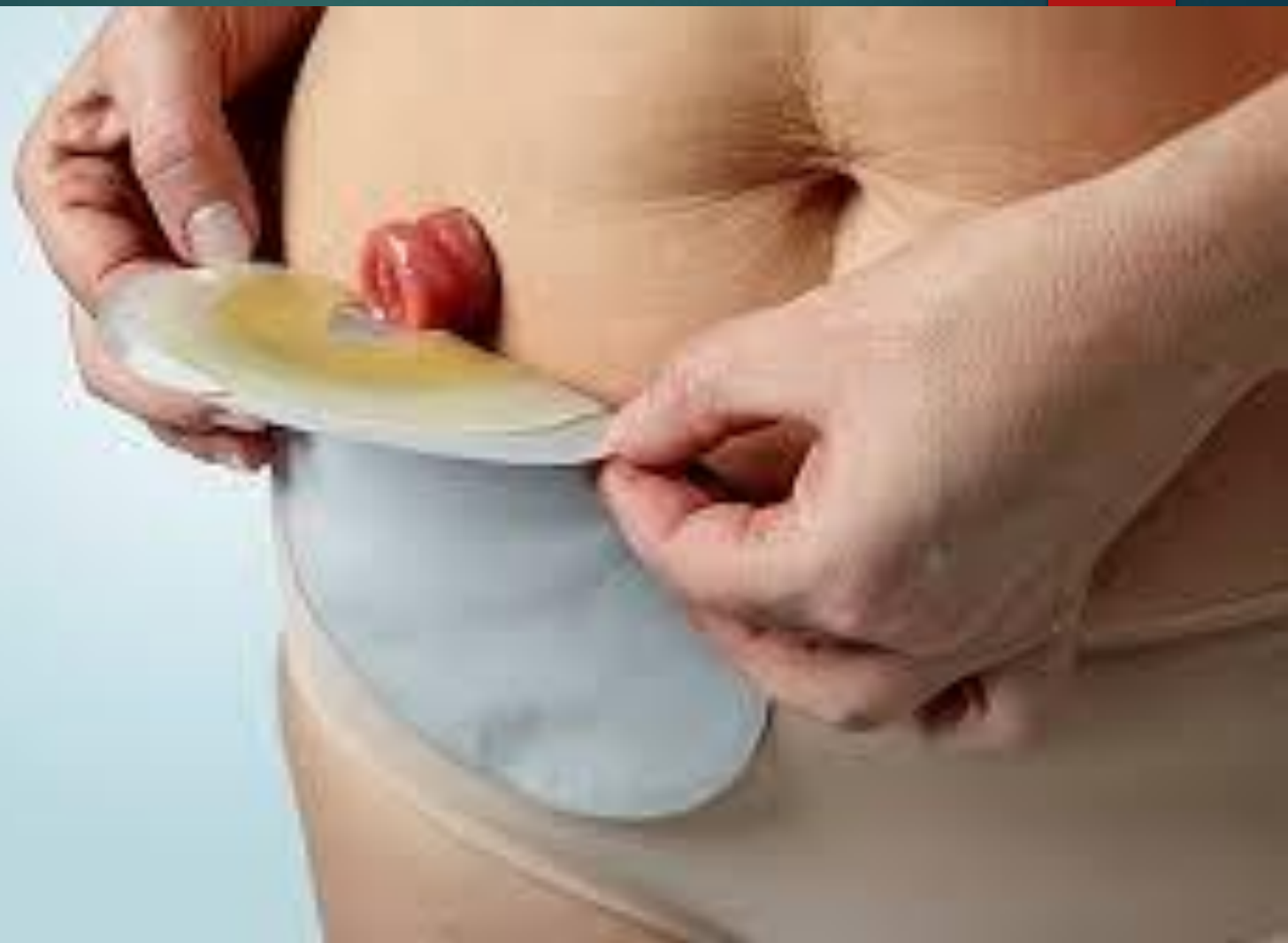
**Figure 70.24** Temporary (loop) colostomy opened over a rod, and immediate suture of the colon wall to surrounding skin (alternatively, a skin bridge is used).





## ▶ Stomas

1. May be colostomy or ileostomy.
2. May be temporary or permanent.
3. An ileostomy is spouted; a colostomy is flush.
4. Ileostomy effluent is usually liquid whereas colostomy effluent is usually solid.
5. Ileostomy patients are more likely to develop fluid and electrolyte problems.
6. An ileostomy is usually sited in the right iliac fossa.
7. End-colostomy is usually sited in the left iliac fossa.



## ▶ **Stoma complications**

1. **Skin irritation**
2. **Prolapse**
3. **Retraction**
4. **Ischemia**
5. **Stenosis**
6. **Parasternal hernia**
7. **Bleeding**
8. **Fistulation**