



Al-Mustaqbal University

College of Health and Medical Technique

Radiology Techniques Department

Third class

By

Assist. lecture

Mustafa kamel muneam

lecture : 2

Introduction:

المقدمة:

Radiographic techniques :- It is used to diagnose or treat patients by recording images of the internal structure of the body to assess the presence or absence of disease, foreign objects, and structural damage or anomaly.

Pretest:

الاختبار القبلي:

What is the Radiographic techniques

Radiographic techniques

Assistant lecturer. Dunya Ali

Radiographic technique of skull

Basic skull technique should be undertaken for specific conditions and referrals and only when the patients' condition allows.

Lateral – supine with horizontal beam (Figs 8.8a, 8.8b)

Position of patient and image receptor

- The patient lies supine with the head raised and immobilized on a non-opaque skull pad. This will ensure the occipital region is included on the image.
- The head is adjusted such that the median sagittal plane is perpendicular to the table/trolley and the interpupillary line is perpendicular to the image receptor.
- The image receptor is supported vertically against the lateral aspect of the head parallel to the median sagittal plane with its edge 5 cm above the vertex of the skull.

Direction and location of the X-ray beam

- The collimated horizontal beam is directed parallel to the interpupillary line such that it is at right-angles to the median sagittal plane.
- The centring point is midway between the glabella and the external occipital protuberance to a point approximately 5 cm superior and posterior to the EAM.
- The long axis of the image receptor should be coincident with the long axis of the skull.

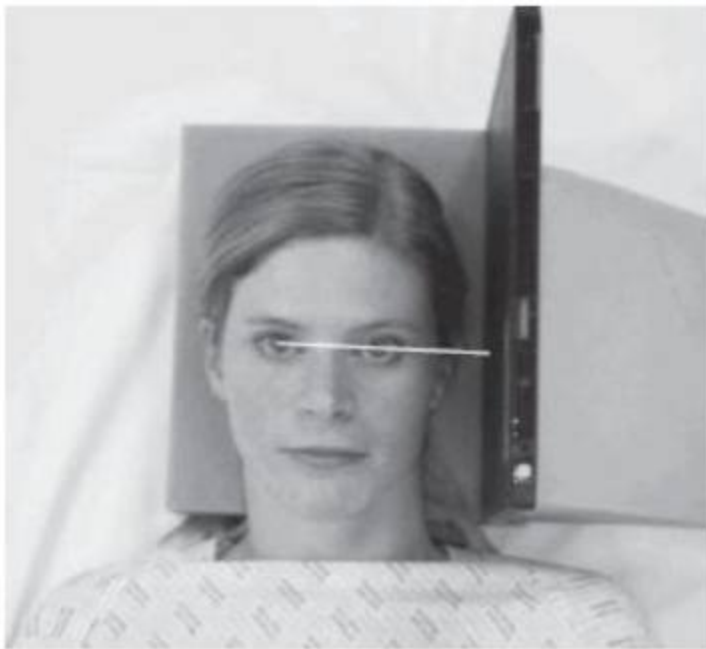

Fig. 8.8a Position from the anterior aspect with the line showing the interorbital line relation to image receptor; the patient is supported in the correct position.

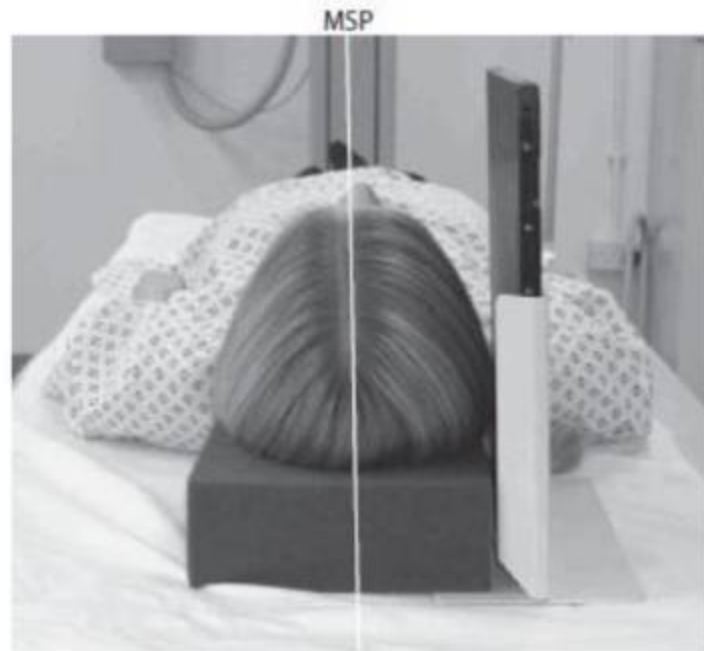

Fig. 8.8b Patient positioning from the superior aspect showing MSP,

Essential image characteristics

- The image should contain all of the cranial bones and the 1st cervical vertebrae.
- A true lateral will result in superimposition of the lateral portions of the floors of the anterior and the posterior cranial fossa. The clinoid processes of the sella turcica should also be superimposed.

Common faults and solutions

- Failure to include the occipital region as a result of not using a pad or similar to ensure the head is elevated adequately from the trolley surface.
- Poor superimposition of the lateral floors of the cranial fossa. Always ensure the interorbital line is perpendicular to the cassette/receptor and the median sagittal plane is perpendicular to the trolley surface.

Lateral erect (Figs 8.9a–8.9c)

Position of patient and image receptor

- The patient sits facing the erect Bucky/receptor and the head is then rotated such that the median sagittal plane is parallel to the Bucky/receptor and the interpupillary line is perpendicular to the Bucky/ receptor.
- The shoulders may be rotated slightly to allow the correct position to be attained and the patient may grip the Bucky inferiorly for stability.
- Position the image receptor transversely such that its upper border is 5 cm above the vertex of the skull.
- A radiolucent pad may be placed under the chin, for support.

Direction and location of the X-ray beam

- The X-ray tube should be centred to the Bucky/image receptor.
- Adjust the height of the Bucky/tube so that the patient is comfortable

- Centre with a collimated horizontal beam midway between the glabella and the external occipital protuberance to a point approximately 5 cm superior and posterior to the EAM.



Fig. 8.9a Correct positioning for erect lateral skull.




Fig. 8.9b Incorrect positioning for erect lateral skull.

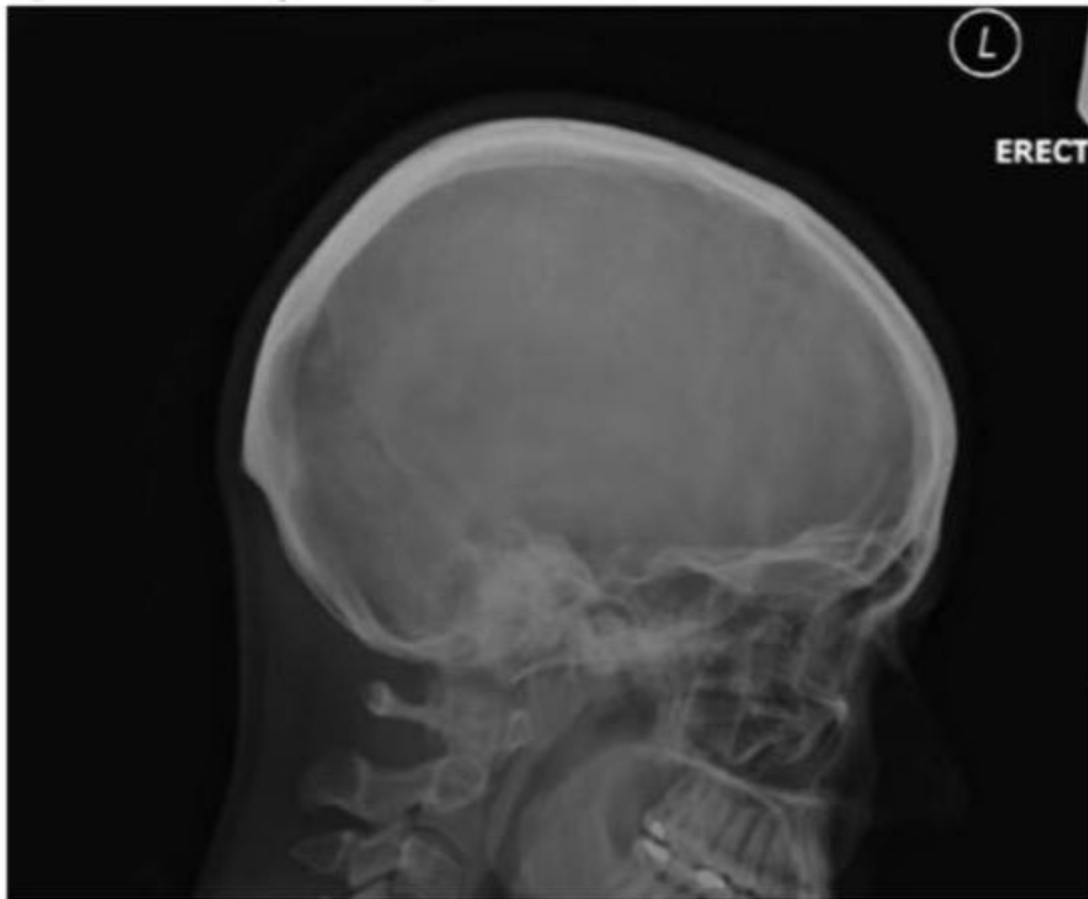

Fig8.9c lateral skull radiograph

Occipito-frontal (Figs 8.10a–8.10e)

Occipito-frontal (OF) projections can be employed with different degrees of beam angulation. The choice of projection will depend upon departmental protocol and the anatomy that needs to be demonstrated.

Position of patient and image receptor

- The patient is seated facing the erect Bucky/receptor so that the median sagittal plane is coincident with the midline of the image receptor and is also perpendicular to it.
- The neck is flexed so that orbito-meatal baseline is perpendicular to the image receptor. This can usually be achieved by ensuring the nose and forehead are in contact with the Bucky/receptor.
- Ensure the mid part of the frontal bone is positioned in the centre of the Bucky/receptor.

Direction and location of the X-ray beam

OF:

- The collimated horizontal beam is directed perpendicular to the Bucky/receptor along the median sagittal plane.

- The beam collimation should include the vertex of the skull superiorly, the region immediately below the base of the occipital bone inferiorly and the lateral skin margins. It is important to ensure the tube is centred to the centre of the Bucky receptor.

OF10° ↓, OF15° ↓, OF20° ↓:

- The technique used for these three projections is similar to that employed for the OF except a caudal angulation is applied. The degree of angulation will depend upon the technique, i.e. for an OF20° ↓ projection a 20° caudal angulation will be employed.

- Ensure the collimated horizontal beam is always centred to the centre of the Bucky/image receptor after the tube angulation has been applied and not before.




Fig. 8.10a Positioning for OF skull projection.




Fig. 8.10b Positioning for OF10°↓ skull projection.




Fig. 8.10c Positioning for OF20°↓ skull projection.

Essential image characteristics

- All the cranial bones should be included within the image including the skin margins.
- It is important to ensure the skull is not rotated.

The degree of beam angulation can be evaluated from an assessment of the position of the petrous ridges within the orbits:

- OF: the petrous ridges should be completely superimposed within the orbit with their upper borders coincident with the upper 1/3 of the orbit.
- OF10° ↓ : the petrous ridges appear in the middle 1/3 of the orbit.
- OF15° ↓ : the petrous ridges appear in the lower 1/3 of the orbit.
- OF20° ↓ : the petrous ridges appear just below the inferior orbital margin.

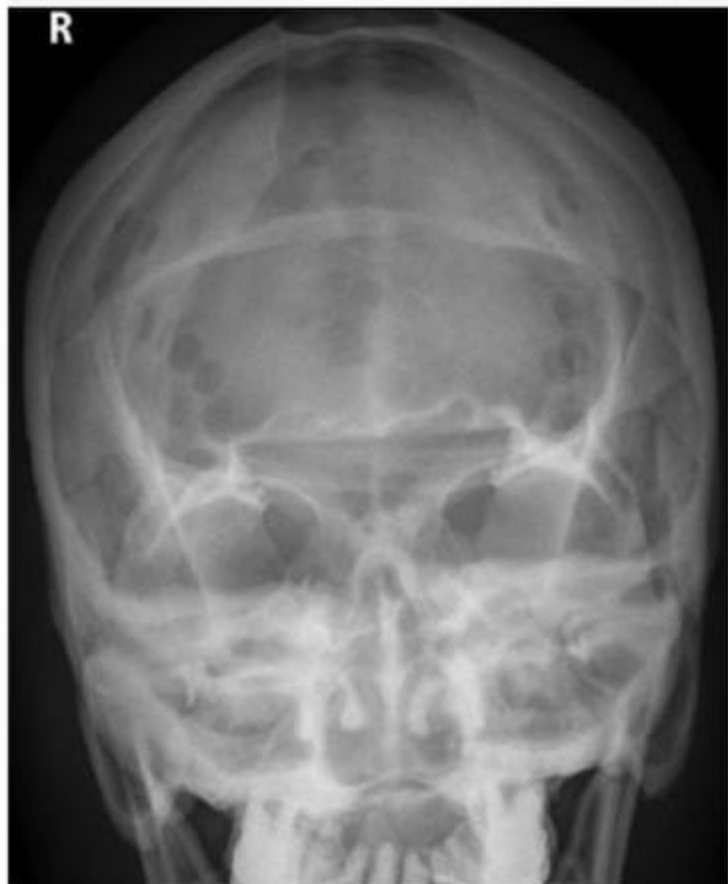
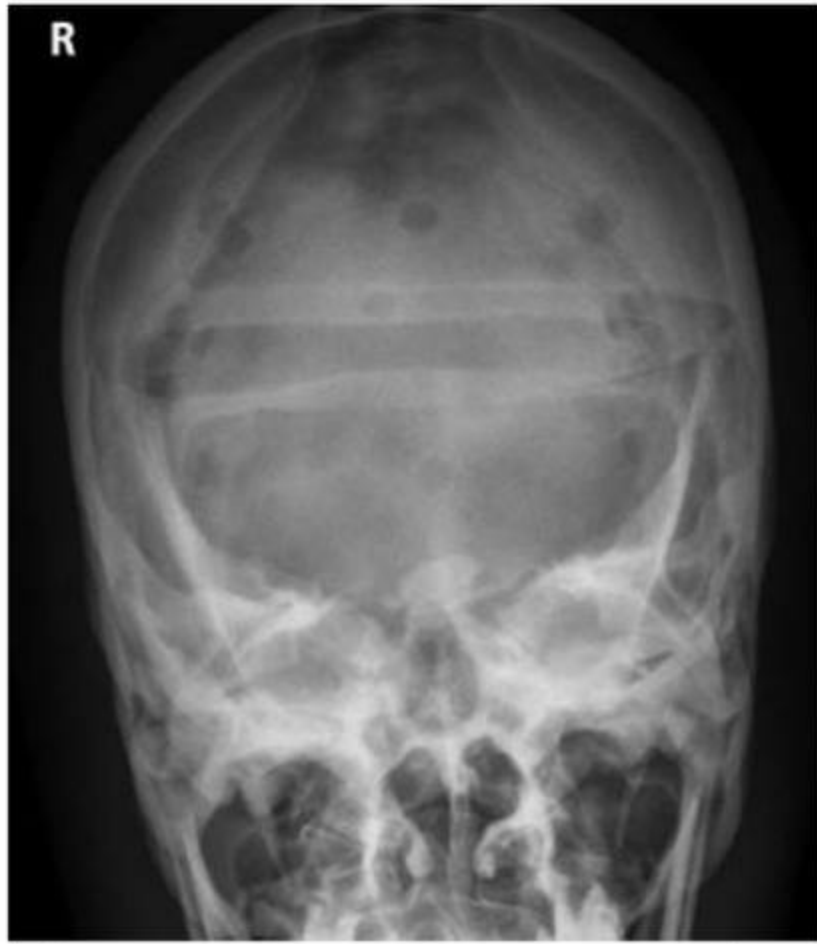
Fig. 8.11b OF 15°.

Fig8. 11a OF

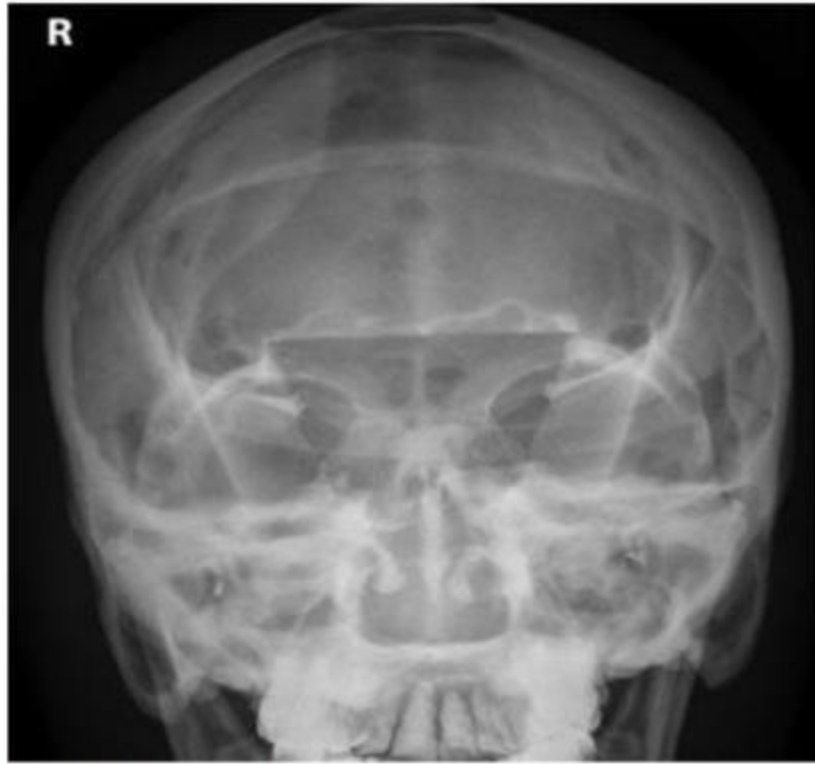

Fig. 8.11c OF 20°.

Fronto-occipital (Figs 8.12a–8.12c)

Fronto-occipital (FO) projections of the skull will demonstrate the same anatomy as OF projections. The orbits and frontal bone however, will be magnified as they are positioned further from the image receptor. Such projections should only be undertaken when the patient cannot be moved and must be imaged supine. These projections result in an increased radiation dose to the orbits and some loss of resolution of the anterior skull structures due to increased object-to-receptor distance.

Position of patient and image receptor

- The patient lies supine on the trolley (or X-ray table) with the posterior aspect of the skull resting on the image receptor/ gridded CR cassette.
- The head is adjusted to bring the median sagittal plane at right-angles to the image receptor and coincident with its midline. In this position the EAMs are equidistant from the image receptor to ensure no rotation.
- The orbito-meatal baseline should be perpendicular to the image receptor.

Direction and location of the X-ray beam

- All angulations for FO projections are made cranially.
- The collimated vertical X-ray beam is directed perpendicular to the image receptor along the median sagittal plane.
- The collimated field should be set to include the vertex of the skull superiorly, the base of the occipital bone inferiorly and the lateral skin margins.

FO10° ↑, FO15° ↑, FO20° ↑:

- The technique used for these three projections is similar to that employed for the OF except cranial angulations are applied. The degree of angulation will depend upon the projection required.
- Remember that the image receptor must be displaced superiorly to allow for the tube angulation.

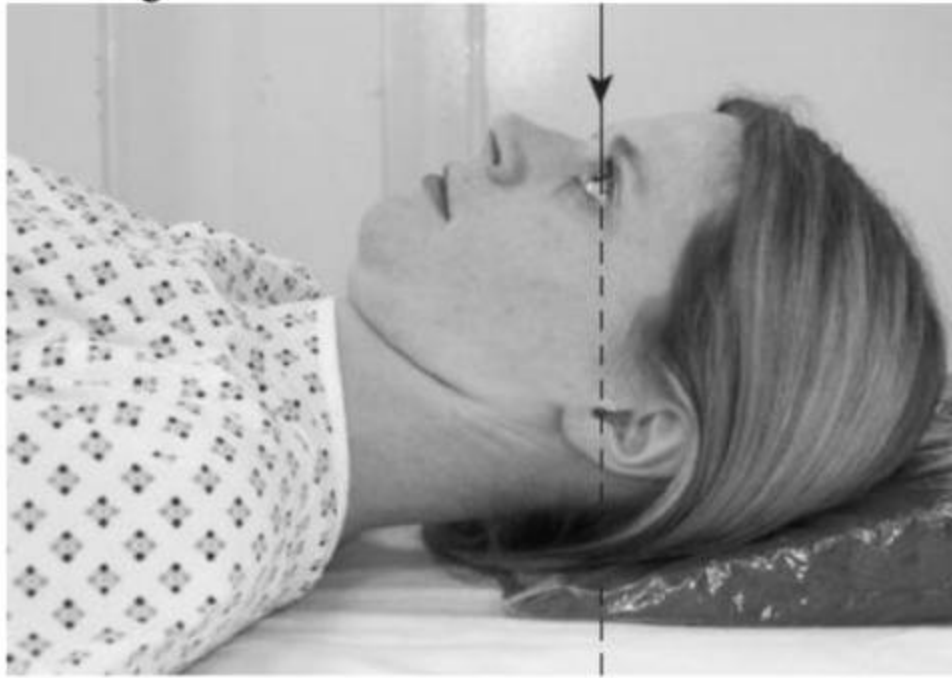


Fig. 8.12a FO projection.

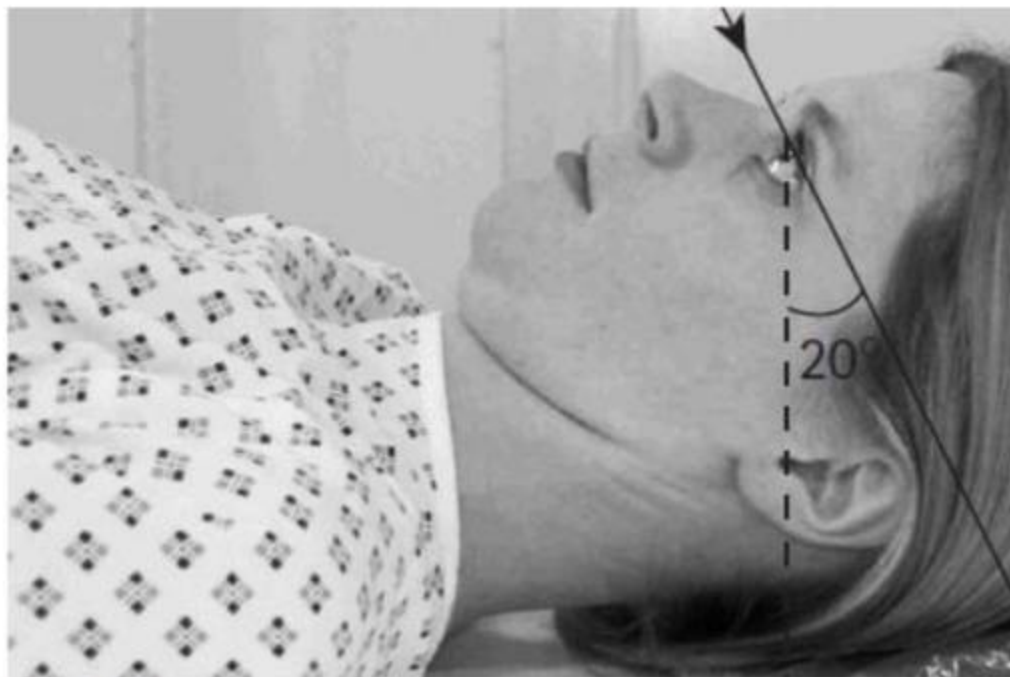


Fig. 8.12b FO 20° projection.

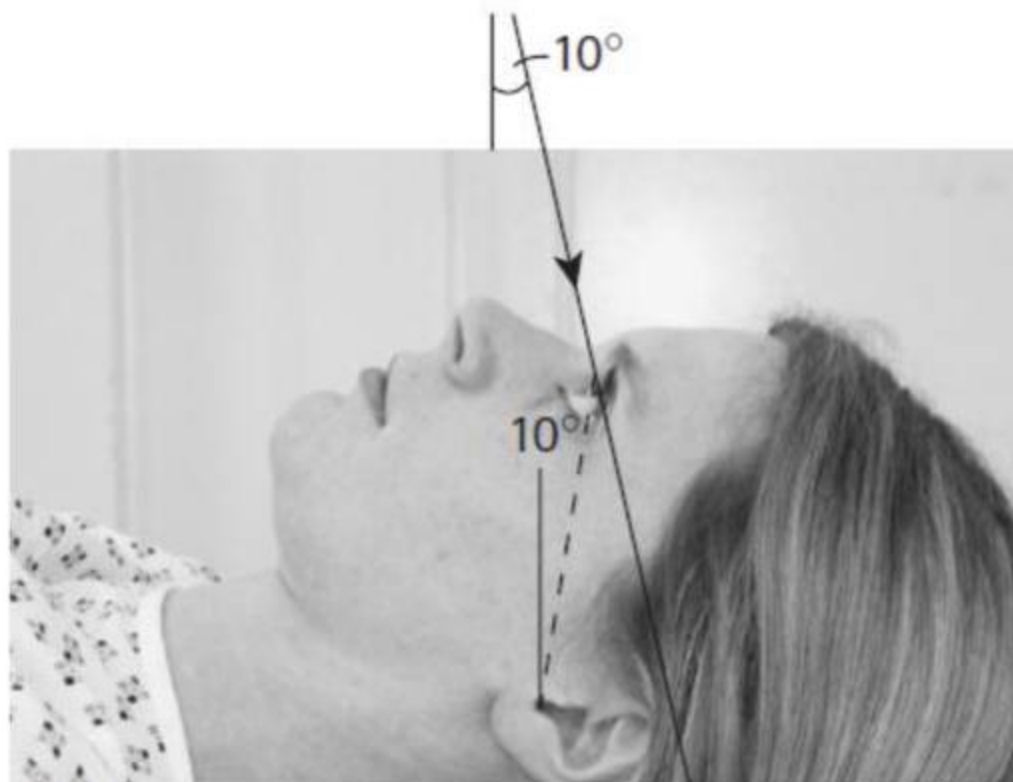


Fig. 8.12c FO 20° projection achieved with 10° tube angle and RBL raised 10°.

Half axial, fronto-occipital 30° Caudal (Towne's projection) (Figs 8.13a, 8.13c)

Position of patient and image receptor

- The patient lies supine on a trolley (or X-ray table) with the posterior aspect of the skull resting on an image receptor/ gridded CR cassette.
- The head is adjusted to bring the median sagittal plane at right-angles to the image receptor and so that it is coincident with its midline.
- The orbito-meatal baseline should be perpendicular to the image receptor.

Direction and location of the X-ray beam

- The collimated vertical beam is angled caudally so it makes an angle of 30° to the orbito-meatal base line.
- The top of the receptor should be positioned adjacent to the vertex of the skull to ensure the beam angulation does not project the area of interest off the bottom of the image.

Essential image characteristics (Fig. 8.13b)

- The sella turcica of the sphenoid bone is projected to appear within the foramen magnum.
- The image must include all of the occipital bone and the posterior parts of the parietal bone and the lambdoidal suture should be clearly visualized.

- The skull should not be rotated. This can also be assessed by ensuring the sella turcica appears centrally in the foramen magnum.

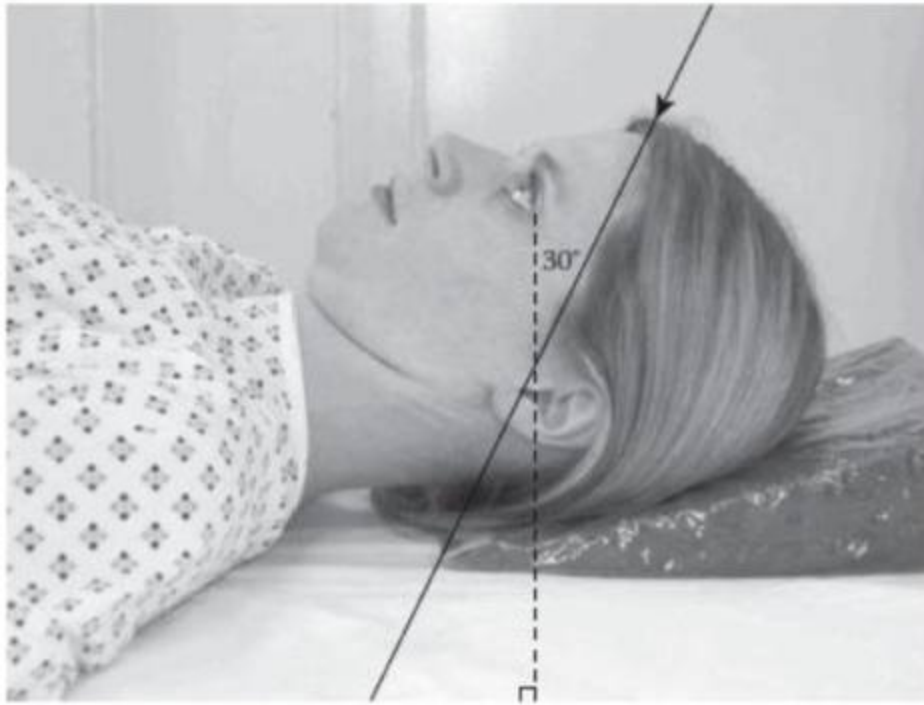


Fig. 8.13a FO 30° Towne's projection.

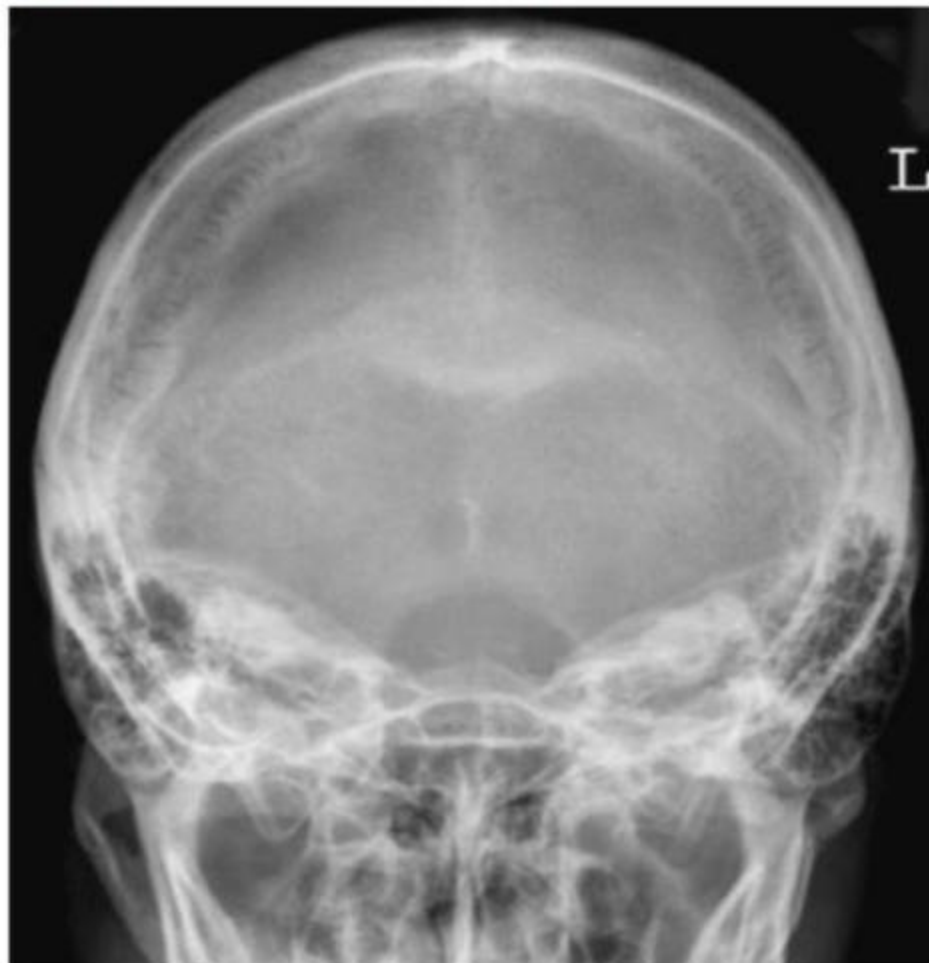


Fig. 8.13b Correctly positioned townes with sella turcica seen within the foramen magnum.

Submento-vertical (Figs 8.16a, 8.16c)

Position of patient and image receptor

The patient may be imaged erect or supine. If the patient is unsteady then a supine technique is advisable as this is a difficult position to maintain.

Supine:

- The patient's shoulders are raised and neck hyperextended to bring the vertex of the skull in contact with the image receptor/gridded CR cassette (or X-ray table).
- The head is adjusted to bring the EAMs equidistant from the image receptor.
- The median sagittal plane should be at right-angles to the image receptor along its midline.
- The orbito-meatal plane should be as near as possible parallel to the image receptor.

Erect:

- The patient sits facing the X-ray tube a short distance away from the vertical Bucky/ receptor.
- The neck is hyperextended to allow the head to fall back until the vertex of the skull makes contact with the centre of the vertical image receptor.
- The remainder of the positioning is as described for the supine technique.

Direction and location of the X-ray beam

- The collimated perpendicular beam is directed at right angles to the orbito-meatal base line and centred midway between them.

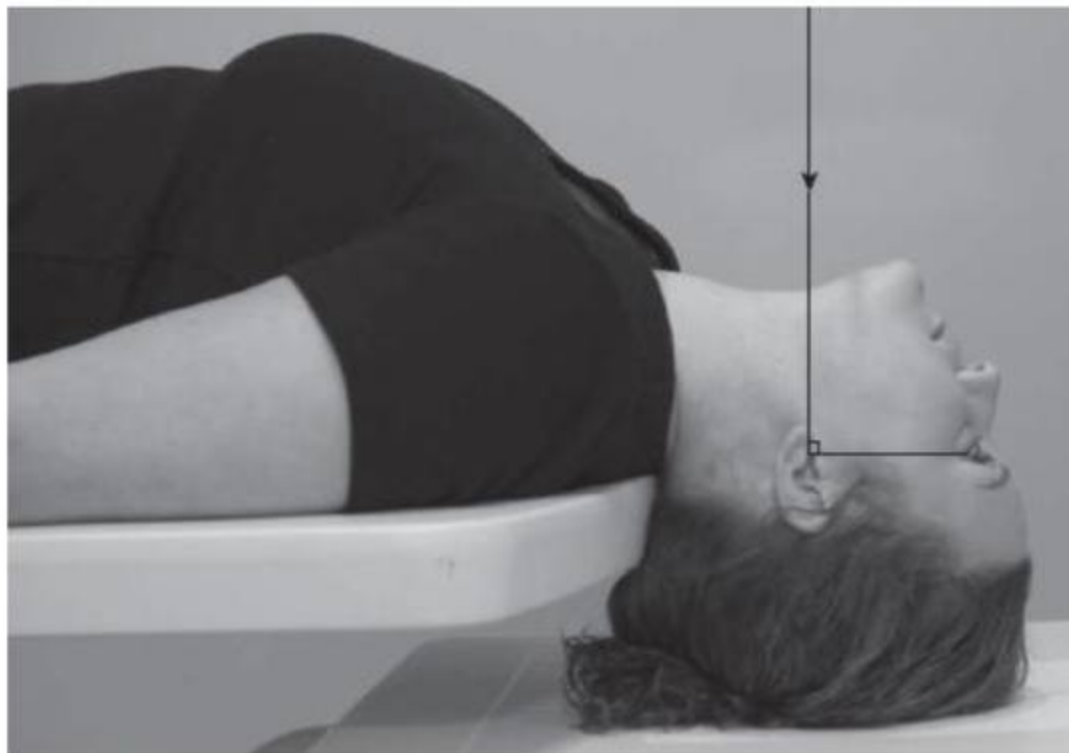

Fig. 8.16a SMV using supine technique.

Essential image characteristics (Fig. 8.16b)

- An optimum projection will demonstrate the mandibular angles clear of the petrous portions of the temporal bone.

- The foramina of the middle cranial fossa should be seen symmetrically either side of the midline.

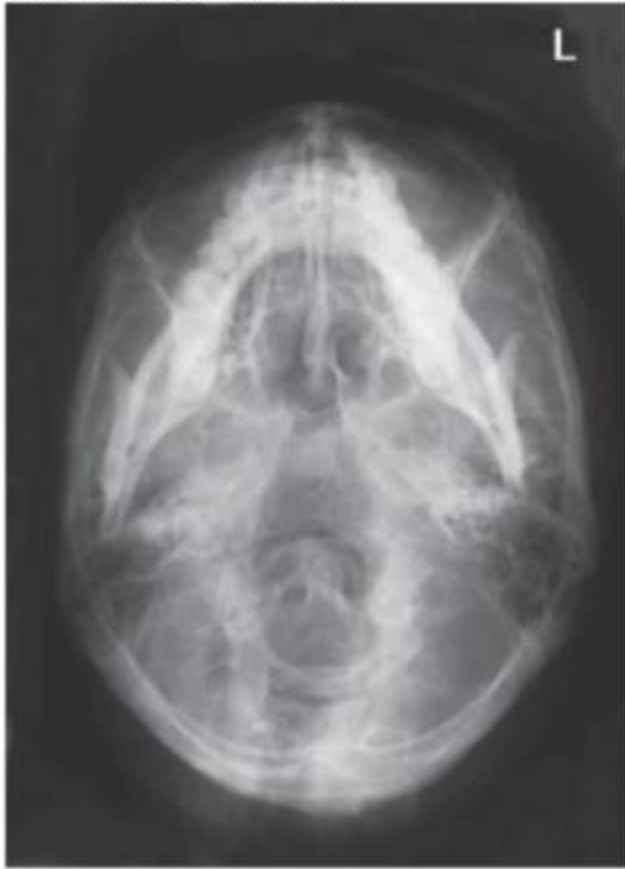

Fig. 8.16b SMV radiograph.