



Echinococcus granulosus

Common name: Dog tape worm

Habitat

- The adult worm lives in the jejunum and duodenum of dogs and other canine carnivore (wolf الذئب and fox ثعلب).
- The larval stage (hydatid cyst) is found in humans and herbivorous animals (sheep, goat, cattle and horse).

Morphology

Adult Worm

- It is a small tapeworm, measuring only 3-6 mm in length.
- It consists of a scolex, a short neck, and strobila.
- The scolex is pyriform, with 4 suckers and a prominent rostellum bearing 2 circular rows of hooklets (25–30).
- The neck is short than the rest of the worm (3 mm × 6 mm).
- The strobila is composed of only 3 proglottids, the anterior immature, the middle mature, and the posterior gravid segment.
- The terminal proglottid is longer and wider than the rest of the worm and contains a branched uterus filled with eggs.
- The adult worm lives for 6–30 months.

Egg

- The eggs of *Echinococcus* are indistinguishable from those of *Taenia* species.
- It is ovoid in shape and brown in color.
- It contains an embryo with 3 pairs of hooklets.

Larval Form

- The larval form is found within the hydatid cyst developing inside various organs of the intermediate host.
- It represents the structure of the scolex of adult worm and remains **invaginated** within a vesicular body.
- After entering the definitive host, the scolex with suckers and rostellar hooklets, becomes **exvaginated** and develops into adult worm.

Life Cycle

The worm completes its life cycle in 2 hosts:

Definitive hosts: Dog (optimal host), wolf, jackal ابن اوى, and fox

Intermediate host: Sheep and Cattle. Sheep is the ideal intermediate host.

- Man acts as an accidental intermediate host (dead end).
- The larval stage of the parasite is passed in intermediate hosts, including man, giving rise to hydatid cyst.

- The adult worm lives in the small intestine of dogs and other canine animals. These animals discharge numerous eggs in the feces.
- Intermediate hosts (sheep and cattle) ingest them while grazing.
- Human infection follows ingestion of the eggs due to intimate handling of infected dogs or by eating raw vegetables or other food items contaminated with dog feces.
- The ova ingested by man or by sheep and cattle are liberated from the chitinous wall by gastric juice liberating the **hexacanth embryos** which penetrate the intestinal wall and enter the **portal venules**, to be carried to the liver along the portal circulation.
- These are trapped in hepatic sinusoids, where they eventually develop into hydatid cyst. About 75% of hydatid cyst develop in liver, which acts as the first filter for embryo.
- However, some embryo which pass through the liver, enter the right side of heart and are caught **تتجمع** in **pulmonary capillaries** (forming pulmonary hydatid cysts), so that the lung acts as the **second filter**.
- A few enter the systemic circulation and get lodged **تستقر** in various other organs and tissues such as the spleen, kidneys, eyes, brain, or bones.
- When sheep or cattle harboring hydatid cysts die or are slaughtered **تذبح**, dogs may feed on the carcass **جثة** or offal **فضلات**. Inside the intestine of dogs, the scolices develop into the adult worms that mature in about 6–7 weeks and produce eggs to repeat the life cycle.
- When infection occurs in humans accidentally, the cycle comes to a dead end because the human hydatid cysts are unlikely to be eaten by dogs.

Pathogenesis

Evolution of Hydatid Cyst

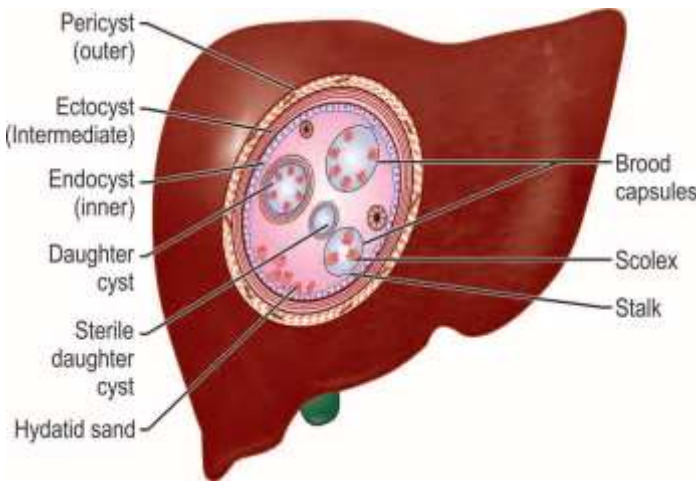
At the site of deposition, the embryo slowly develops into a hollow bladder or cyst filled with fluid.

This becomes the hydatid cyst (Greek *hydatis*: a drop of water).

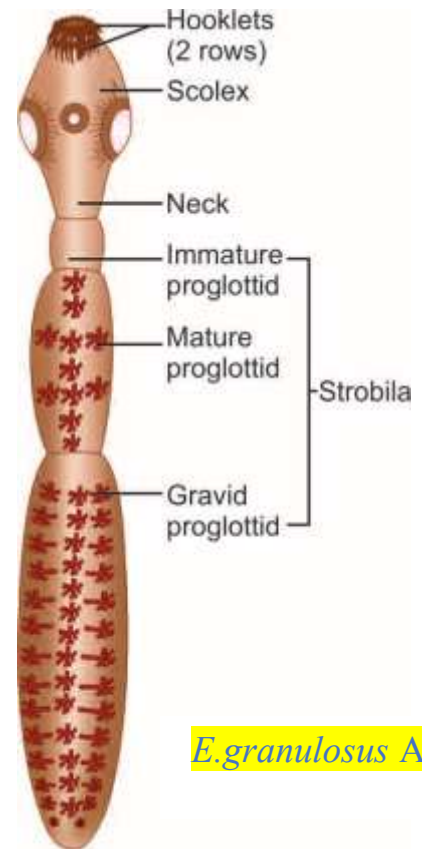
- It enlarges slowly and reaches a diameter of 0.5–1 cm in about 6 months. The growing cyst evokes host tissue reaction leading to the deposition of fibrous capsule around it.
- The cyst wall secreted by the embryo consists of indistinguishable layers.
- **Pericyst** is the outer host inflammatory reaction consisting of fibroblastic proliferation, mononuclear cells, eosinophils, and giants cells, eventual developing into dense fibrous capsule which may even calcify.
- **Ectocyst** is the intermediate layer composed of characteristic a cellular, chitinous, laminated hyaline material. It has the appearance of the white of a hardboiled egg **البيض المسلوق**.
- **Endocyst** is the inner germinal layer which is cellular and consists of number of nuclei embedded in a protoplasmic mass and is extremely thin (22–25 mm).

The germinal layer is the vital layer *الطبقة الحويبية* of the cyst and is the site of asexual reproduction giving rise to brood capsules with scolices. It also secretes hydatid fluid, which fills the cyst.

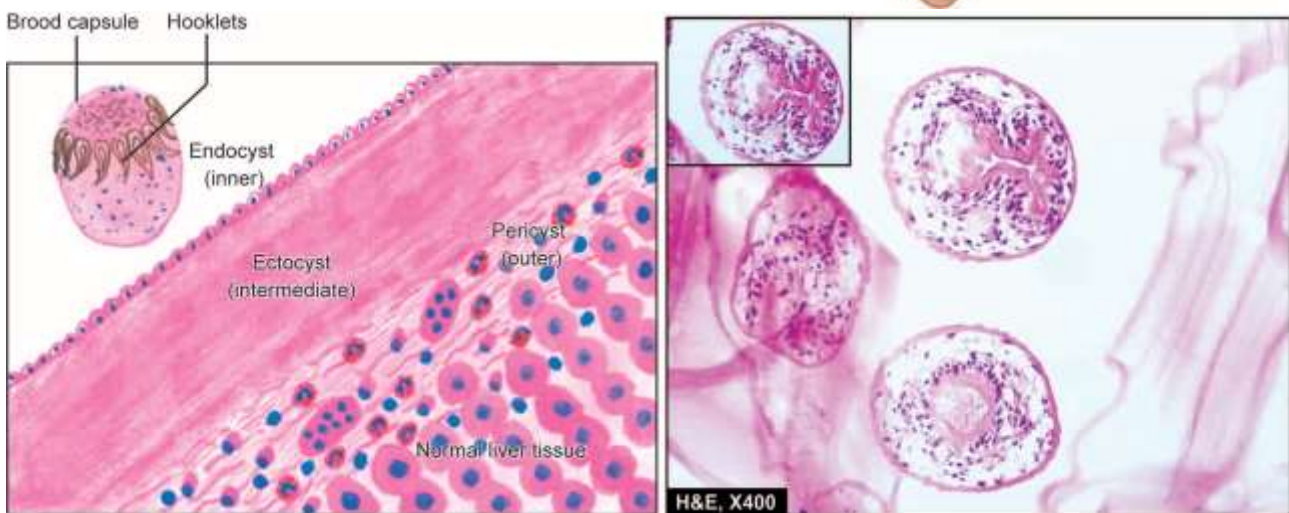
- **Hydatid fluid:** The interior of the cyst is filled with a clear colorless or pale yellow fluid called as **hydatid fluid**.
- pH of the fluid is 6.7 (acidic).



Hydatid Cyst in the Liver



E. granulosus Adult



Microscopy shows 3 layers in the wall of hydatid cyst. In box in the right photomicrograph shows a scolex with a row of hooklets.

Composition: It contains salts (sodium chloride 0.5%, sodium sulphate, sodium phosphate, and salts of succinic acid) and proteins.

- It is antigenic and highly toxic so that its liberation into circulation gives rise to pronounced eosinophilia **فرط الحساسية** or may even cause anaphylaxis **فرط الحساسية**.
- The fluid was used as the antigen for Casoni's intradermal test.
- A granular deposit or **hydatid sand** is found at the bottom of the cyst, consisting of **free brood capsules** and protoscolices and loose hooklets.

Brood capsules

From the germinal layer, small knob-like excrescences **تبرز زوائد صغيرة تشبه المقبض** into the lumen of the cyst. These enlarge, become vacuolated, and are filled with fluid. These are called as **brood capsules**.

- They are initially attached to the germinal layer by a stalk, but later escape free into the fluid-filled cyst cavity.
- From the inner wall of the brood capsules, protoscolices (new larvae) develop, which represent the head of the potential worm, complete with invaginated scolex, bearing suckers and hooklets.
- Several thousands of protoscolices develop into a mature hydatid cyst, so that this represents an asexual reproduction.
- Inside mature hydatid cysts, further generation of cyst, **daughter** cysts and **grand daughter** **الضخمة-daughter** cysts may develop. The cyst grows slowly often taking 20 years or more to become big enough to cause clinical illness and is therefore, particularly seen in man.

Acephalocysts

Some cysts are sterile and may never produce brood capsules, while some brood capsule may not produce scolices. These are called *acephalocysts*.

Fate of hydatid cysts

The cyst may get calcified or spontaneously evacuated following inflammatory reaction. Hydatid cyst of liver may rupture into lung or other body cavity producing disseminated hydatid lesions.

Clinical Features

- Most of the times infection is asymptomatic and accidentally discovered.
- Clinical disease develops only when the hydatid cyst has grown big enough to cause obstructive symptoms. Disease results mainly from pressure effects caused by the enlarging cysts.

- In about half the cases, the primary hydatid cyst occurs in **liver** (63%) in the right lobe. Hepatomegaly, pain, and obstructive jaundice are the usual main manifestations.
- The next common site is the **lung** (25%) (most common being the lower lobe of the right lung). Cough, hemoptysis, chest pain, pneumothorax, and dyspnea constitute the clinical picture.
- In the kidney (2%), hydatid cyst causes pain and hematuria.
- **Other sites** affected include spleen (1%), brain (1%), pelvic organs, orbit, and bones (3%). Cerebral hydatid cysts may present as focal epilepsy.
- When hydatid cyst is formed inside the **bones**, the laminated layer is not well developed because of confinement by dense osseous tissues. The parasite migrates along the bony canals as naked excrescences that erode the bone tissue. This is called osseous hydatid cyst. Erosion of bone may lead to pathological fractures.
- Apart from pressure effects, another pathogenic mechanism in hydatid disease is **hypersensitivity** to the echinococcal antigen. The host is sensitized to the antigen by minute amounts of hydatid fluid seeping through the capsule. Hypersensitivity may cause **urticaria**. But if a hydatid cyst ruptures spontaneously or during surgical interference, massive release of hydatid fluid may cause severe, even **fatal anaphylaxis**.

Laboratory Diagnosis

✓ Imaging

- Radiological examinations and other imaging techniques such as ultrasonography (USG), CT scan, and MRI reveal the diagnosis in most cases of **cystic echinococcosis**
- **USG** is the diagnostic procedure of choice. Cyst wall typically shows double echogenic lines separated by a hypoechoic layer (**double contour**). Pathogenic findings include daughter cysts and the ‘**water-lily**’ sign due to detached endocyst floating within the cavity.
- **CT scan** is superior for the detection of extrahepatic disease.
- **MRI** appears to add diagnostic benefit for cysts, especially at difficult sites such as spinal vertebrae and cardiac cysts.
- **Plain X-rays** permit the detection of hydatid cyst in lung and bones. In cases where long bones are involved, a mottled appearance is seen in the skiagram.
- **IV pyelogram** is often helpful for detection of renal hydatid cyst.

✓ Examination of Cyst Fluid

Examination of aspirated cyst fluid under microscope after trichome staining reveals scolices, brood capsules, and hooklets. Exploratory puncture of the cyst to obtain cystic fluid should be avoided as it may cause escape of hydatid fluid and consequent anaphylaxis. Therefore, fluid aspirated from surgically removed cyst should only be examined

✓ Casoni's Intradermal Test

- It is an immediate hypersensitivity (Type 1) skin test introduced by Casoni in 1911, using fresh sterile hydatid fluid. The antigen in hydatid fluid is collected from animal or human cysts and is sterilized by Seitz or membrane filtration. The fluid is injected (0.2 mL) intradermally in one arm and an equal volume of saline as control is injected in the other arm. In a positive reaction, a large wheal of about 5 cm in diameter with multiple pseudopodia like projections appears within half an hour at the test side and fades in about an hour. A secondary reaction consisting of edema and induration appears after 8 hours. The test is almost abandoned now due to non-specificity and has been supplemented by serological tests.

✓ Serology

Antibody detection

- Detection of serum antibodies using specific antigens (8 and 16 KDA) from hydatid fluid are frequently used to support the clinical diagnosis of cystic echinococcosis.
- The tests include IHA, indirect immunofluorescence, and
- ELISA. In hepatic cysts, the sensitivity of test is relatively superior (85–98%) than pulmonary cyst (50–60%).
- The slide latex agglutination test and immune electrophoresis using hydatid fluid fraction 5 antigen are also widely used. Precipitin test and complement fixation test (CFT) with hydatid antigen have also been found to be positive. CFT is not very sensitive and false positive reaction is seen in those receiving neural
- antirabic vaccine. CFT is useful after surgical removal of cysts, when a negative test has a better prognostic value.

Antigen detection

Specific echinococcal antigen in sera and in CSF can be detected by double diffusion and counter immunoelectrophoresis technique (CIEP).

✓ Blood Examination

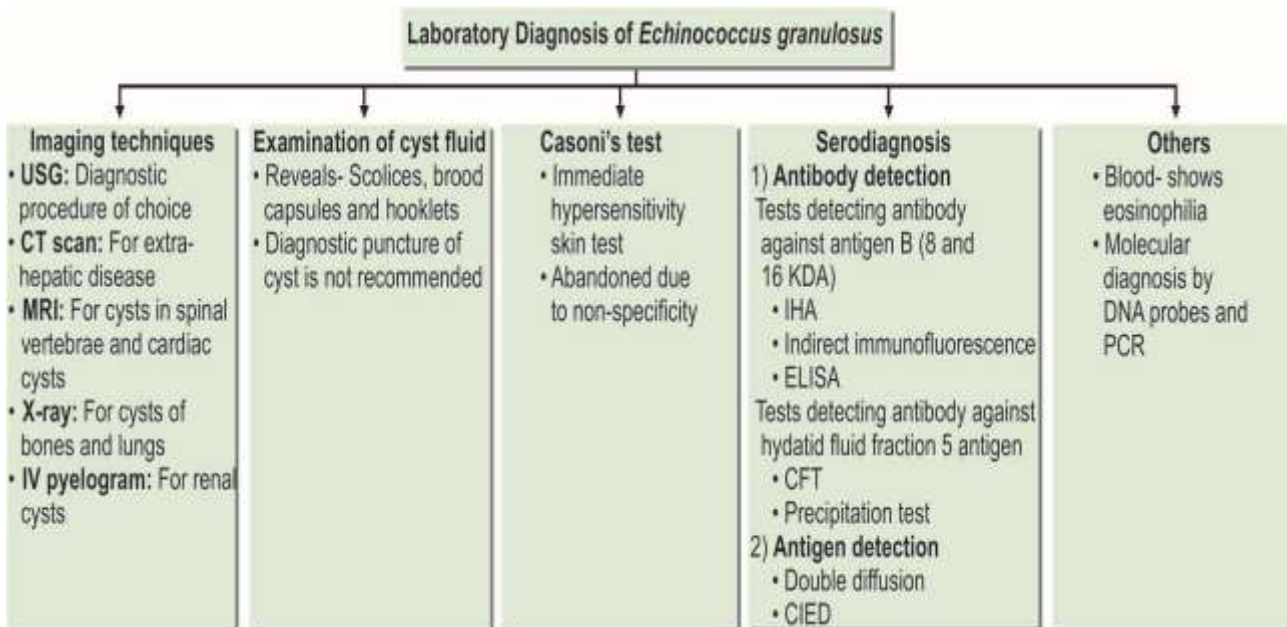
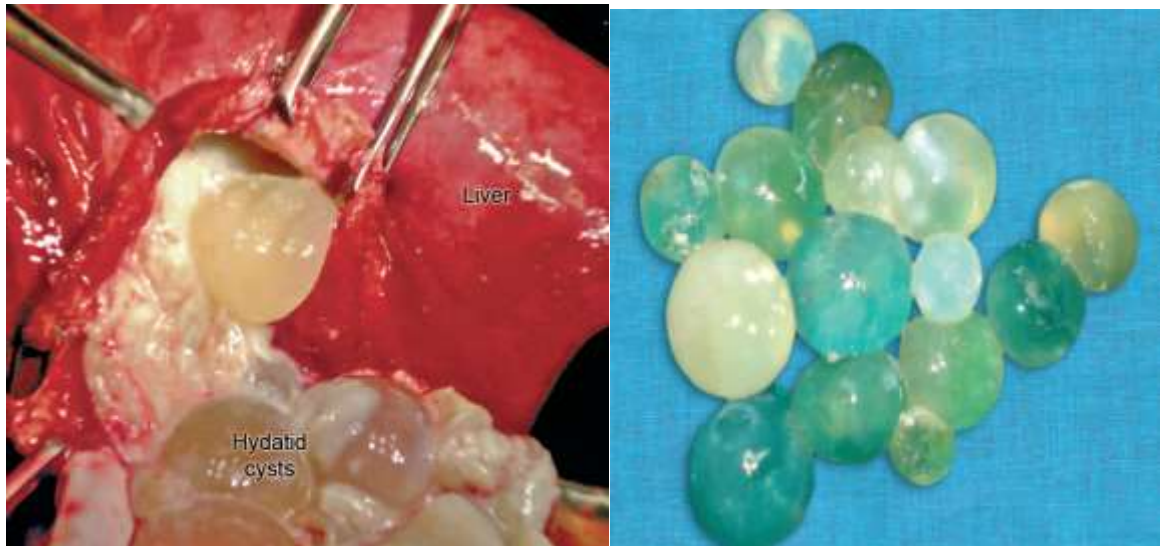
It may reveal a generalized **eosinophilia** of 20–25%.

✓ Excretion of the Scolices

Excretion of scolices into the sputum or urine may be observed in pulmonary or renal cyst, respectively and can be demonstrated by acid fast staining or lactophenol cotton blue (LPCB) staining.

✓ Specific Molecular Diagnostic

Specific molecular diagnostic methods have been developed involving DNA probes and PCR, but their application is limited by their technical complexity.



Surgery

It is the treatment of choice for complicated *E. granulosus* cysts like those communicating with the biliary tract and in those cysts where PAIR is not possible.

*The preferred surgical approach is pericystectomy. For pulmonary cyst, treatment consists of wedge resection or lobectomy.

*Recurrence after surgery is common.

*Pre- and postoperative chemotherapy with albendazole for 2 years after curative surgery is recommended.

*Positron emission tomography (PET) scanning can be used to follow disease activity.

*Other new treatment modalities include laparoscopic hydatid liver surgery and percutaneous thermal ablation (PTA) of the germinal layer of the cyst using radiofrequency ablation device.