



Schistosoma mansoni

Habitat

Adult worm lives in the **inferior mesenteric vein** **الوريد المساريقي السفلي**.

Morphology

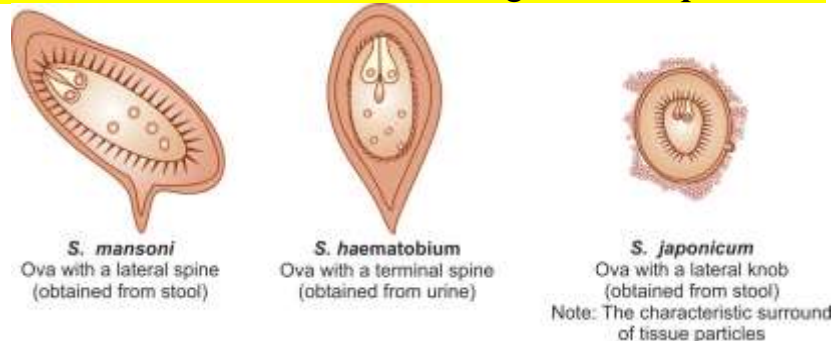
S. mansoni resembles *S. haematobium* in morphology and life cycle, except The adult worms are smaller and their integuments studded **مرصع** with prominent coarse **tubercles**.

- In the gravid female, the uterus contains very few eggs, usually 1–3 only.
- The **prepatent period** **فتره ما قبل النضج** (the interval between cercarial penetration and beginning of egg laying) is 4–5 weeks.
- The egg has a characteristic **lateral spine** more near to the rounded posterior end. The eggs are **non operculated** and **yellowish brown**.

Life cycle

Definitive host: Humans are the only natural definitive hosts, though in endemic areas monkeys and baboons have also been found infected.

Intermediate host: Fresh-water **snails** of the genus ***Biomphalaria***.



Schematic diagram to show distinguishing features of eggs of *S. mansoni*, *S. haematobium*, and *S. japonicum*.

Infective form: *Fork-tailed cercaria*.

In humans, the schistosomulae mature in the liver and the adult worms move against the blood stream into the venules of the **inferior mesenteric** group in the **sigmoidorectal** area. Eggs penetrate the gut wall, reach the colonic lumen, and are shed in feces.

Pathogenicity and Clinical Features

- **Following skin penetration by cercariae:** A pruritic طفح جلدي rash called as **cercarial dermatitis** or swimmers itch may develop locally. Cercarial dermatitis is a self-limiting clinical entity.
- **During maturation and at the beginning of oviposition** (i.e. 4–8 weeks after skin invasion): Acute schistosomiasis or Katayama fever (a serum sickness-like syndrome) with fever, rash, myalgia آلام عضلية, arthralgia ألم مفاصلي, cough سعال, generalized lymph adenopathy اعتلال الغدد اللمفاوية, and hepatosplenomegaly تضخم الطحال والكبد may develop.
- Individual with acute schistosomiasis show high peripheral blood eosinophilia.
- Parasite-specific antibodies may be detected at this stage before schistosoma eggs are identified in feces.
- **During the stage of egg deposition:** The symptomatology is mainly intestinal as the eggs are deposited in the small intestine. This condition is, therefore known as **intestinal bilharziasis** or schistosomal dysentery. Patients develop colicky abdominal pain and bloody diarrhea, which may go on intermittently for many years يستمر بشكل متقطع لعدة سنوات.
- The eggs deposited in the gut wall cause inflammatory reactions leading to microabscesses, granulomas أورام حبيبية, hyperplasia تضخم, and eventual fibrosis. Egg granulomas are found in the distal part of the colon and rectum. Ectopic lesions include hepatosplenomegaly and periportal fibrosis التليف المحيطي, portal hypertension, as some of the eggs are carried through portal circulation into liver.
- Portal hypertension may cause gastrointestinal hemorrhage.

Laboratory Diagnosis

✓ Stool Microscopy

Eggs with lateral spines may be demonstrated microscopically in stools. **Kato-katz thick smear** or other concentration methods may be required when infection is light. **Kato-katz thick smear** provides quantitative data on the intensity of infection, which is of value in assessing the degree of tissue damage and monitoring the effect of chemotherapy.

✓ Rectal Biopsy

Proctoscopic biopsy of rectal mucosa may reveal eggs when examined as fresh squash preparation between 2 slides.

✓ Serological Diagnosis

Serological diagnosis by detecting schistomal antigen and antibody is similar to that of *S.haematobium*.

✓ Imaging

Ultrasonography (USG) is useful to detect hepatosplenomegaly and periportal fibrosis.

✓ Blood Examination

Blood examination may reveal eosinophilia, and increased levels of alkaline phosphatase.

Schistosoma japonicum

Common name: Oriental blood fluke.

Habitat

The adult worms are seen typically in the venules of the superior mesenteric vein (الوريد المساريقي العلوي) draining the ileocecal region. They are also seen in the intrahepatic portal venules and (المستقيمية) hemorrhoidal plexus of veins.

Morphology

Morphologically, they are similar to the schistosomes described above except:

- The adult male is comparatively slender (0.5 mm thick) and does not have cuticular tuberculations.
- In the gravid female, the uterus contains as many as 100 eggs at one time and up to 3,500 eggs may be passed daily by a single worm.
- The prepatent period is 4–5 weeks.
- The eggs are smaller and more spherical than those of *S. haematobium* and *S. mansoni*. The egg has **no spine**, but shows a lateral small rudimentary knob.

Life Cycle

Life cycle of *S. japonicum* is similar to *S. haematobium* with the following exceptions.

Definitive host: Man is the definitive host but in endemic areas, natural infection occurs widely in several domestic animals and rodents, which act as reservoirs of infection.

Intermediate host: Amphibian snails of the genus *Oncomelania*.

Infective form for humans: Fork tailed cercaria.

- Eggs deposited in the **superior mesenteric venules** penetrate the gut wall and are passed in feces.
- They hatch in water and the **miracidia** infect the **intermediate hosts**, amphibian **snails** of the genus *Oncomelania*.
- The fork-tailed cercaria, which escapes from the snails, is the **infective form** for men and other definitive hosts.

Pathogenicity and Clinical Features

Disease caused by *S. japonicum* is also known as **Oriental Schistosomiasis** or **Katayama disease**.

- Its pathogenesis is similar to that in other Schistosomiasis, but probably because of the higher egg output, the clinical manifestations are more severe.

Differentiating Features of *S. haematobium*, *S. mansoni* and *S. japonicum*

	<i>Schistosoma haematobium</i>	<i>Schistosoma mansoni</i>	<i>Schistosoma japonicum</i>
Habitat	Veins of the vesical and pelvic plexuses, less commonly in portal vein and its mesenteric branches	Inferior mesenteric vein and its branches	Superior mesenteric vein and its branches
Morphology			
Size: Male	1.5 cm × 1 mm	1 cm × 1 mm	1.2–2 cm × 0.5 mm
Female	2 cm × 0.22 mm	1.4 cm × 0.25 mm	2.6 cm × 0.3 mm
Integument	Finely tuberculated	Grossly tuberculated	Non-tubercular
Number of testes	4–5 in groups	8–9 in a zigzag row	6–7 in a single file
Ovary	In the posterior one-third of the body	In the anterior half of the body	In the middle of the body
Uterus	Contains 20–30 eggs	1–3 eggs	50 or more eggs
Egg	Elongated with terminal spine	Elongated with lateral spine	Round with small lateral knob
Cephalic glands in Cercariae	2 pairs oxyphilic and 3 pairs basophilic	2 pairs oxyphilic and 4 pairs basophilic	5 pairs oxyphilic, no basophilic
Distribution	Africa, Near East, Middle East, India	Africa and south America	China, Japan, far east (oriental)
Definitive host	Man	Man	Man (mainly) domestic animals & rodents (which act as reservoir of infection)
Intermediate host	Snail of Genus <i>Bulinus</i>	Snail of Genus <i>Biomphalaria</i>	Amphibian snail of Genus <i>Oncomelania</i>