

TRANSVERSUS ABDOMINIS PLANE (TAP) BLOCK

Osama Aziz

B.M.TCH ANAESTHESIA
2024- 2023

College of Health and Medical Techniques
Anesthesia Techniques Department
Al_Mustaqbal University
Babylon, Iraq



TRANSVERSUS ABDOMINIS PLANE (TAP) BLOCK

Abdominal field blocks have been around for a long time and have been extensively used as they are mostly technically unchallenging. They, however, provide limited analgesic fields, hence multiple injections are usually required. Traditionally these blocks have blind end points (pops) making their success unpredictable. The description of the landmark technique for performing transversus abdominis plane (TAP) block advocated a single-entry point, **the triangle of Petit**, to access a number of abdominal wall nerves hence providing more widespread analgesia. More recently, ultrasound guided TAP block has been described with promises of better localization and deposition of the local anesthetic with improved accuracy.

Anatomy Innervation of the anterolateral abdominal wall arises from the anterior rami of spinal nerves T7 to L1. **These include the intercostal nerves (T7-T11), the subcostal nerve (T12), and the iliohypogastric and ilioinguinal nerves (L1).**

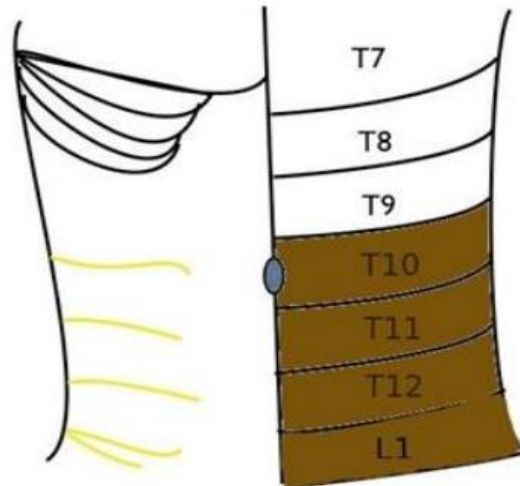


Figure 1. Cutaneous innervation of the abdominal wall . Coloured region is mostly blocked by a single injection posterior TAP block.

The anterior divisions of T7-T11 continue from the intercostal space to enter the abdominal wall between the internal oblique and transversus abdominis muscles until they reach the rectus abdominis, which they perforate and supply, ending as anterior cutaneous branches supplying the skin of the front of the abdomen.

Midway in their course they pierce the external oblique muscle giving off the lateral cutaneous branch which divides into anterior and posterior branches that supply the external oblique muscle and latissimus dorsi respectively. The anterior branch of T12 communicates with the iliohypogastric nerve and gives a branch to the pyramidalis. Its lateral cutaneous branch perforates the internal and external oblique muscles and descends over the iliac crest and supplies sensation to the front part of the gluteal region. The iliohypogastric nerve (L1) divides between the internal oblique and transversus abdominis near the iliac crest into lateral and anterior cutaneous branches, the former supplying part of the skin of the gluteal region while the latter supplies the hypogastric region. The ilioinguinal nerve (L1) communicates with the iliohypogastric nerve between the internal oblique and transversus abdominis near the anterior part of the iliac crest. It supplies the upper and medial part of the thigh and part of the skin covering the genitalia.

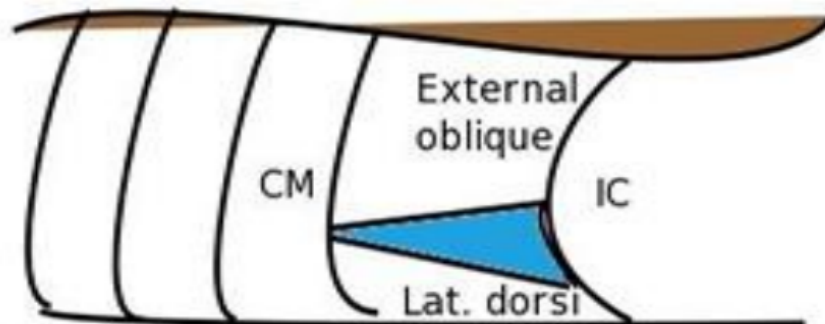


Figure 3. Lumbar triangle of Petit between external oblique muscle and latissimus dorsi.
CM: costal margin, **IC:** iliac crest.

Block Technique

The aim of a TAP block is to deposit local anesthetic in the plane between the internal oblique and transversus abdominis muscles targeting the spinal nerves in this plane. The innervation to abdominal skin, muscles and parietal peritoneum will be interrupted. If surgery traverses the peritoneal cavity, dull visceral pain (from spasm or inflammation following surgical insult) will still be experienced. The block can be performed blind or using the ultrasound

BLIND TAP

The point of entry for the blind TAP block is the lumbar triangle of Petit. This is situated between the lower costal margin and iliac crest. It is bound anteriorly by the external oblique muscle and posteriorly by the latissimus dorsi. This technique relies on feeling double pops as the needle traverses the external oblique and internal oblique muscles. A blunt needle will make the loss of resistance more appreciable.

Ultrasound- guided TAP

The ultrasound probe is placed in a transverse plane to the lateral abdominal wall in the midaxillary line, between the lower costal margin and iliac crest. The use of ultrasound allows for accurate deposition of the local anesthetic in the correct neurovascular plane. If prolonged analgesia is required beyond the duration of a single shot of local anesthetic, a catheter can be introduced into the transversus abdominis plane through a Touhy needle. After opening up the plane with 2 ml of saline, the catheter is introduced around 3 cm beyond the needle tip. Position is verified by injecting the local anesthetic bolus (20ml). An infusion of a dilute local anesthetic is started at a rate of 7 to 10 ml per hour.

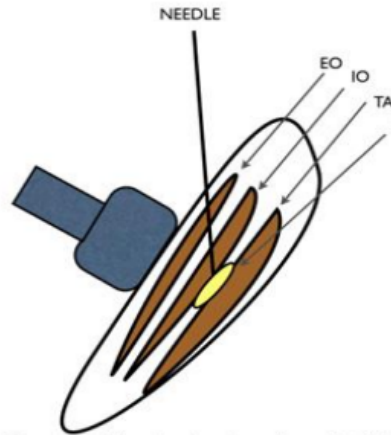


Figure 4. Schematic view of an ultrasound-guided transversus abdominis plane block. **EO:** external oblique, **IO:** internal oblique, **TA:** transversus abdominis, **LA:** local anaesthetic

Indications

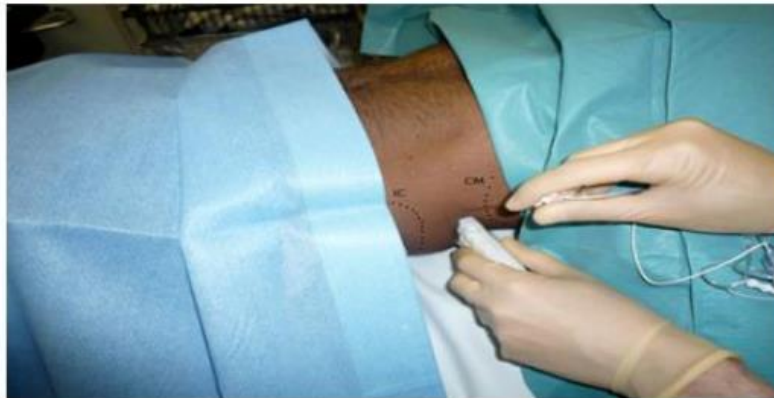This block is indicated for any lower abdominal surgery including **appendectomy, hernia repair, caesarean section, abdominal hysterectomy and prostatectomy.**

Efficacy in laparoscopic surgery has also been demonstrated. Bilateral blocks can be given for midline incisions or laparoscopic surgery. Care should be taken not to exceed recommended safe doses of local anesthetic agent with bilateral injections. There has been controversy in the literature regarding the spread and level of block achieved with a single TAP injection. Whilst early studies showed a T7 to L1 spread with a single posterior injection making the block suitable for midline abdominal incisions, other studies, however, failed to demonstrate a spread cephalad to T10 making it more suited for lower abdominal surgery. In a small cadaveric study, T11, T12 and L1 were most consistently present in the transversus abdominis plane, while T10 was present in 50% of the cases. It is reasonable to expect a good analgesic effect in the region between T10 and L1 following a single posterior injection. Augmentation with a subcostal injection will help attain a higher block up to T7. The subcostal TAP is a modification of the

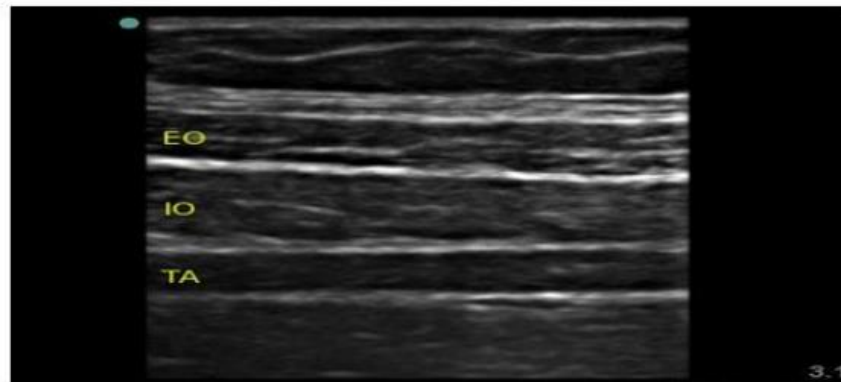
original technique in which the ultrasound probe is placed just beneath the costal margin and parallel to it. The needle is then introduced from the lateral side of the rectus muscle in plane of the ultrasound beam and 10 ml of local injected into the transversus abdominis plane to extend the analgesia provided by the posterior TAP block above the umbilicus.

TECHNIQUE

Whilst the patient is in the supine position, a high frequency ultrasound probe is placed transverse to the abdominal wall between the costal margin and iliac crest.



The image produced shows (from above downwards) skin, subcutaneous tissue, fat, external oblique, internal oblique, transversus abdominis. The peritoneum and bowel loops may also be visualized deeper to the muscles.



The needle is introduced in plane of the ultrasound probe directly under the probe and advanced until it reaches the plane between the internal oblique and transversus abdominis muscles. The needle can also be introduced a few centimeters medial to the probe (a distance equivalent to the depth of the plane as viewed on the ultrasound image). The probe will have to follow the needle entry point medially in its superficial path and is then returned to its original position in the midaxillary line as the needle is directed deeper. Upon reaching the plane, 2 ml of saline is injected to confirm correct needle position after which 20 ml of local anesthetic solution is injected. The transversus abdominis plane is visualized expanding with the injection (appears as a hypoechoic space).

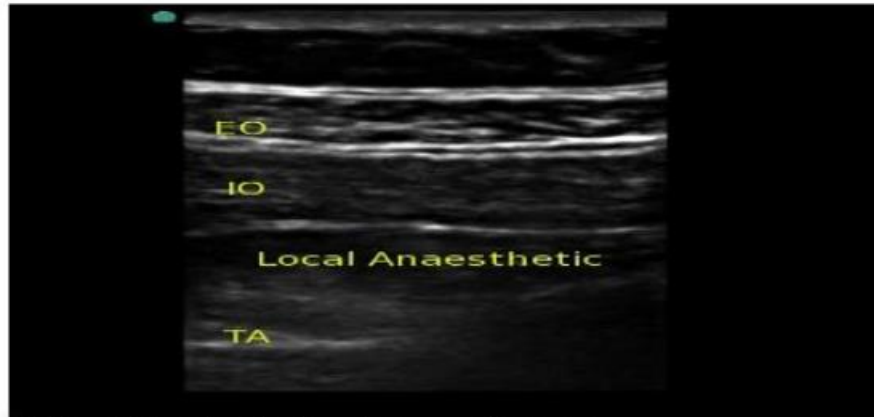


Figure 7. Correct local anaesthetic deposition in the transversus abdominis plane.

Complications

There have been no reported complications to date with the ultrasound guided technique. A few complications have been reported with blind TAP block, the most significant of which was a case report of *intrahepatic injection*. Other complications include: *intrapertoneal injection, bowel hematoma and transient femoral nerve palsy. Local anesthetic toxicity could also occur due to the large volumes required to perform this block especially if it was done bilaterally.* As with any regional technique, careful aspiration will help avoid intravascular injections.