

Anatomy and physiology as related to dental prosthesis

In order to construct a prosthesis a dentist require an understanding and a thorough knowledge of the anatomy and physiology of the supporting structures to assure successful results.

Osteology

The osseous structures not only support the denture but have a direct relation on the impression making procedure, position of teeth and the contours of the finished denture.

It is quite essential to have knowledge of the tissues that support the maxillary and the mandibular dentures. These tissues also help the dentures in obtaining their retention and stability. There are certain tissue areas or regions in the maxillary and mandibular edentulous foundations, which are better suited to bear the stresses due to mastication, and are called as *stress bearing areas*. While there are other tissue areas which are not quite suited to take up these stresses, either due to their anatomy or due to the structures that lie beneath them and are called *stress relief areas*. The structures which limit the extension of the maxillary and mandibular complete dentures are called *border-limiting areas*.

The mucous membrane that lines the oral cavity varies in character in different zones and denture border depends on the function of the different zones. The sub-mucosa, which is a connective tissue, attaches the mucosa to the underlying structures. The submucosa varies in composition depending on whether the mucosa is firmly or loosely attached to the bony structure and whether there is muscle tissue between itself and the underlying bone. The blood vessels present in the submucosa supply blood to the edentulous foundation and the nerves innervate it.

Factors that influence the form and size of the supporting bone include the following:

1. The original size and arch form before extractions.
2. The severity of periodontal disease.
3. Amount of alveoloplasty at the time of tooth extraction.
4. Forces developed by the surrounding musculature.
5. Forces accruing from the wearing of dental prostheses.
6. The relative length of time different parts of the jaws have been edentulous.
7. Unknown genetic predisposition to bone resorption.

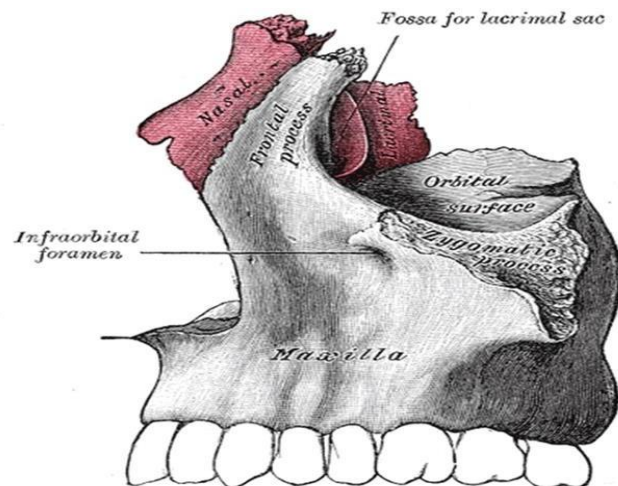
STRUCTURES RELATED TO THE MAXILLARY AND MANDIBULAR DENTURE EDENTULOUS FOUNDATION

These structures can be divided into two categories:

1. Supporting structures: These are the structures that support the denture
2. Border limiting structures: These are the structures that limit the border extent of the denture (maxillary and mandibular denture).

Osteology of the oral cavity: the maxilla:

The maxillary denture is supported by two pairs of bone the maxillae and the palatine bones whereas the mandibular denture is supported by one bone the mandible. There are two maxillae each consisting of a central body and four processes: alveolar, frontal, zygomatic and palatine. Some area of the body and two of the processes are involved in the support of the maxillary denture.

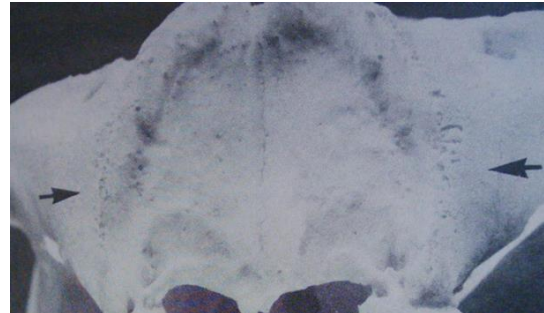


Supporting Structures in the Maxillary Edentulous Foundation

1. Zygomatico-alveolar crest (malar process).
2. Alveolar process
3. The palatine bone
4. Palatine process of the maxilla
5. The incisive fossa
6. The pterygoid hamulus
7. Maxillary tuberosity
8. The greater palatine foramen
9. Cuspid eminence.

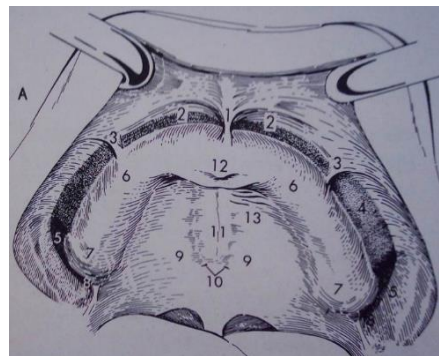
Zygomatico-alveolar crest (malar process):

This is located opposite the 1st molar region some denture require relief over this area to prevent soreness and aid in retention especially in sever resorbed ridge.



Alveolar process:

It arises from the lower surface of the maxilla. It consists of two parallel plates of cortical bone which unite behind the last molar to form the tuberosity. The part of the alveolar process that remain after loss of teeth is called the residual alveolar ridge. The maxillary ridge act as a secondary stress bearing area. The slopes of the ridges do help in the stability of the denture during function. Hence, some of the stress does get transmitted through the slopes.



The palatine processes of maxillary bone:

They arises as horizontal plates from the body of the maxilla. The two plates unite in the mid line forming the mid palatine suture. Sometime overgrowth of bone seen in this area called torus palatinus. The hard palate resist resorption (primary stress bearing area).

The area of sutural joint (mid palatal raphe) is covered by firmly adherent mucous membrane to the underlying bone with little submucosal tissue. There is, therefore, no resiliency in this region and stress cannot be applied

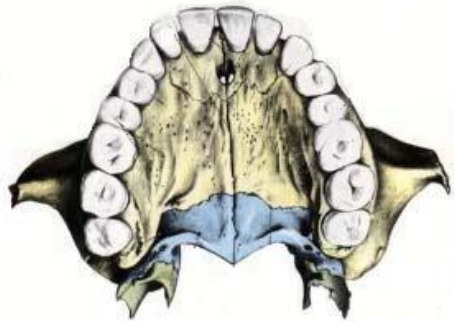
in this region. This is a stress relief area in the maxillary edentulous foundation.

Clinical consideration:

During final impression procedure the mid palatal raphae is relieved in order to create equilibrium between the resilient and non-resilient tissue supports.

The palatine bone:

The horizontal plate of palatine bone unite with the posterior rough border of the horizontal palatal process of maxillae. The posterior border of palatine bone unite at midline forming the posterior nasal spine. The soft palate is attached to this posterior border. The posterior palatal seal (PPS) is placed at the junction between immovable and movable parts of the soft palate.



Posterior palatal seal area: The soft tissue area limited posteriorly by the distal demarcation of the movable and non-movable tissues of the soft palate and anteriorly by the junction of the hard and soft palates on which pressure, within physiologic limits, can be placed; this seal can be applied by a removable complete denture to aid in its retention.

Vibrating line:

An imaginary line across the posterior part of the soft palate marking the division between the movable and immovable tissues; this line can be identified when the movable tissues are functioning.

Incisive foramen:

The incisive foramen is located in the palate on the median line posterior to the maxillary central incisor. In edentulous mouth it comes nearer to the crest of the ridge as resorption progress. Failure to relieve this area may result in irritation and burning sensation at the anterior part of the palate.

Incisive Papilla

It is a pad of fibrous connective tissue anteriorly overlying the incisive foramen. The submucosa in this region contains the nasopalatine nerves and vessels.

Significance

- A stable landmark is related to the incisive foramen through which the neurovascular bundle emerge and lies on the surface of the bone.
- It is a biometric guide giving information about location of maxillary canines (a perpendicular line drawn posterior to the center of the incisive papilla to sagittal plane passes through the canines).
- It is a biometric guide giving information on positional relation of central incisors, which are about 8-10 mm anterior to the incisive papilla.

Clinical consideration:

During the impression procedure, care should be taken not to compress the papilla. This is one of the *relief areas* of the maxillary edentulous foundation. Hence the incisive papilla should be relieved.

Anterior (greater) palatine foramen:

This is located medial to the third molar at the junction of the ridge and horizontal plates of palatine bone .Rarely would a relief be required in the denture base over this area since the nerve and blood vessels are retained in a groove and covered by thick soft tissue.

Maxillary tuberosity:

It is that part of the residual ridge that extend distally from the area of the 2nd molar to the hamular notch. The *tuberosities* often are covered with dense fibrous connective tissues with minimal compressibility. In this situation, considerable support is offered to the denture. Sometimes cause problem in maxillary denture construction such as:

1. Enlargement of the tuberosity with the presence of bilateral undercuts negatively affect the insertion and removal of denture.
2. The presence of pendulous tuberosities cause a reduction in the interarch distance in the posterior region against the retro molar pad.
3. To prevent oro-antral fistula, it is important to have an occlusal radiograph before surgical resection of the tuberosity.
4. In case of severe undercuts at the tuberosity region, the undercut on the preferential chewing side should be reduced.
5. The last posterior tooth should not be placed on the tuberosity.

Hamular notch:

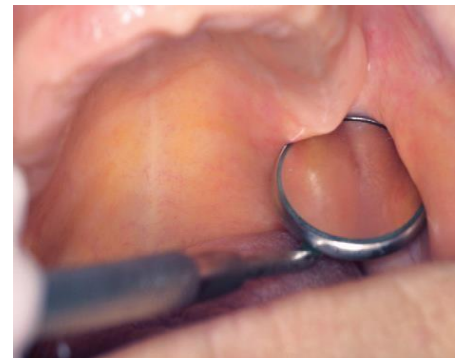It is a narrow cleft of loose connective tissue, which is approximately 2 mm in extent antero-posteriorly. This structure is bounded by the maxillary tuberosity anteriorly and the pterygoid hamulus posteriorly and marks the postero-lateral limit of the upper denture. The submucosa in this region is thick and made up of loose areolar tissue. A seal can be obtained by utilizing this area as it can be displaced to a certain extent without trauma.

Significance

1. Constitutes the lateral boundary of the posterior palatal seal area in the maxillary foundation.
2. The pterygomandibular raphe attaches to the hamulus.

Clinical considerations: The denture should not extend beyond the hamular notch, failure of which will result in:

1. Restricted pterygomandibular raphe movement.
2. When mouth is wide open, the denture dislodges.
3. Pterygomandibular raphe may be sandwiched below the denture.



Cuspid eminence:

It is a bony elevation on the residual ridge formed after extraction of the canine located over the canine root and serve as a guide for positioning of artificial canine.

The limiting structures of the upper denture can be divided into three areas: (1) the labial vestibule, which runs from one buccal frenum to the other on the labial side of the ridge; (2) the right and left buccal vestibules, which extend from the buccal frenum to the hamular

notch; and (3) the vibrating line, which extends from one hamular notch to the other across the palate.

Osseous structures associated with the mandibular denture:

1. Coronoid process.
2. Residual alveolar ridge.
3. Buccal shelf area.
4. Mental foramen.
5. Mylohyoid ridge.
6. Genial tubercles.
7. Torus mandibularis.
8. External oblique ridge.

The mandible is the movable member of the stomatognathic system. It consist of:

- A. The body of the mandible.
- B. The rami: Each ramus terminate at its upper extremity into two processes, posteriorly the condyloid and anteriorly the coronoid process.

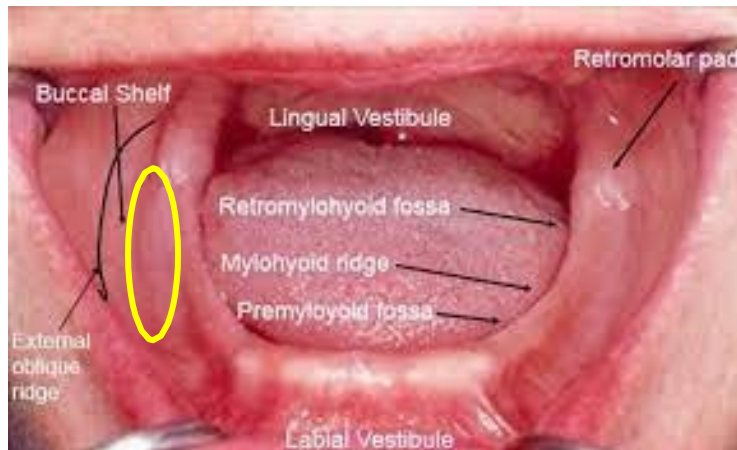Coronoid process: It is the anterior process and continuous with the anterior border of the ramus. If the distobuccal flange of maxillary denture is too thick it will cause discomfort and dislodgment of upper denture when the mandible is protruded and move from side to side. Trimming of the flange will solve the problem.

Residual alveolar ridge:

It is that part which remain after loss of teeth. The bone underlying the crest of RR is cancellous which makes it unfavorable for resisting applied forces from a denture.

Buccal shelf area: The *buccal shelf* is the area between the mandibular buccal frenum and the anterior edge of the masseter muscle. Medially it is bound by the crest of the ridge and laterally by the boney external oblique ridge and distally by the retromolar pad. The buccinators muscle fibers attach horizontally along the boney oblique ridge. As resorption of the ridge occurs, the buccal shelf does not resorb because of its muscle attachments on the posterior and lateral borders. The alveolar ridge of the

mandible is significantly medial to the inferior border of the mandible; therefore, as the ridge resorbs, the denture-bearing surface becomes flatter and widens towards the buccal shelf. The shelf is dense cortical bone and lies at right angles to vertical occlusal forces, and is therefore a primary stress-bearing area for the denture.

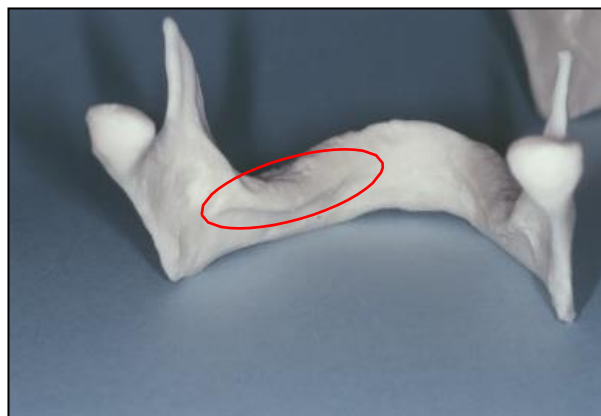


Mental foramen:

It is located on the lateral surface of the mandible between 1st and 2nd premolar half way between the lower border and alveolar crest. The *mental nerve* exits the *mental foramen* below the alveolar ridge, but with continued resorption of the ridge, the mental foramen can become positioned at the crest of the ridge and be compressed by the denture. This causes pain or even altered sensation in the lip (numbness in the lower lip).

Mylohyoid ridge:

It runs along the lingual surface of the mandible. Anteriorly the ridge lies close to the inferior border of mandible while posteriorly, it lies flush with the residual ridge. The thin mucosa over the mylohyoid ridge may get traumatized and should be relieved. The area under this ridge is an undercut.



Genial tubercles:

Also called mental spines, 2- 4 in number situated on the lingual surface of the body of mandible in the mid line. They represents the muscle attachment of the genioglossus and geniohyoid muscle .it is usually seen below the crest of the ridge.

Significance

- In a severely resorbed ridge, it is seen above the residual alveolar ridge and hence, it should be relieved.
- The mucosa covering the genial tubercle is thin and tightly adherent to the underlying bone.

Clinical consideration:

It should be relieved with a spacer, failure of which leads to ulceration.

Mandibular tori

Mandibular tori are lingual bilateral or unilateral prominences of cortical bone in the premolar area. But they may extend posteriorly to the molar area. Small tori may only require relief in the denture. Large tori require removal before a denture can be fabricated.

External oblique ridge:

It is a ridge of dense bone extended from just above the mental foramen superiorly and distally to be continuous with the anterior border of the ramus. In most individuals it is the anatomic guide for lateral end of the buccal flange of lower denture.

Retromolar pad:

The retromolar pad is a triangular pad of tissue at the distal end of the residual ridge. The anterior portion of the triangle is keratinized tissue of the remnant gingiva of the third molar called the pear-shaped pad. The posterior aspect of the triangle is composed of thin, non-keratinized epithelium; loose connective tissue; glandular tissue; fibers of the temporalis tendon and of the buccinators and superior constrictor muscles; and the pterygomandibular raphe. The underlying bone is dense cortical bone because of the muscle attachments and is resistant to resorption. The denture should cover the retromolar pad because of the support and absence of long-term cortical bone resorption.

Maxillary and Mandibular Stress-Bearing Areas

Maxillary

- 1° firm tuberosities
- 1° hard palate on either side of palatal raphe
- 2° alveolar ridge
- 2° rugae

Mandibular

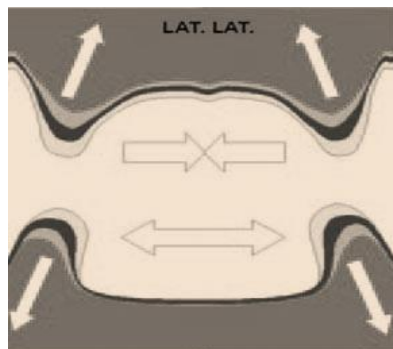
- 1° buccal shelves
- 1° retromolar pads
- 2° alveolar ridge

Areas Requiring Relief in Final Impression

- 2° stress-bearing areas
- Palatal torus
- Median palatal raphe
- Mandibular tori
- Retromylohyoid ridge
- Undercuts or sharp bony prominence on ridges.

The pattern of bone resorption:

The maxilla resorb upward and inward to become progressively smaller (centripetal). While the mandible resorb downward and outward to become gradually wider (centrifugal). This progressive change of the mandible and maxillae makes many edentulous patients appear to be prognathic.



Thinking Notes/ The mean denture bearing area for edentulous maxillae are 23cm² while for mandible 12cm² in contrast with 45cm² area of PDL in each dental arch.

The masticatory loads recorded for the natural teeth are about 20 Kg while maximum forces of 6 Kg during chewing have been recorded with complete denture. In fact, maximal bite forces appear to be five to six times less for complete denture wearer than person with natural teeth.