



4th Year Lec. No. 7

Fixed orthodontic Appliances

They are devices which have attachments that are fixed onto the tooth surface, and forces are exerted via these attachments using archwires and /or other auxiliaries. The appliances cannot and should not be adjusted or removed by the patient.

ADVANTAGES OF FIXED ORTHODONTIC APPLIANCES

1. Precise tooth control is possible.
2. Multiple tooth movements are possible.
3. Patient cooperation is reduced in comparison to removable appliance
4. All types of tooth movements are possible.

DISADVANTAGES OF FIXED ORTHODONTIC APPLIANCES

1. Oral hygiene requirement.
2. Esthetics.
3. Special training for operator.
4. Increased cost of treatment.
5. Increased chair side time.
6. Anchorage control is more difficult.
7. The possibility of producing adverse tooth movement.

INDICATIONS FOR THE USE OF FIXED APPLIANCES

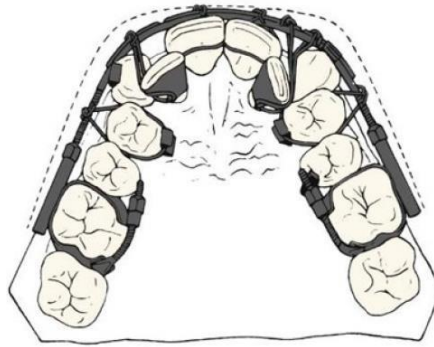
1. Correction of mild to moderate skeletal discrepancies. As fixed appliances can be used to achieve bodily movement it is possible, within limits, to compensate for skeletal discrepancies and treat a greater range of malocclusions.
2. Intrusion/extrusion of teeth.
3. Correction of rotations.
4. Overbite reduction by intrusion of incisors.
5. Multiple tooth movements required in one arch.
6. Active closure of extraction spaces, or spaces due to hypodontia.

The development of contemporary Fixed Appliances

Edward Angle's position as the "father of modern orthodontics" is based not only on his contributions to classification and diagnosis but also on his creativity in developing new orthodontic appliances.

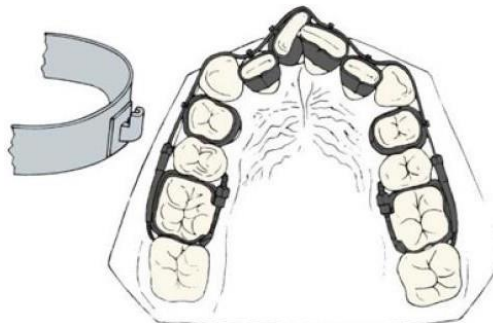
E-Arch:

Edward Angle's E-arch from the early 1900s. Ligatures from a heavy labial arch were used to bring the malposed teeth to the line of occlusion.



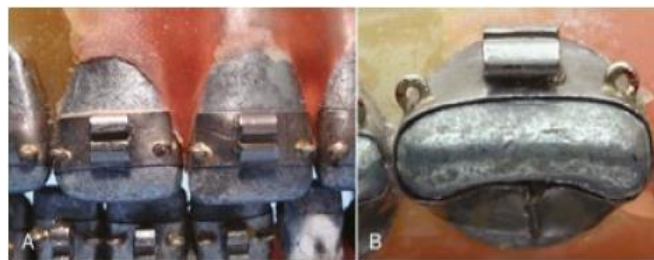
Ribbon Arch

Angle's ribbon arch appliance, introduced about 1910, was well-adapted to bring teeth into alignment but was too flexible to allow precise positioning of roots. It was the first introduction of brackets. Used a gold wire of 10x20.



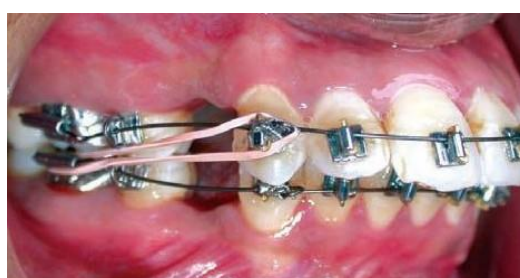Edgewise

To overcome the deficiencies of the ribbon arch, Angle reoriented the slot from vertical to horizontal and inserted a rectangular wire rotated at 90 degrees to the orientation it had with the ribbon arch, thus the name “edgewise”



Begg Appliance

The Begg appliance used a modification of the ribbon arch attachment, into which round archwires were pinned. A variety of auxiliary archwires were used in this system to obtain control of root position.

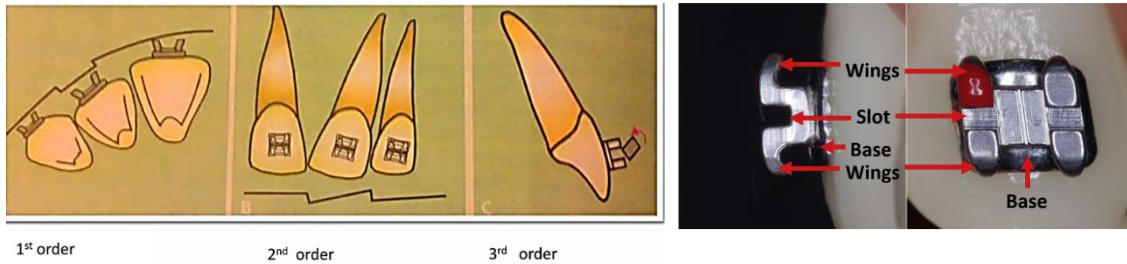




4th Year Lec. No. 7

Traditional standard edgewise

In this appliance, the orientation of the bracket slot is at right angles to the long axis of the tooth, and the thickness of the bracket base is the same for all types of teeth. During treatment, bends are placed in the archwire to position individually each tooth in the buccolingual direction (in-out or first-order bends). As well as to idealize the angulation of the long axis of the tooth in the mesiodistal direction (tip or second-order bends) and in the buccolingual direction (torque or third-order bends).

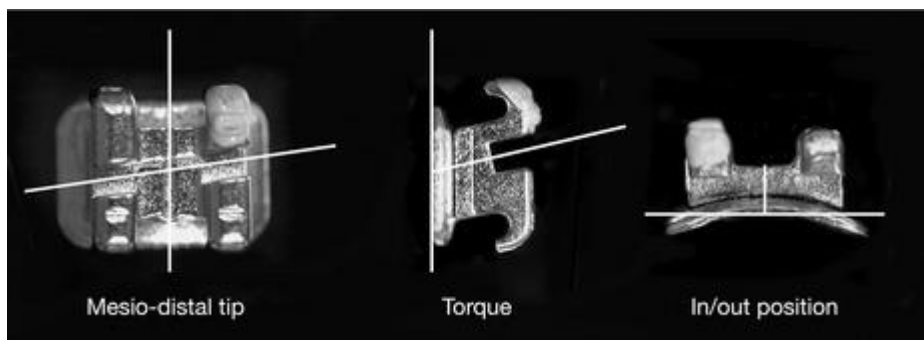


Straight-Wire Appliance

Angle used the same bracket on all teeth, as did the other appliance systems. In the 1980s, Andrews developed bracket modifications for specific teeth to eliminate the many repetitive bends (first, second and third order bends) in archwires that were necessary to compensate for differences in tooth anatomy, and bonding made it much easier to have different brackets for each tooth. The result was the “straight-wire” appliance. This was the key step in improving the efficiency of the edgewise appliance.

Features of the brackets of straight wire appliance:

- Variable distance from base of slot to base of bracket for correct in/out position.
- Pre-angulated slots for correct mesiodistal tooth angulation or tip;
- Bracket bases inclined for correct inclination or torque.





4th Year Lec. No. 7

Components of Fixed orthodontic Appliance:

They can be broadly classified into:

- I. Attachments
- II. Archwire.
- III. Auxiliaries.

I- Attachments:

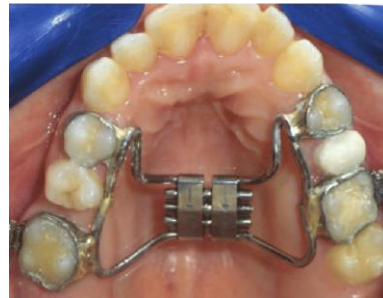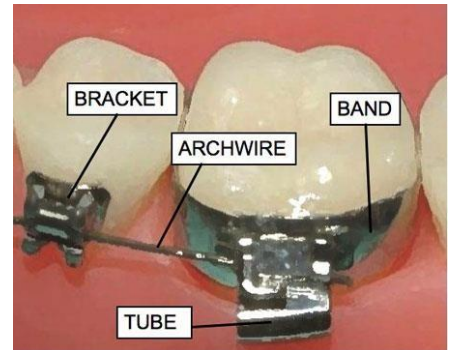
These include:

- A. Bands
- B. Brackets.
- C. Other attachments: Buccal tubes, Buttons, eyelet, sheath, cleat,etc.

The attachments may be welded to bands, or directly placed on the tooth surface.

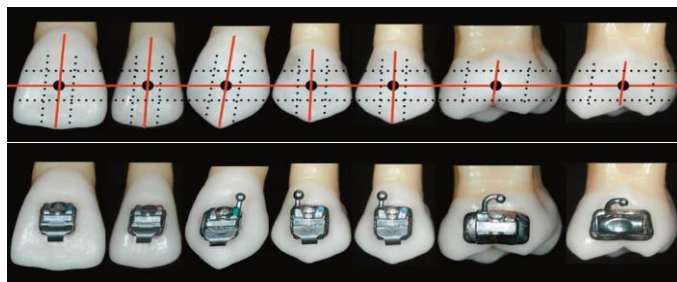
A. Bands:

These are rings encircling the tooth to which buccal, and as required, lingual attachments are soldered or welded. Until the 1980s, the only practical way to place a fixed attachment was to put it on a band that could be cemented to a tooth.



B. Brackets:

Each bracket is made up of a bracket base, stem with bracket slot, tie-wings to retain the ligature as it secures the arch wire into the slot, and some form of hook used for intramaxillary or intermaxillary attachment of elastics or coils.



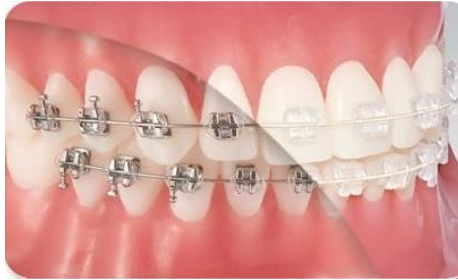

4th Year Lec. No. 7

There are many bracket types, the basic ways to classify brackets are:

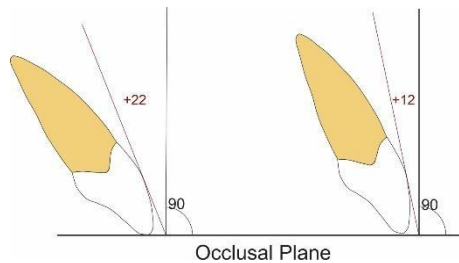
1- According to material:

- a. Metallic: e.g. Stainless-steel.
- b. Non-Metallic (Esthetic): Composite, Ceramic, Sapphire.




2- According to prescription (the amount of built-in tip and torque):

- a. Standard edgewise (zero tip and torque).
- b. Roth prescription
- c. *McLaughlin, Bennett, & Trevisi (MBT) prescription,etc.*



3- According to slot size:

- a. 18 mil (milli-inch) slot. (0.018 x 0.025 inch, where 0.018 is the width, and 0.025 is the slot depth)
- b. 22 mil slot (0.022 x 0.028 inch, where 0.022 is the width, and 0.028 is the slot depth)

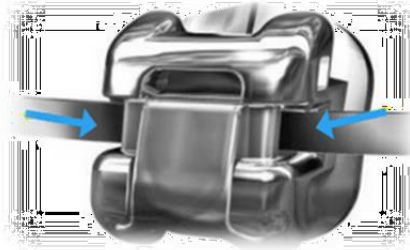




4th Year Lec. No. 7

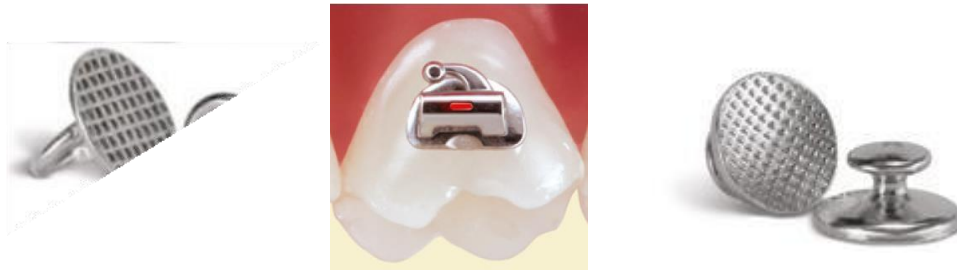
4- According to ligation method

- a) Conventional ligating.
- b) Self-ligating brackets (which utilize a permanently installed, moveable component to entrap the arch wire).



C. Other attachments: including but not limited to:

- Buccal Tubes: Used on molars.
- Buttons: Small, mushroom-shaped orthodontic attachments that can be bonded directly onto a tooth or welded on a band. They are usually used on the palatal surface of the teeth (to provide a couple force), or on a partially erupted tooth.
- Eyelets: mostly on partially erupted teeth.



II- Archwires:

The amount and type of force applied to an individual tooth can be controlled by varying the cross-sectional dimension and form of the archwire, and/ or the material of its construction.

In the initial stages of treatment, a wire which is flexible with good resistance to permanent deformation is desirable (e.g. Nickel-titanium archwires), so that displaced teeth can be aligned without the application of excessive forces.

In contrast, in the later stages of treatment rigid arch wires are required to engage the archwire slot fully and to provide fine control over tooth position while resisting the unwanted effects of other forces, such as elastic traction (e.g. stainless-steel).

Archwires can be described according to their material, dimensions, and form.

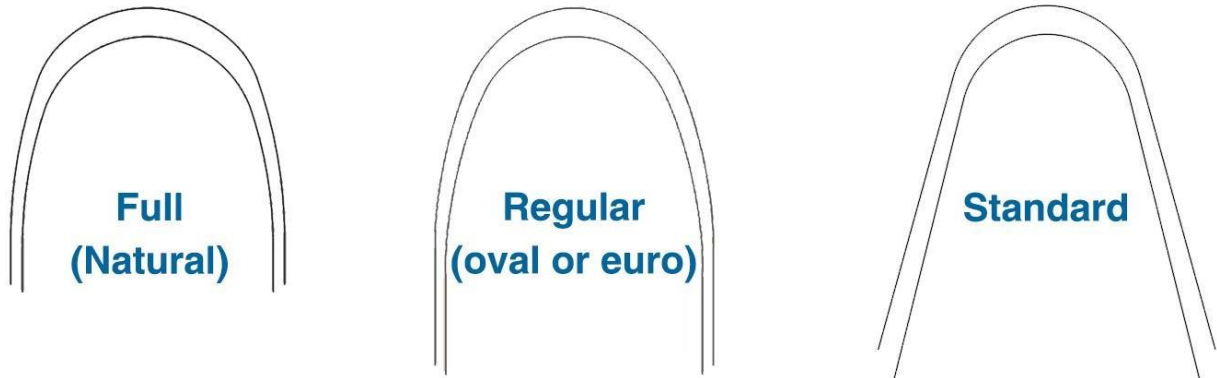
Material: e.g. stainless-steel, Nickel titanium, Beta Titanium, Etc.



4th Year Lec. No. 7

Dimensions: Usually archwire dimension is expressed in milli-inches (= 0.025 mm). A 16 milli-inch (0.016") is a round 0.4 mm wire, and a 16x22 is a rectangular 0.4x0.55 mm wire.


Form: It may be a full form, regular (or oval) form, or standard form.



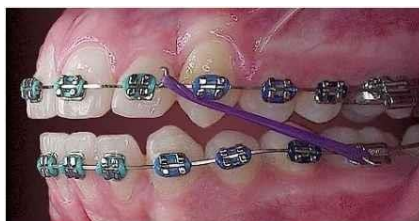III- Auxiliaries

There are many auxiliaries used with fixed orthodontic appliance, among them are:

Ligatures: these are used to secure the archwire into the bracket. They include elastomeric modules and ligature wires.



Intra-oral elastics: available in different sizes and strength to provide intra and interarch traction. For most purposes they must be changed daily. Class II and Class III elastics are ways to describe these elastics according to their use.



Elastomeric modules (Elastomeric chain, or Power chain)

A chain of connected elastomeric rings used as a force-producing mechanism for orthodontic tooth movement. Elastomeric chains can be long, short, or closed, depending on whether or not there is a distance between the rings at its passive state.



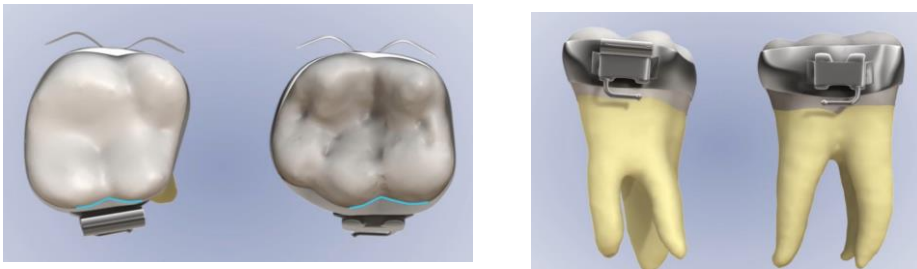
4th Year Lec. No. 7

Fixing attachments

Attachments can be fixed to the teeth surfaces by either banding or bonding. The procedure of cementing a band to the tooth is called “banding”. The method of fixing attachment directly to enamel using resins is called bonding. It greatly enhances esthetics, and maintenance of oral hygiene as compared to banding.

Banding involves:

- Separation of teeth.
- Selection of proper band size with close fit.
- Cementation of the band preferably using glass ionomer cement.



A number of indications still exist for use of a band rather than a bonded attachment, including:

- Teeth that will receive heavy intermittent forces against the attachments, e.g., an upper first molar against which extraoral force is placed via a headgear.
- Teeth that will need both buccal and lingual attachments such as a molar with both headgear tube and transpalatal bar.
- Teeth with short clinical crowns, so that bonded brackets are difficult to place correctly.
- Teeth with extensive restorations.

Bonding may be made directly in the office, or indirectly through a lab. Direct bonding involves:

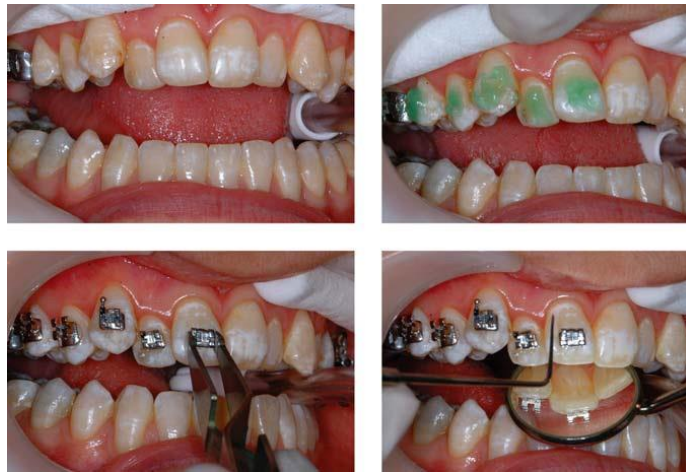- Cleaning the tooth surface, to remove any pellicle using a slow hand piece and prophyl brush or cup;
- Acid-etching the enamel surface using 35-37% phosphoric acid for 15–30 seconds;
- Washing and drying the tooth surface;



4th Year Lec. No. 7 Direct Bonding

- Placing unfilled primer on the etched area of the tooth;
- Placing composite resin on the bracket base;
- Positioning the bracket on the tooth crown;
- Cleaning up excess composite from around the bracket base; and
- Curing the composite, either chemically or with a blue light source.

It is very important to clean up excess composite or ‘flash’ as this can create problems in maintaining high levels of oral hygiene and result in demineralization around the bracket, a major risk of fixed appliance therapy.



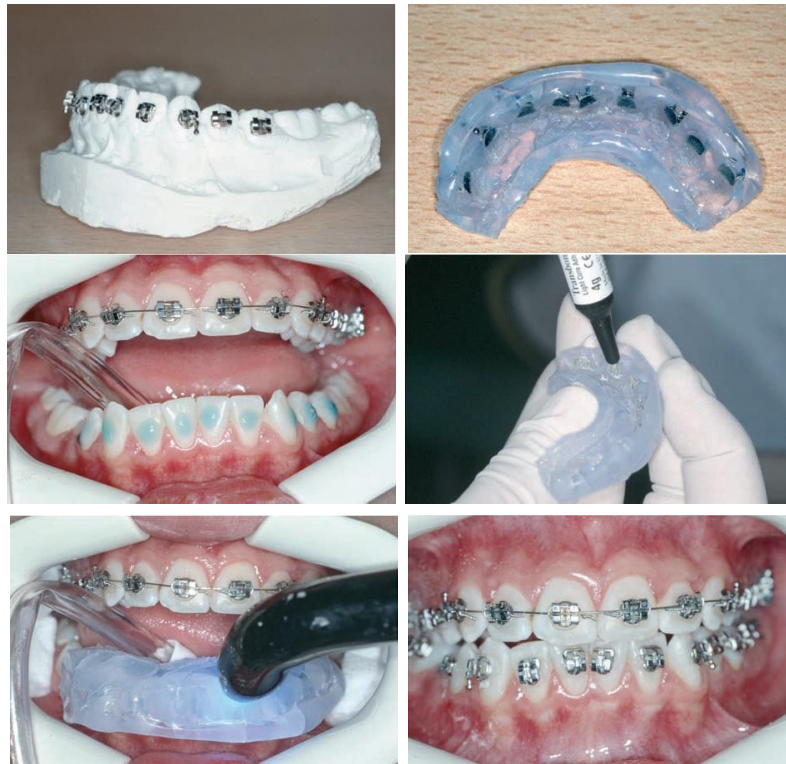In **indirect bonding**, the brackets are glued with a temporary material to the teeth on the patient’s models, transferred to the mouth with some sort of tray into which the brackets become incorporated, and then bonded simultaneously with adhesives.

The main **advantages** of indirect compared to direct bonding are:

- a. The brackets can be positioned more accurately in the laboratory.
- b. The clinical chair time is decreased.

However, the method is:

1. Technique-sensitive.
2. The procedure requires greater experience.
3. Removal of excess adhesive can be more difficult and more time consuming with some techniques.
4. The risk for adhesive deficiencies under the brackets is greater.
5. The risk for adhesive leakage to interproximal gingival areas can disturb oral hygiene procedures.
6. The failure rates with some methods seem to be slightly higher.

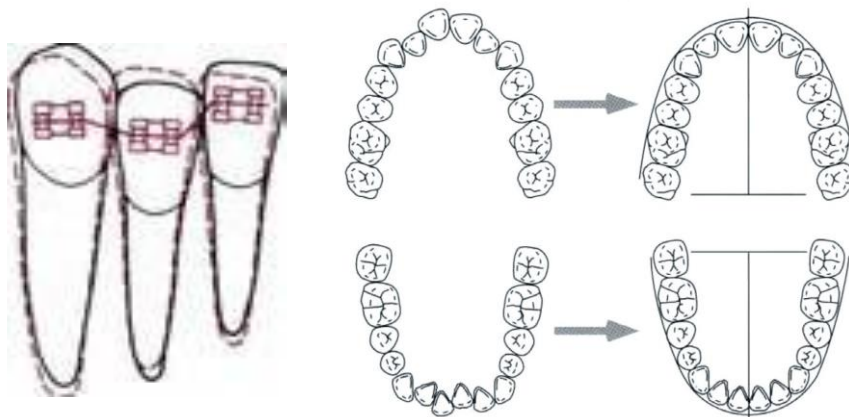


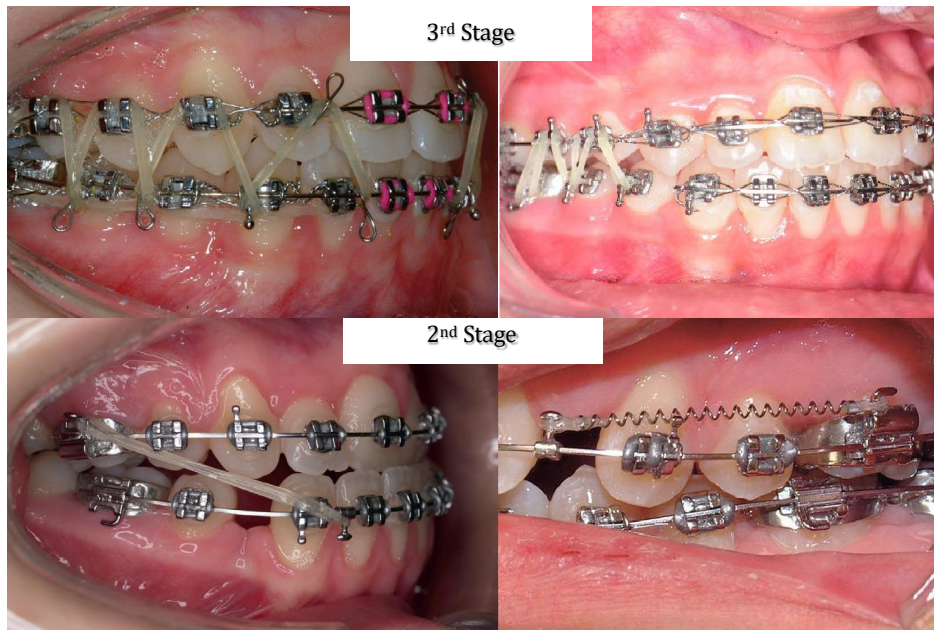
The comprehensive orthodontic treatment with fixed appliance

1st stage: Alignment and leveling: Eliminating rotations, bringing the teeth to one line buccolingually and one level occlusogingivally following the archwire shape. It facilitates future treatment stages.

2nd stage: Correction of molar relationship and space closure (e.g. extraction space).

3rd stage: Finishing (settling): optimizing occlusal relationship between upper and lower dental arches.





Visit frequency

Following insertion, the patient must be seen regularly to evaluate the progress of treatment and make the necessary adjustments. There is no agreement or evidence to support a specific timeframe. Most orthodontists see their patients every 4 weeks, others see them every 6, 8, or 10 weeks intervals.

These visits are also necessary to avoid or prevent problems during orthodontic treatment. The problems encountered are caries and decalcification, debonded brackets, loose bands and soft tissue problems.

Treatment duration

There is no specific way to estimate duration of treatment. It usually takes 12-30 months, depending on the complexity of the case. Missing appointments will lengthen treatment duration.

Pain with fixed orthodontic appliances

Some pain may be felt in the teeth for a period of 3-5 days following each adjustment visit, especially during eating. The pain level is usually mild to moderate. Analgesics like ibuprofen or paracetamol may be used to decrease pain.

Some pain may be felt with salty or sour food because of ulcers. Ulcers often develop as a result of rubbing the cheeks and lips with the appliance during



4th Year Lec. No. 7

normal function. This usually lasts for few days after insertion, and can be reduced by using orthodontic wax.

Trauma to the cheek may happen because of a protruding wire; it is better to go to the orthodontist to fix it, meanwhile orthodontic wax can be used to reduce irritation.