

Provisional Restoration (Temporary Restoration)

A crown restoration that is used in fixed prosthodontics during the interim between tooth preparation and final placement of the definitive crown restoration.

Objectives of provisional restoration:

1. To protect the tooth from pain stimuli as a result of thermal, and chemical.
2. To prevent sensitivity and further irritation to the pulp.
3. To prevent movement of the prepared, adjacent, and opposing teeth. i.e., to prevent super-eruption and drifting.
4. To protect the gingival tissue from irritation and food impaction.
5. To provide esthetic, phonetic, and function.
6. To prevent tooth fracture.

Types of provisional restoration:

- I. Preformed temporary crowns.
- II. Customized temporary restorations.
- III. Laboratory-made temporary restorations.

I. Preformed temporary crowns:

consist of a shell of plastic or metal that could be cemented directly on the prepared tooth following adjustment, or after its lining with a resin material. They could be used for single or multiple preparations.

Types of preformed temporary crowns:

- A. Metal temporary crowns.
- B. Plastic temporary crowns
- C. Celluloid crown forms.

A. Metal temporary crowns:

Metal temporary crowns are mainly indicated for use in the posterior teeth. They are made of stainless steel, nickel-chromium, or aluminum. The most commonly used type is aluminum temporary crowns.

Clinical procedure:

1. Select the proper size and shape of the temporary crown according to the prepared tooth.
2. Trim the cervical margin of the temporary crown using a scissor to conform to the gingival margin of the preparation (finishing line) and to accommodate the vertical height of the prepared tooth.
3. Seat the temporary crown on the prepared tooth and ask the patient to bite on it. Check the margins and the occlusion (centric and eccentric).
4. Smooth the margins with a stone bur.
5. Cement the temporary crown on the prepared tooth using zinc oxide-eugenol cement.

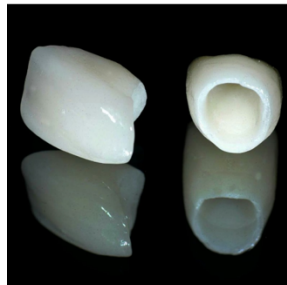

B. Plastic temporary crowns:

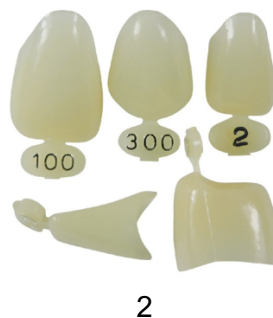Used mostly for the anterior teeth. The clinical procedure for the use of plastic temporary crown is nearly the same as that for metal temporary crown.

Types of plastic temporary crowns:

1. Acrylic temporary crowns: These are made from acrylic resin and are available in different sizes and colors, used for the anterior teeth.



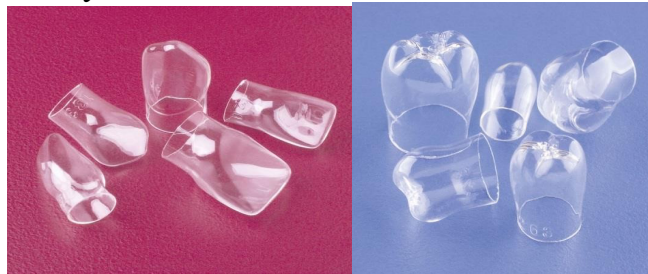
2. Polycarbonate temporary crowns: these are made from polycarbonate plastic combined with micro glass fibers. Used for the anterior and posterior teeth.



In case we need to improve the fitness of the temporary crown or if there is no size which approximately fits the prepared tooth, we can reline the temporary crown with a resin material to improve its fitness after the selection of the most suitable size and shade of the temporary crown and cutting its margin according to the finishing line of the prepared tooth. The procedure of relining could be done either directly on the prepared tooth in a manner similar to that of celluloid temporary crown or could be done indirectly on a study cast of the prepared tooth.

C. Celluloid crown forms:

Used for the anterior teeth, but can be used for the posterior teeth also. They are made from a very thin translucent layer. They act as a mold for the construction of the temporary crown. They come in different sizes.



Clinical procedure:

1. Coat the prepared tooth with Vaseline to facilitate removal of the temporary crown.
 2. Select the proper size and shape of the celluloid crown.
 3. Make two holes in the corners of the temporary crown to provide an escape way for the excess material.
 4. Cut the gingival margin of the crown to accommodate that of the prepared tooth.
 5. Fill the celluloid crown with a provisional crown material (Bis-acryl composite resin or composite resin) of the same shade of the tooth and seat it over the prepared tooth until setting.
- If Bis-acryl composite resin is used as a provisional material, the celluloid crown should be removed at its semi-plastic stage so that the polymerization reaction of the acrylic resin will occur outside the mouth to prevent pulpal irritation since the polymerization reaction of the acrylic resin is exothermic.
6. Take the crown out and remove the excess material. Then place it again on the prepared tooth and check the occlusion, contact with the adjacent teeth, fitness, and extension.

1. Customized temporary crown and bridge:

The fabrication of customized temporary crowns requires the construction of a mold of the patient's teeth before their preparation. This may be obtained from any type of elastic impression material, into which resin polymer material (Bis-acryl or composite) is placed and the mold is held either directly on the prepared tooth or indirectly against a cast of the patient's teeth.

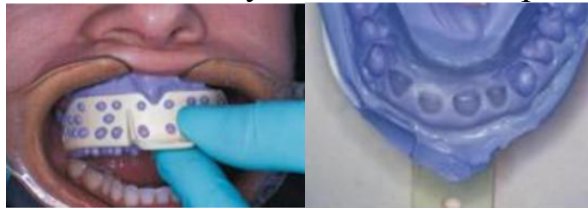Methods of construction of customized temporary restorations:

Impression method (over-impression method):

- Indirect impression method (indirect chairside technique).
- Direct impression method (direct chairside technique).

Clinical procedure of the indirect impression method:

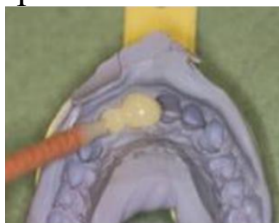1. A preoperative over-impression with silicone impression material is made from the patient's teeth and carefully stored until completing tooth preparation.



2. After completing the preparation of teeth, another alginate impression was then taken and poured with plaster or stone. After setting of the plaster or stone, the cast is separated from the impression.

3. Coat the prepared tooth on the cast with a separating medium (such as petroleum jelly).

4. Mix tooth colored resin according to the manufacturer's instructions and place the mixed resin in the over-impression at the area of tooth preparation only.



5. Seat the cast into the over-impression in an upright position and maintain constant pressure until the resin sets completely. It is important to note that the cast is correctly seated in the over impression.

6. After complete polymerization of the resin, separate the cast from the over-impression. The formed crown is then removed from the prepared tooth in the cast.

7. Trim any excess material from the formed crown. Then the crown is seated on the prepared tooth inside the patient's mouth. Check the occlusion and remove any premature contact in centric and eccentric occlusion.

8. Cement the crown on the prepared tooth using zinc oxide- eugenol cement.

Clinical procedure of the direct impression method:

The clinical procedure of the direct impression method is the same as that of the indirect method except that it is done directly inside the patient's mouth. In this method, we need a preoperative over-impression but there is no need to have a study cast. Prepare the tooth, mix the resin, place it in the over-impression in the area of tooth preparation, and seat the over-impression inside the patient's mouth. Then follow the same steps that are used in the indirect method.

Advantages of the indirect method over the direct method:

1. There is no direct contact of the free monomer of the resin with the prepared tooth or gingival tissue which might cause tissue irritation or allergic reaction.
2. The indirect method avoids subjecting the prepared tooth to the heat of polymerization of the resin.

Temporary restoration for a tooth prepared to receive Post crown:

It is often difficult to fabricate a temporary crown for a tooth that has been prepared to receive a post crown because there is so little tooth structure supra-gingivally that cannot give support to the temporary crown, so in such a case we need intracanal retentive means to give retention to the temporary crown.

A piece of stainless-steel wire could be used as an intracanal retentive means. The wire should be adapted to the prepared root canal and should extend coronally at least 4 mm. i.e., 4 mm of the wire should extend supra-gingivally outside the canal prior to the construction of the temporary crown. After that, a temporary crown could be constructed and the stainless-steel wire will be part of the temporary crown.

Cementation of the temporary restoration:

Zinc oxide-eugenol cement is the most commonly used cement for temporary crowns. This cement promotes healing and allows easy removal of the temporary restoration.