



Methods of Imaging of Hepatobiliary System

2 nd stage

LECTUER 1-2

Ahmed Salman Jassim

MSc Radiographic Imaging

2023

Methods of imaging of hepatobiliary system

1. Plain film
2. Ultrasound (US):
 - (a) Transabdominal
 - (b) Endoscopic
 - (c) Intraoperative
3. Computed tomography (CT), including:
 - (a) Routine 'staging' (portal venous phase) CT
 - (b) Triple phase 'characterization' CT
 - (c) CT cholangiography
4. Magnetic resonance imaging (MRI)
5. Endoscopic retrograde cholangiopancreatography (ERCP)
6. Percutaneous transhepatic cholangiography (PTC)
7. Operative cholangiography
8. Postoperative (T-tube) cholangiography
9. Angiography—diagnostic and interventional
10. Radionuclide imaging:
 - (a) Static, with colloid
 - (b) Dynamic, with iminodiacetic acid derivatives.

METHODS OF IMAGING THE PANCREAS

1. Plain abdominal films
2. US:
 - (a) Transabdominal
 - (b) Intraoperative
 - (c) Endoscopic
3. CT
4. MRI
5. ERCP
6. Arteriography:
 - (a) Coeliac axis
 - (b) Superior mesenteric artery

PLAIN FILMS

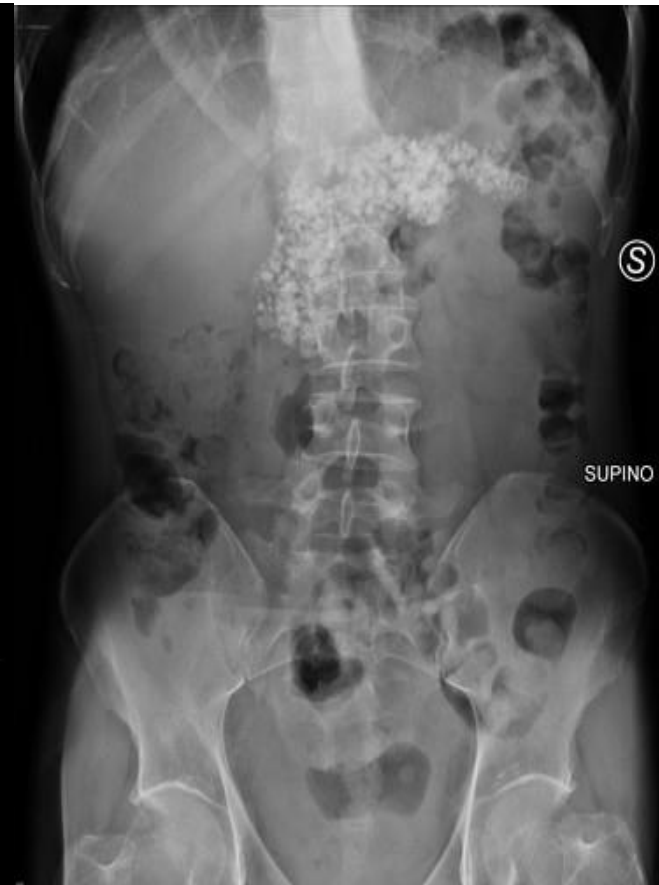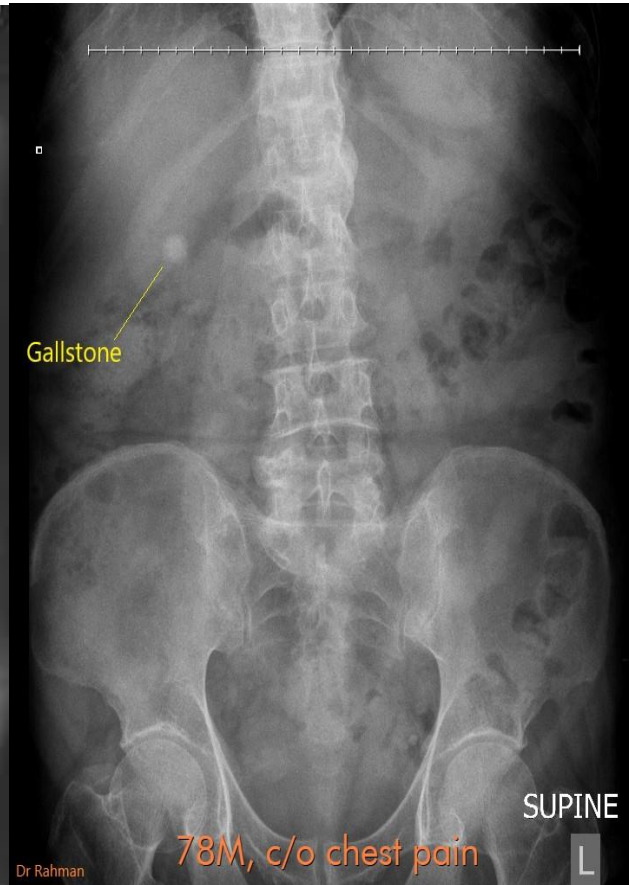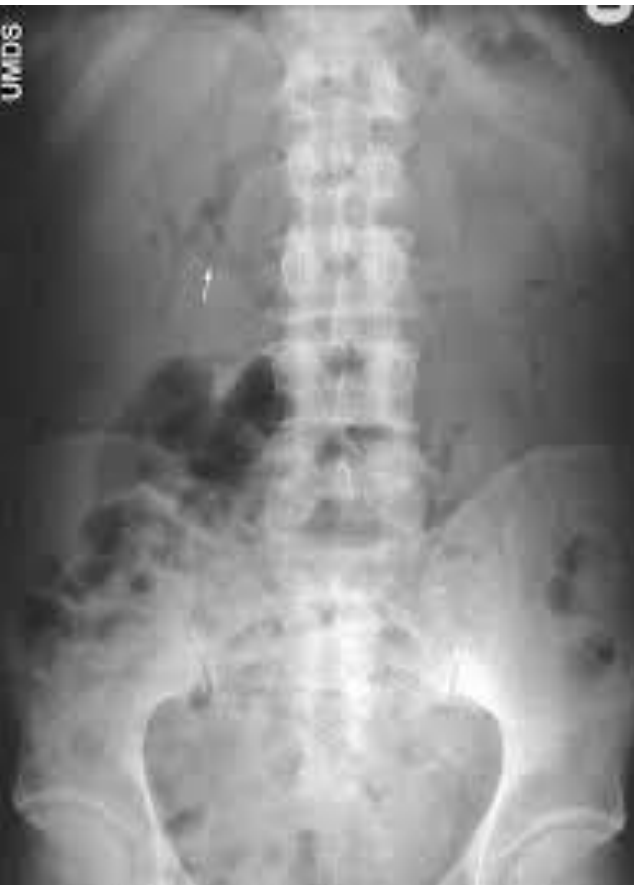Not a routine indication.¹ May incidentally demonstrate air within the biliary tree or portal venous system, opaque calculi or pancreatic calcification .

PLAIN FILMS

air within the biliary tree
or portal venous system

opaque calculi

pancreatic calcification

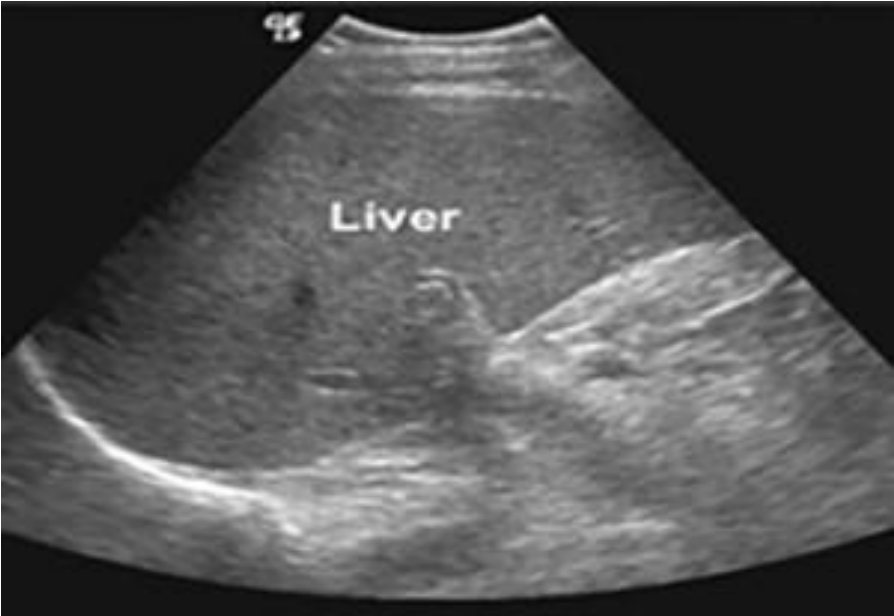
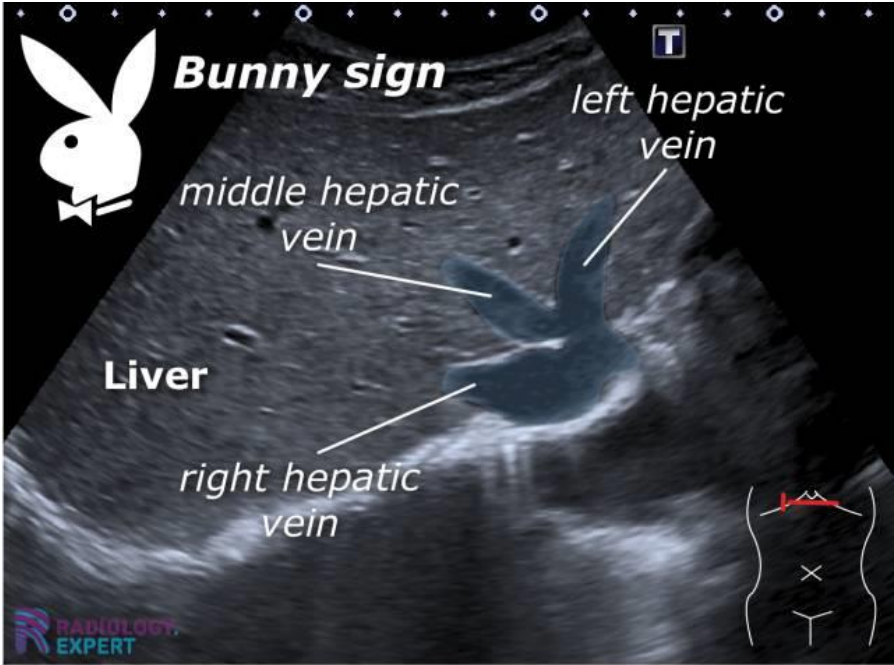
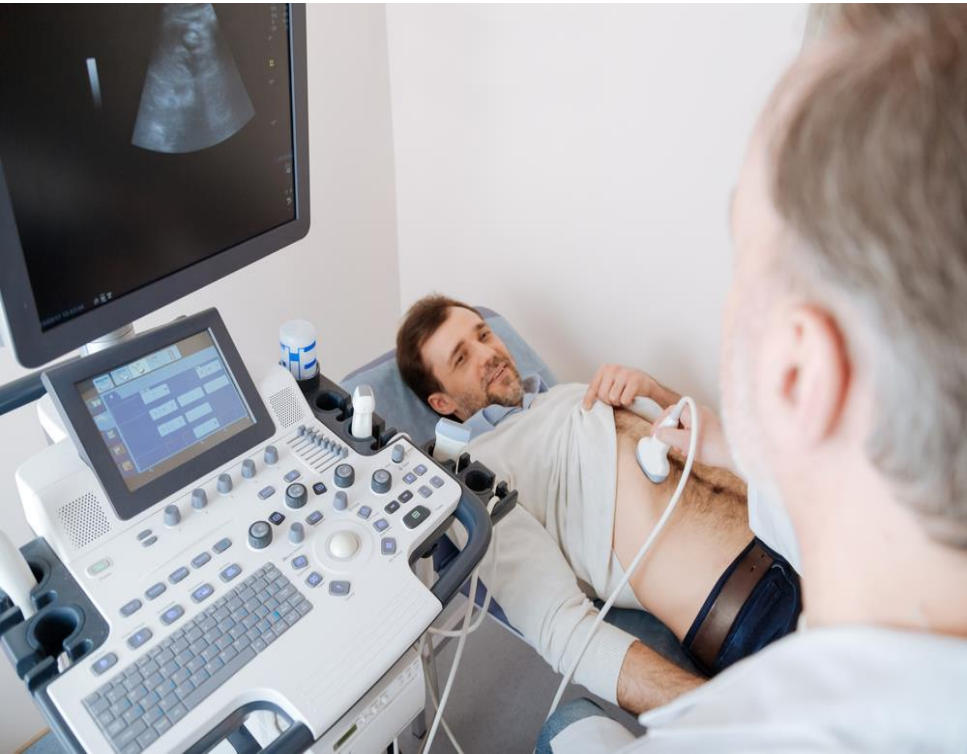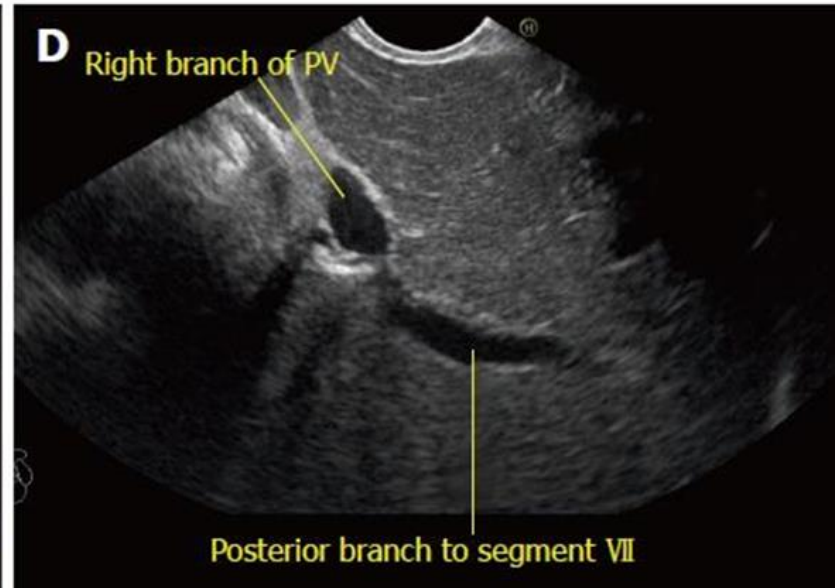
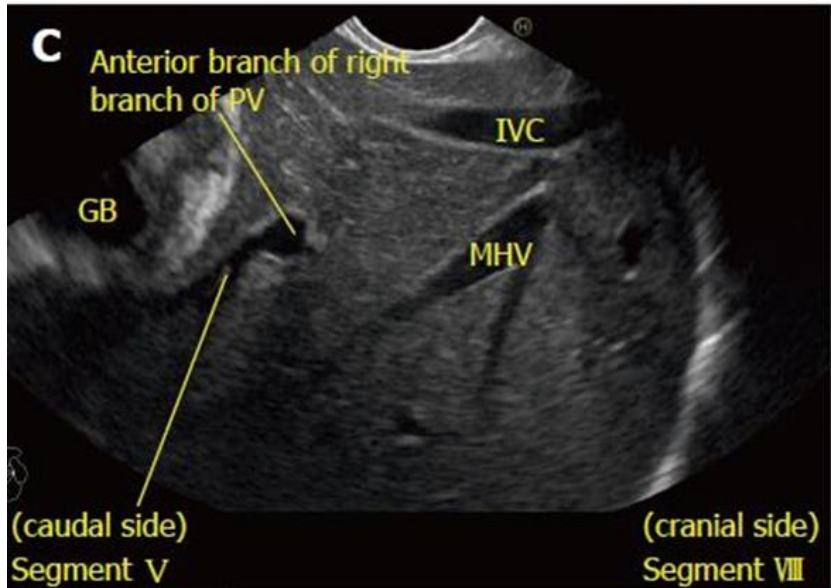
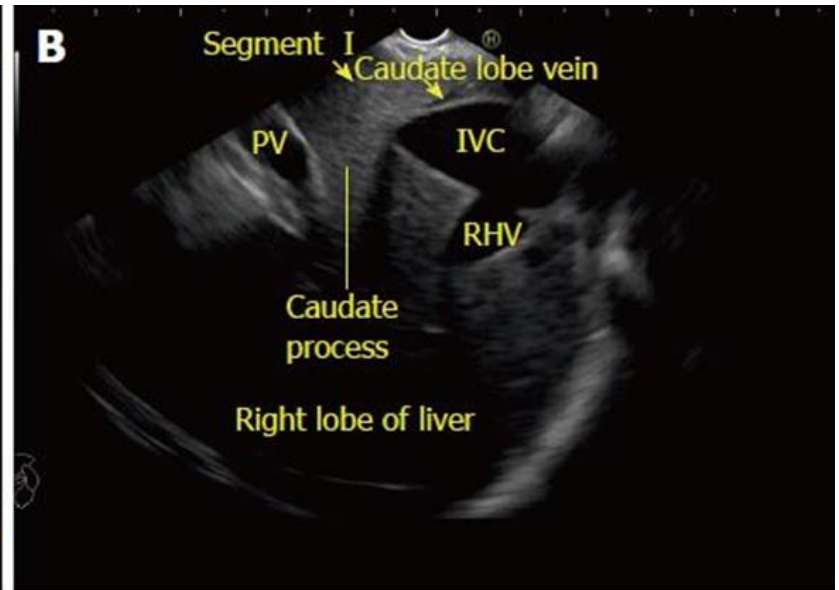
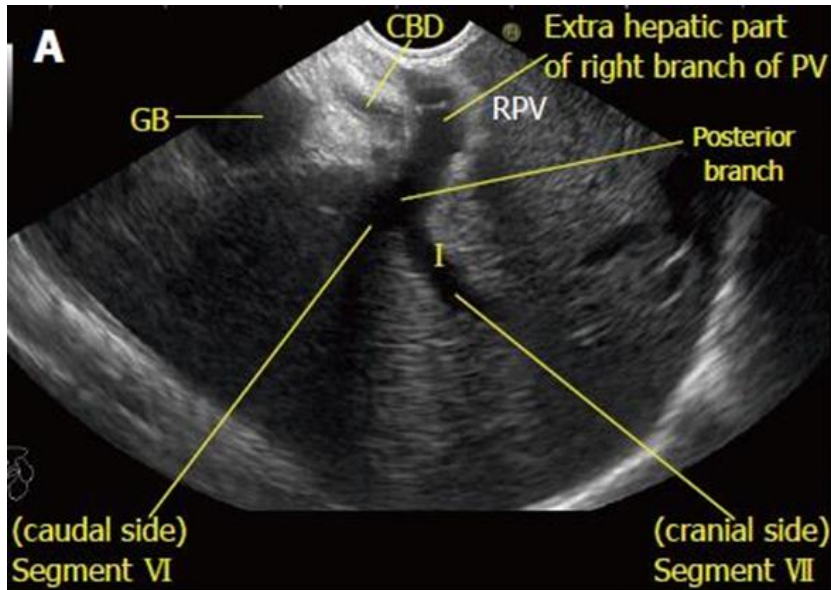
ULTRASOUND OF THE LIVER

Indications

1. Suspected focal or diffuse liver lesion
2. Jaundice
3. Abnormal liver function tests
4. Right upper-quadrant pain or mass
5. Hepatomegaly
6. Suspected portal hypertension
7. Staging known extrahepatic malignancy, superseded by CT
8. Pyrexia of unknown origin, now superseded by CT for patients over 30 years old
9. To provide real-time image guidance for the safe placement of needles for biopsy
10. Assessment of portal vein, hepatic artery or hepatic veins
11. Assessment of patients with surgical shunts or transjugular intrahepatic portosystemic shunt (TIPS) procedures
12. Follow-up after surgical resection or liver transplant

ULTRASOUND OF THE LIVER





- **Contraindications:**

None.

- **Patient Preparation:**

- Fasting or restriction to clear fluids only required if the gallbladder is also to be studied.

- **Equipment:**

- 3–5-MHz transducer and contact gel. Selection of the appropriate preset protocol and positioning of focal zone will depend upon the type of machine, manufacturer and patient habitus.

Technique

1. Patient supine
 2. Time-gain compensation set to give uniform reflectivity throughout the right lobe of the liver
 3. Suspended inspiration
 4. Longitudinal scans from epigastrium or left subcostal region across to right subcostal region. The transducer should be angled cephalad to include the whole of the left and right lobes.
 5. Transverse scans, subcostally, to visualize the whole liver
 6. If visualization is incomplete, due to a small or high-positioned liver, then additional right intercostal, longitudinal, transverse Liver, biliary tract and pancreas 95 4 and oblique scans may be useful. Suspended respiration without deep inspiration may allow useful intercostal scanning. In patients who are unable to hold their breath, real-time scanning during quiet respiration is often adequate. Upright or left lateral decubitus positions are alternatives if visualization is still incomplete
 7. Contrast-enhanced ultrasound of the liver uses microbubble agents to enable the contrast enhancement pattern of focal liver lesions, analogous to contrast-enhanced CT or MRI, to be assessed and thus to characterize them. It requires specific software on the ultrasound machine. The lesion to be interrogated is identified on conventional B mode scanning, and then the scanner is switched to low mechanical index (to avoid bursting the bubbles too quickly) contrast-specific scanning mode, with a split screen to allow the contrast-enhanced image to be simultaneously viewed with the B mode image.
The images are recorded after bolus injection of the contrast agent flushed with saline.
- Advantages: Feasible even in the presence of impaired renal function
 - Disadvantages: Limited to single lesion visualization per pass

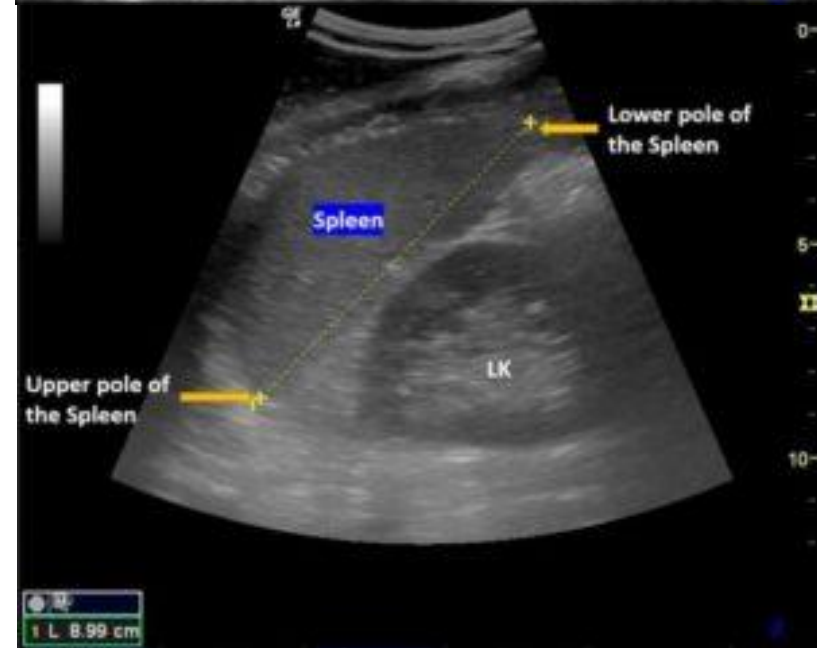
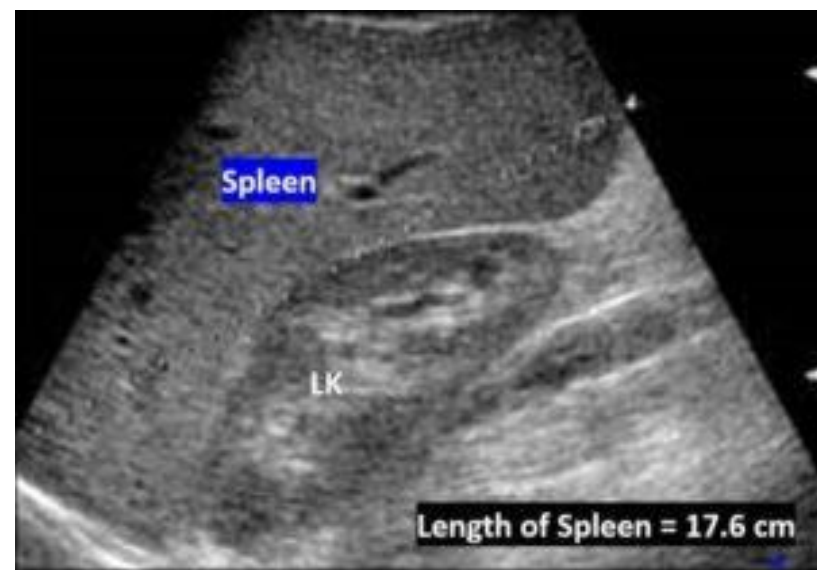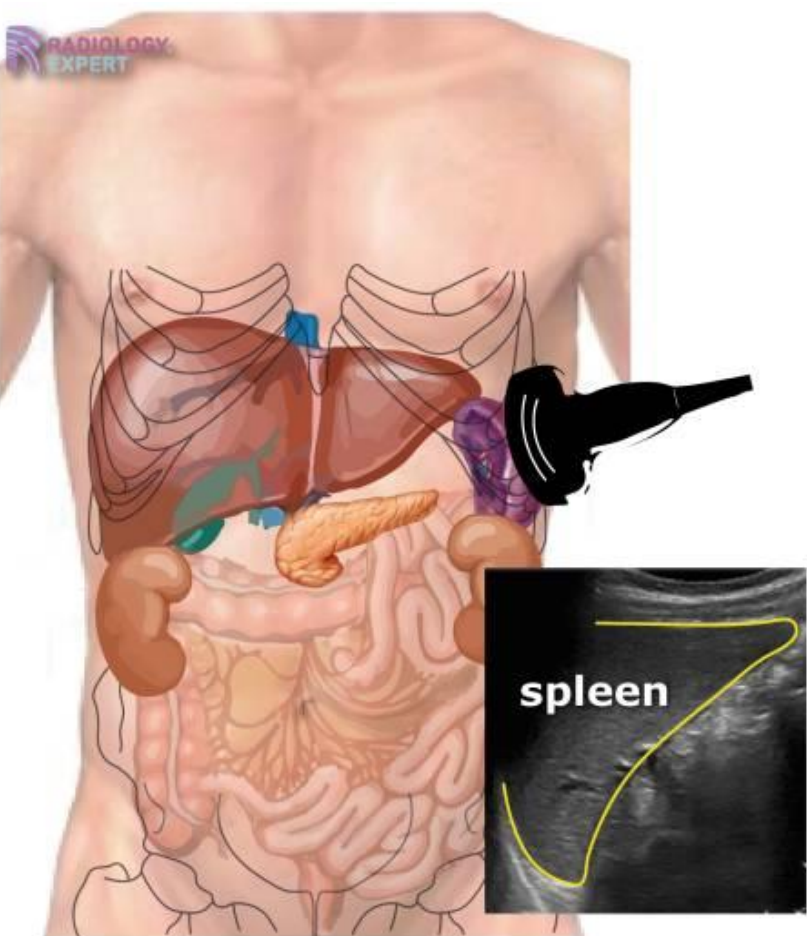
Additional Views

- **Hepatic veins:**
- These are best seen using a transverse intercostal or epigastric approach. During inspiration, in real time, these can be seen traversing the liver to enter the inferior vena cava (IVC). Hepatic vein walls do not have increased reflectivity in comparison to normal liver parenchyma. The normal hepatic vein waveform on Doppler is triphasic, reflecting right atrial pressures. Power Doppler may be useful to examine flow within the hepatic segment of the IVC since it is angle-independent.
- **Portal vein:**
- The longitudinal view of the portal vein is shown by an oblique subcostal or intercostal approach. Portal vein walls are of increased reflectivity in comparison to parenchyma. The normal portal vein blood flow is toward the liver. There is usually continuous flow, but the velocity may vary with respiration.

Additional Views

- **Hepatic artery :**
- This may be traced from the coeliac axis, which is recognized by the 'seagull' appearance of the origins of the common hepatic artery and splenic artery. There is normally forward flow throughout systole and diastole, with a sharp systolic peak.
- **Common bile duct:**
- See in the discussion in the 'Ultrasound of the Gallbladder and Biliary System' section.
- **Spleen:**
- The spleen size should be measured in all cases of suspected liver disease or portal hypertension. Ninety-five percent of normal adult spleens measure 12 cm or less in length, and less than 7 × 5 cm in thickness. The spleen size is commonly assessed by 'eyeballing' and measurement of the longest diameter.¹ In children, splenomegaly should be suspected if the spleen is more than 1.25 times the length of the adjacent kidney; normal ranges have also been tabulated according to age and sex.¹⁻³ .

US of Spleen

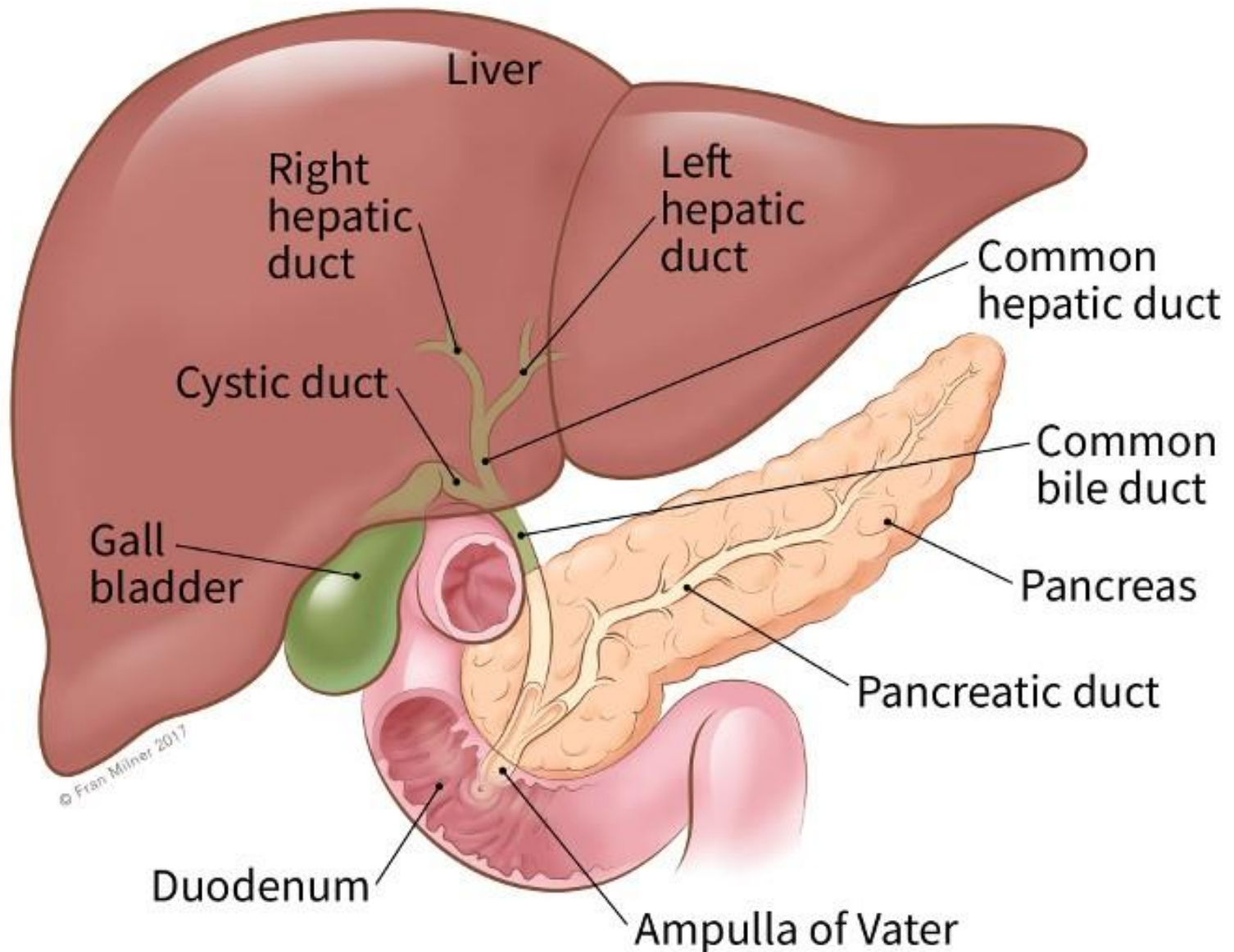


ULTRASOUND OF THE GALLBLADDER AND BILIARY SYSTEM

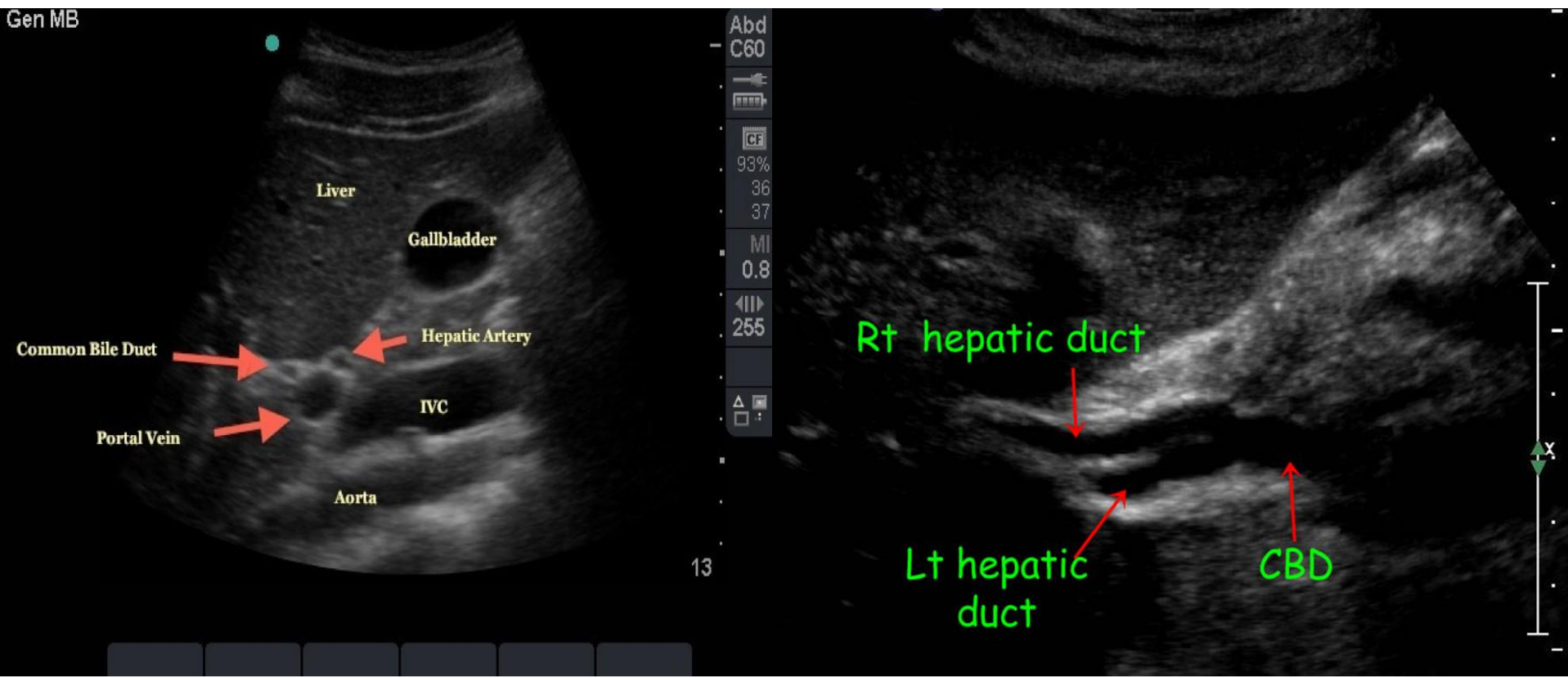
Indications:

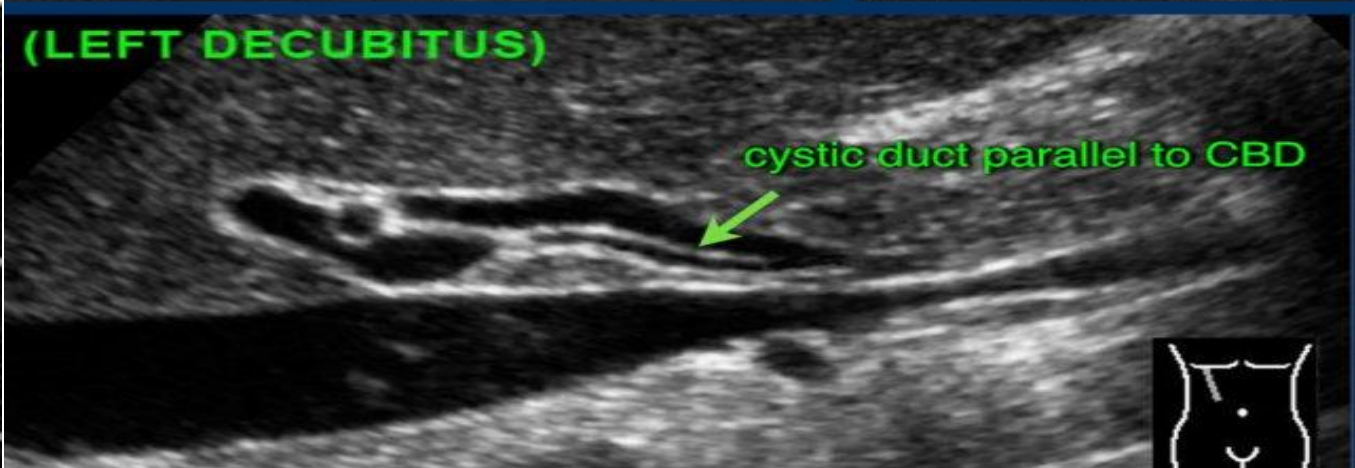
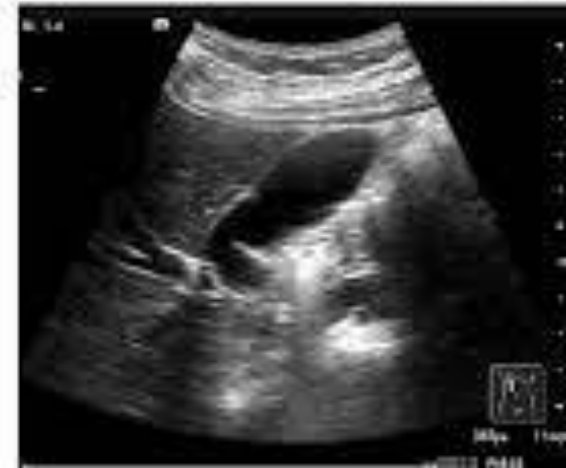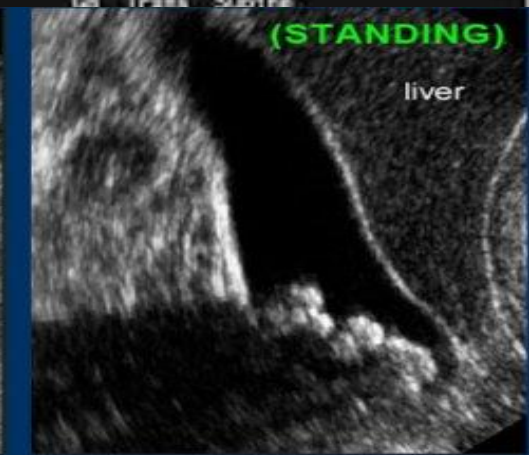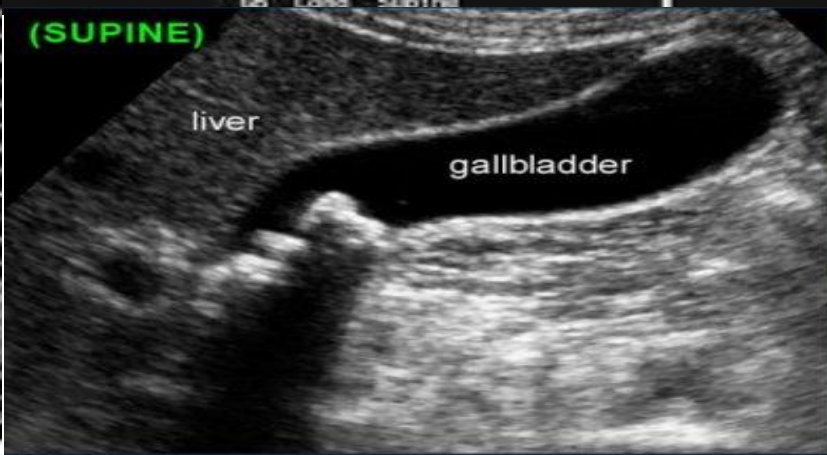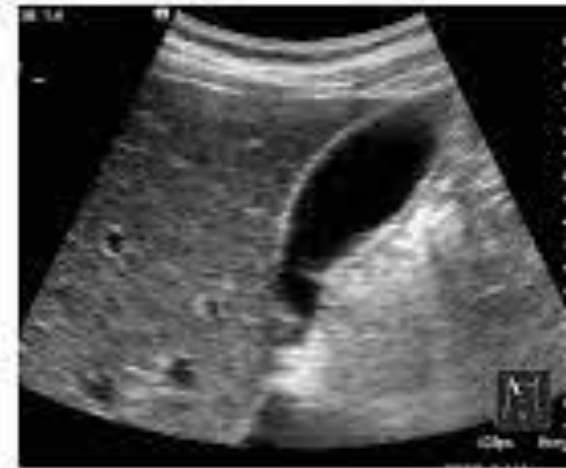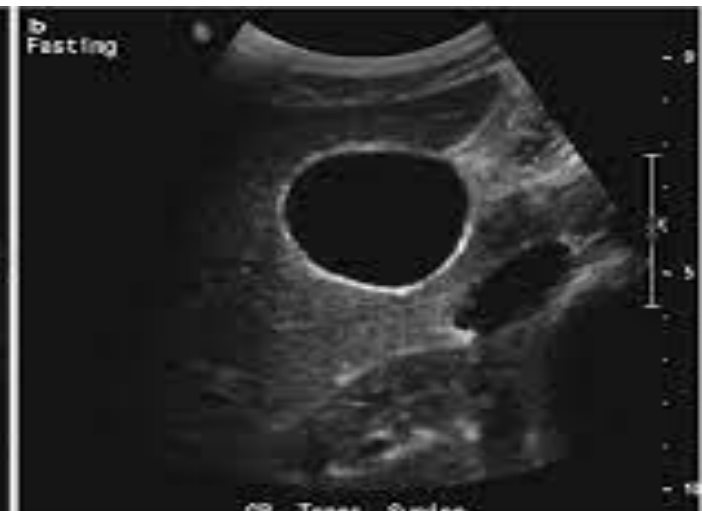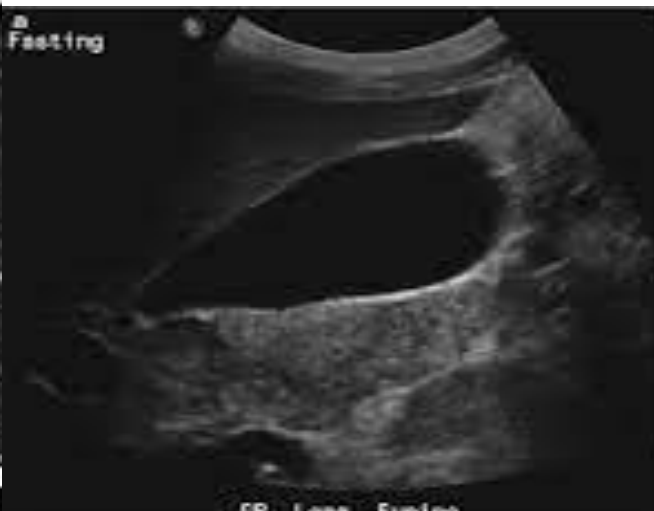
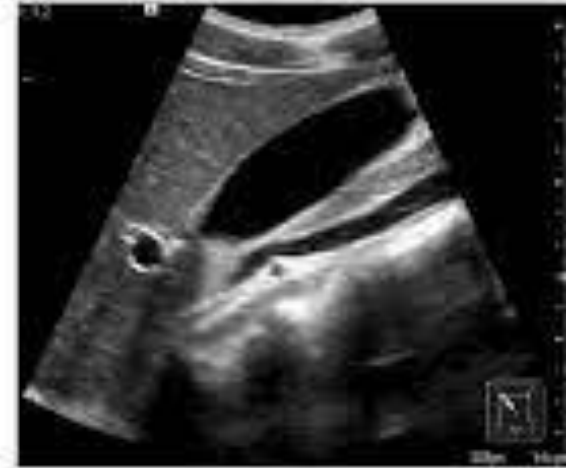1. Suspected gallstones .
2. Right upper quadrant pain.
3. Jaundice .
4. Fever of unknown origin .
5. Acute pancreatitis .
6. To assess gallbladder function .
7. Guided percutaneous procedures.

Hepatopiliary system



ULTRASOUND OF THE BILIARY SYSTEM





- **Contraindications:**
- None
- **Patient Preparation:**
- Fasting for at least 6 h, preferably overnight. Water is permitted.
- **Equipment:**
- 3–5-MHz transducer and contact gel. Selection of the appropriate preset protocol and positioning of focal zone will depend upon the type of machine, manufacturer and patient habitus. A stand off may be used for a very anterior-sited gallbladder.

Technique:

1. The patient is supine.
2. The gallbladder can be located by following the reflective main lobar fissure from the right portal vein to the gallbladder fossa.
3. Developmental anomalies are rare, but the gallbladder may be intrahepatic or on a long mesentery. In the absence of a previous cholecystectomy, the commonest cause for a nonvisualized gallbladder is when a gallbladder packed with stones is mistaken for a gas-filled bowel (usually duodenal) loop.
4. The gallbladder is scanned slowly along its long axis and transversely from the fundus to the neck, leading to the cystic duct.
5. The gallbladder should then be rescanned in the left lateral decubitus or erect positions, because stones may be missed if only supine scanning is performed.
6. Visualization of the neck and cystic ducts may be improved by head-down tilt. Note: The normal gallbladder wall is never more than 3-mm thick.

Additional Views

Assessment of gallbladder function :

1. Fasting gallbladder volume may be assessed by measuring longitudinal, transverse and antero-posterior (AP) diameters.
2. Normal gallbladder contraction reduces the volume by more than 25%, 30 min after a standard fatty meal. Somatostatin, calcitonin, indomethacin and nifedipine antagonize this contraction.

Intrahepatic bile ducts :

1. Left lobe—Transverse epigastric scan
2. Right lobe—Subcostal or intercostal longitudinal oblique

Normal intrahepatic ducts are visualized with modern scanners. Intrahepatic ducts are dilated if their diameter is more than 40% of the accompanying portal vein branch. There is normally acoustic enhancement posterior to dilated ducts but not portal veins. Dilated ducts have a beaded branching appearance.

Additional Views

Extrahepatic bile ducts :

1. The patient is supine or in a lateral position.
2. The upper common duct is demonstrated on a longitudinal oblique, subcostal or intercostal scan running anterior to the portal vein. The right hepatic artery is often seen crossing transversely between the two.
3. The common duct may be followed downward along its length through the head of the pancreas to the ampulla, and when visualized, transverse scans should also be performed to improve detection of intraduct stones. However, gas in the duodenum often impedes the view of the lower duct.

The segment of bile duct proximal to the junction with the cystic duct (the common hepatic duct) is 4 mm or less in a normal adult; 5 mm is borderline and 6 mm is considered dilated. The lower bile duct (common bile duct) is normally 6 mm or less. Distinction of the common hepatic duct from the common bile duct depends on identification of the junction with the cystic duct. This is usually not possible with US. Colour-flow Doppler enables quick distinction of bile duct from ectatic hepatic artery. In less than one-fifth of patients, the artery lies anterior to the bile duct.

Postcholecystectomy :

There is disagreement as to whether the normal common duct dilates after cholecystectomy. Symptomatic patients and those with abnormal liver function tests should have further investigations if the common duct measures more than 4 mm age 40, plus 1 mm for each decade over 40, and 1 mm for the postcholecystectomy state.

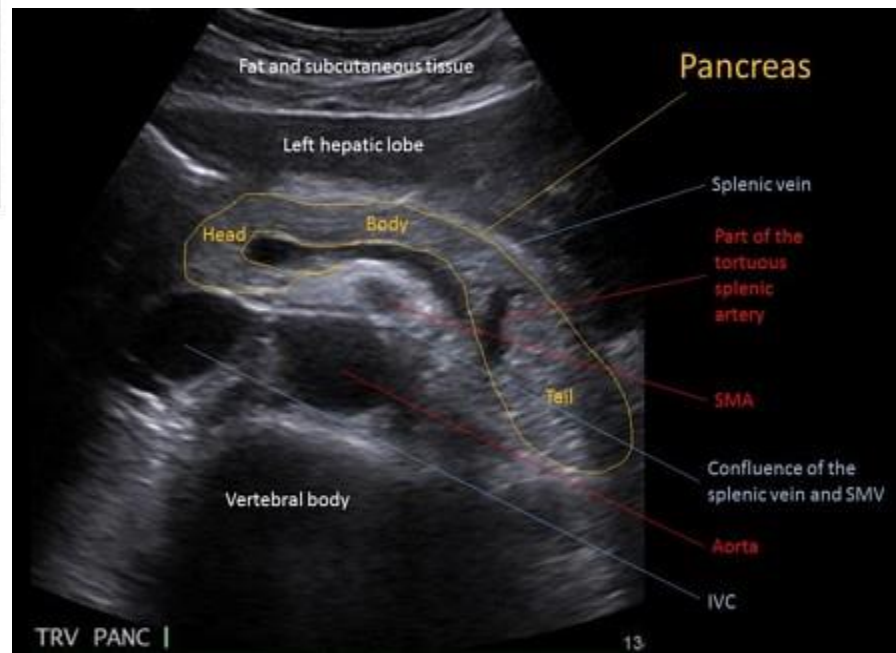
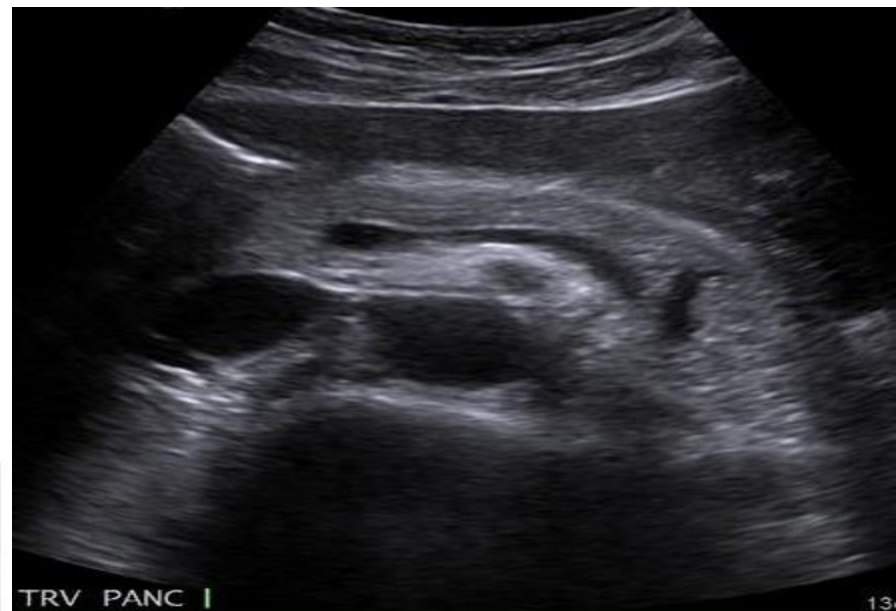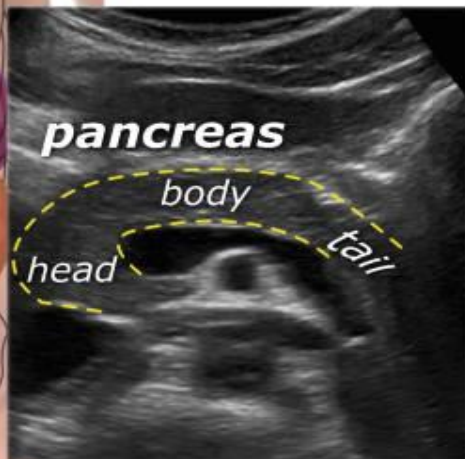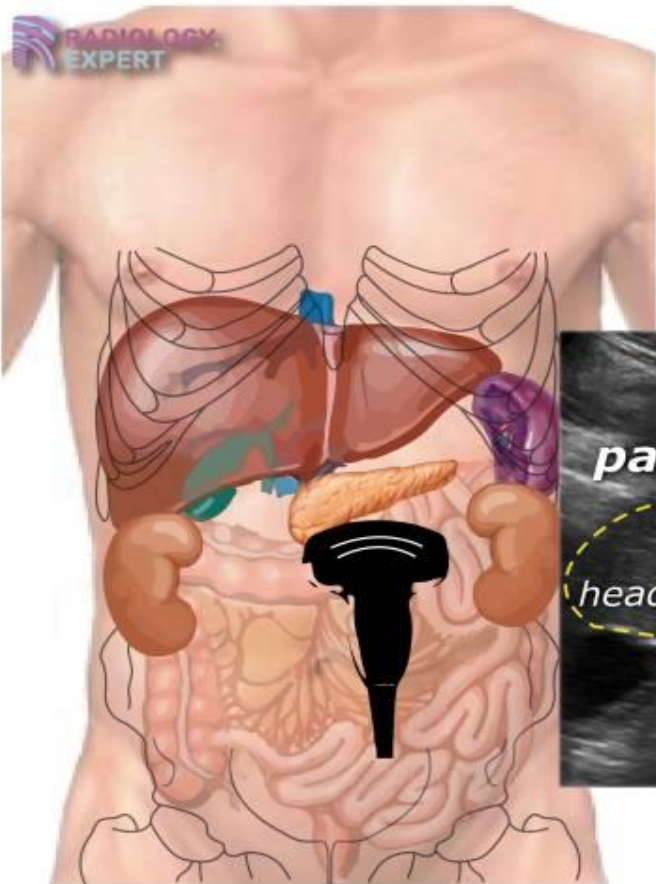
ULTRASOUND OF THE PANCREAS

Indications

1. Suspected pancreatic tumour
2. Pancreatitis or its complications
3. Epigastric mass
4. Epigastric pain
5. Jaundice
6. To facilitate guided biopsy and/or drainage

Contraindications

None.



Patient Preparation

Nil by mouth, preferably overnight.

Equipment

3–5-MHz transducer and contact gel. Selection of the appropriate preset protocol and positioning of focal zone will depend upon the type of machine, manufacturer and patient habitus. A stand off may be required in thin patients.

Technique

1. The patient is supine.
2. The body of the pancreas is located anterior to the splenic vein in a transverse epigastric scan.
3. The transducer is angled transversely and obliquely to visualize the head and tail.
4. The tail may be demonstrated from a left intercostal view using the spleen as an acoustic window.
5. Longitudinal epigastric scans may be useful.
6. The pancreatic parenchyma increases in reflectivity with age, being equal to liver reflectivity in young adults.
7. Gastric or colonic gas may prevent complete visualization. This may be overcome by left and right oblique decubitus scans or by scanning with the patient erect. Water may be drunk to improve the window through the stomach, and the scans repeated in all positions. One cup is usually sufficient. Degassed water is preferable. The pancreatic duct should not measure more than 3 mm in the head or 2 mm in the body.

Endoscopic US and intraoperative US are useful adjuncts to transabdominal US. EUS may be used to further characterize and biopsy pancreatic solid and cystic lesions. Intraoperative US is used to localize small lesions (e.g. islet cell tumours prior to resection).

THANK .

YOU