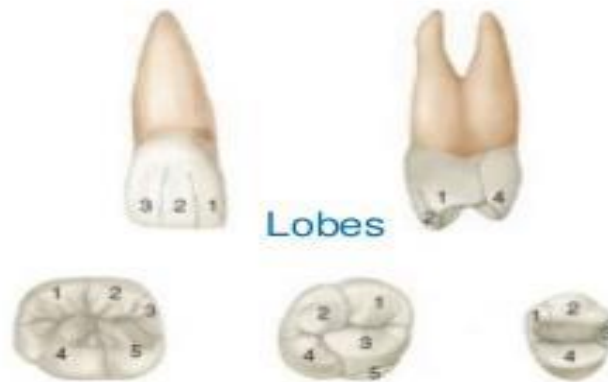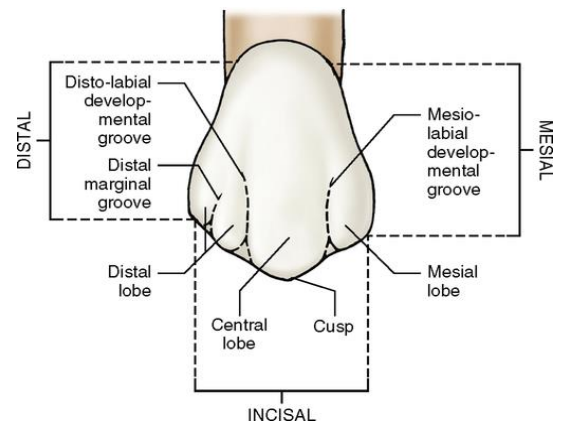
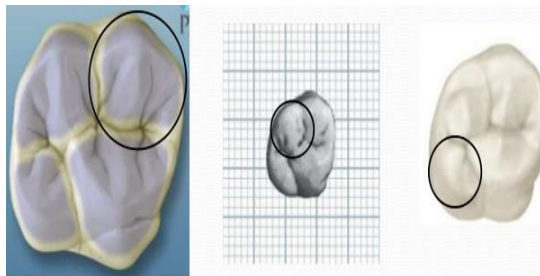


Anatomical landmarks (posterior teeth)

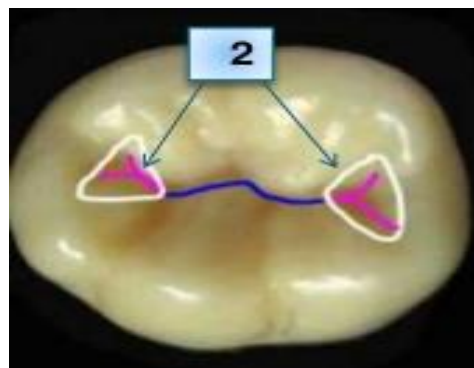
Lob: is a primary section of formation in the development of the crown.



Cusp: is an elevation on the crown that could be rounded or pointed it is present on the occlusal surface of premolars and molars and the incisal surface of canines, making up a divisional part of the occlusal surface

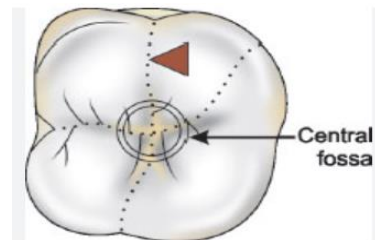


Fossa: an irregular, rounded depression or concavity found on the surface of a tooth. It is named according to its position.

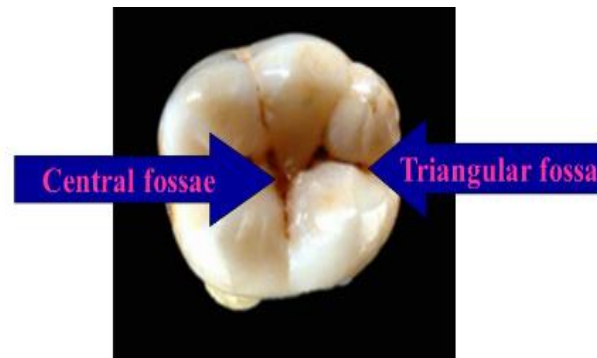
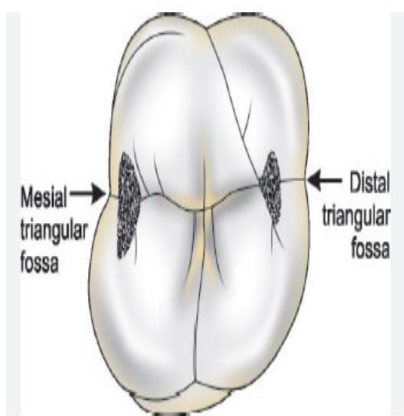


Types of fossae:

1. **Central fossa:** a depression found upon the occlusal surface of molars and formed by the converging of ridges terminating at a central point in the bottom of the depression where there is a junction of grooves.



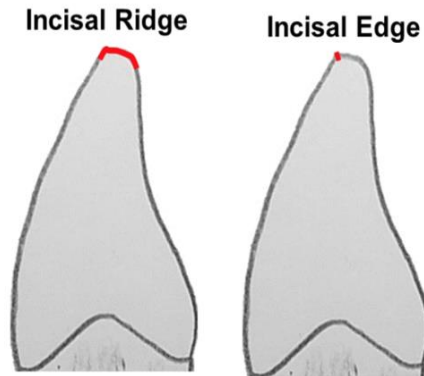
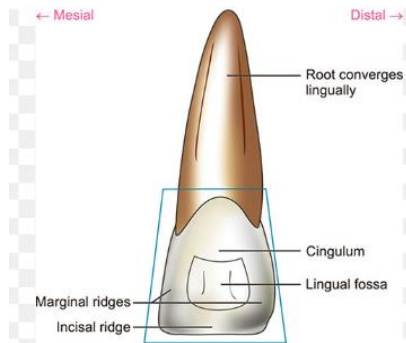
2. **Triangular fossa** is located on the occlusal surface near the (mesial, distal) marginal ridge of posterior teeth and the lingual surface of anterior teeth.



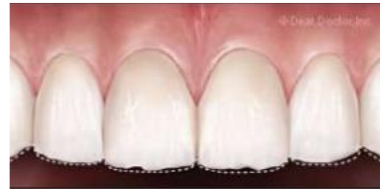Ridge is any liner, or elevation on the surface of a tooth and is named according to its location or form, (buccal ridge, incisal ridge, marginal ridge) so on.

Types of ridges

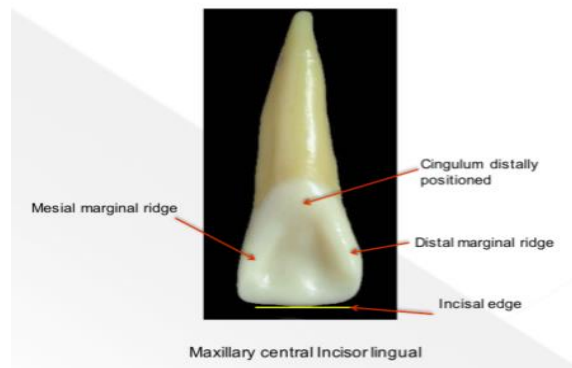
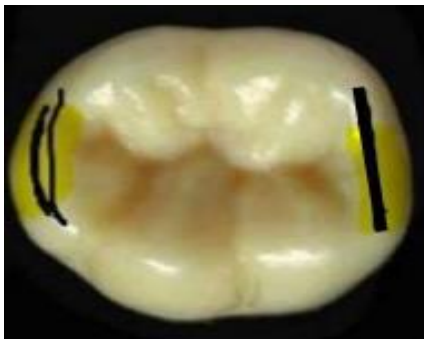1. ***Incisal ridge***: that portion of the crown that makes up the complete incisal surface.



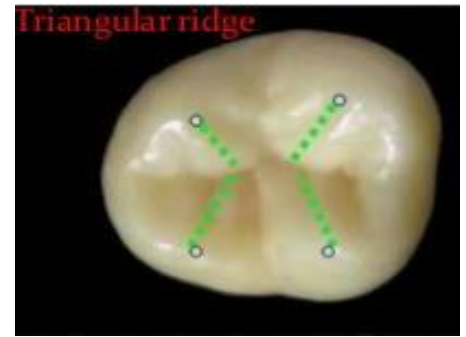
- ✚ ***Incisal edge***: is a term used to describe the edge derived from the union of two flat surfaces.



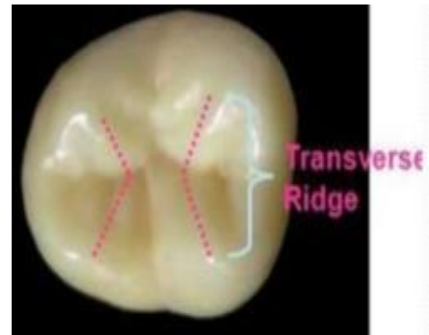
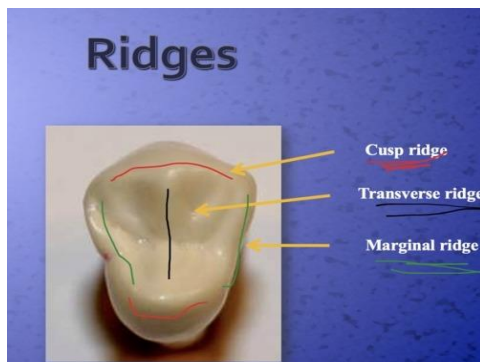
2. ***Marginal ridges***: are those rounded borders of the enamel that form the margins of the occlusal surface of the premolar and molar mesially and distally and on the lingual surface of anterior teeth.



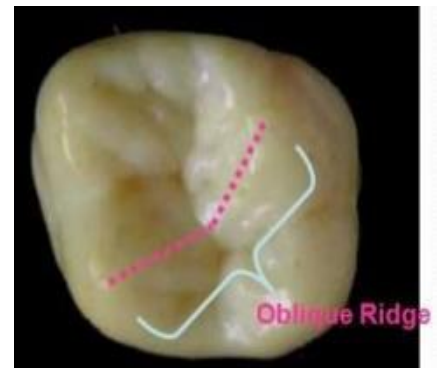3. **Triangular ridges:** are those ridges that descend from the tips of the cusps of the molar and premolar toward the central part of the occlusal surfaces.



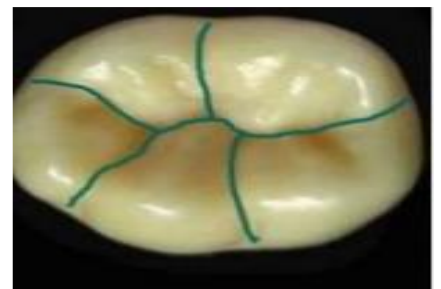
4. **A transverse ridge** is the union of two triangular ridges crossing transversally on the occlusal surface.



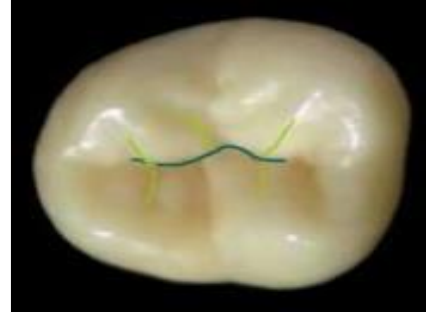5. **Oblique ridge:** the ridge which is the union of two triangular ridges crossing obliquely the occlusal surface of the maxillary molar.



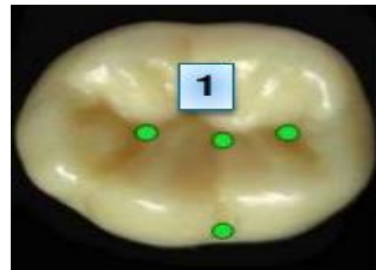
Developmental groove: a shallow groove or line on a tooth.



Supplemental groove: it lies distant shallow groove.

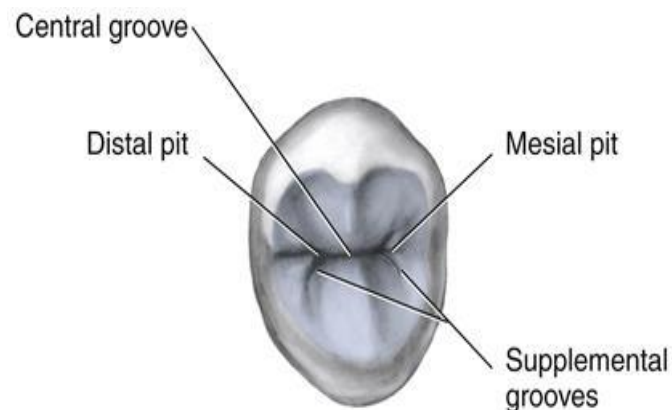


Pit: is a small pinpoint depression located at the junction of the groove.



Types of pits

1. **Central pit:** it is located in the center of the central fossa.
2. **Mesial pit:** is a pointed depression that is located distally to the mesial marginal ridge in the premolar and molars and it is the deepest point in the mesial triangular fossa.
3. **distal pit:** is located mesially to the distal marginal ridge in the distal triangular fossa where the developmental groove meets. In the premolars and molars.



THANK YOU