

Occlusal Concepts in complete denture

Attempts to understand occlusion have ranged from the mechanical, mathematical and geometrical analysis of tooth contact and jaw movement, to the biological and functional analyses based on the behaviour of natural dentitions under different environmental conditions.

Occlusion: is —the static relationship between the incising or masticatory surfaces of the maxillary or mandibular teeth or tooth analogues" (Occlusion=contact between teeth).

Articulation: It is defined as "static &dynamic contact relationship between maxillary &mandibular teeth as they move against each other during function".

Centric relation (CR): a maxilla mandibular relationship, independent of tooth contact, in which the condyles articulate with the thinnest avascular portion of their respective disc in the anterior-superior position against the posterior slopes of the articular eminences .It is a clinically useful, repeatable reference position.(bone-to bone relation).

Significance of centric relation:

1. It is a reproducible and recordable position, which can be repeatedly arrived at and thus serves as a reliable guide to develop centric occlusion in complete dentures.
2. Centric relation become starting point to plan and execute the occlusion.
3. Centric relation is related to terminal hinge axis. In centric relation, condyles exhibit pure rotation without any translation.
4. This position is more definite than the vertical relation and is independent of the presence or absence of teeth.
5. The final act of masticatory stroke ends in centric relation. It is a functional position.
6. It is a border position and the posterior limit of the envelope of motion

Centric occlusion: the occlusion of opposing teeth when the mandible is in centric relation; this may or may not coincide with the maximal intercuspal position. (tooth-to tooth relation).

Maximum intercuspation: The complete intercuspation of the opposing teeth, independent of condylar position.

Occlusal balance: a condition in which there are simultaneous contacts of opposing teeth or tooth analogues on both sides of the opposing dental arches during eccentric movements within the functional range.

Occlusal harmony : a condition in maximal intercuspal position and eccentric jaw relation in which there are no interceptive or deflective contacts of occluding surfaces.

Occlusal interference:

1. Any tooth contact that inhibits the remaining occluding surfaces from achieving stable and harmonious contacts;

2. Any undesirable occlusal contact Maximal intercuspal position the complete intercuspation of the opposing teeth, independent to condylar position.

Mandibular movement can be: opening closing, protrusive, and lateral in lateral it may be

- **Working side** is the side that the mandible move toward it in lateral excursion.
- **Nonworking side** is the side that the mandible move away from during lateral excursion.

Difference between Natural and Artificial Occlusion

Natural teeth	Artificial teeth
1. Fixed in bone.	1. Rest on residual ridge.
2. Supported by periodontal ligament.	2. Not fixed to soft tissue.
3. Tooth move into socket during mastication because of elasticity of ligament.	3. Denture move toward tissue because of resiliency of mucosa.
4. When teeth, move one side during mastication the other side is not affected.	4. When teeth meet on one side, the other side loses balance upsetting retention and stability.
5. When teeth move in socket, they produce stretching effect and exert tensile force.	5. Compression of soft tissue causes displacement of the supporting tissue.
6. Tensile force produces stimulation to under lying bone.	6. Compression causes pressure on mucosa of affecting vascular supply of bone.
7. Physiologic stimulation maintains good health of the bone.	7. Instability of denture causes loss of bone because of leverage.
8. To maintain the stimulus optimal occlusion of natural teeth is important.	8. To maintain the supporting tissue in good health ,planned occlusion is necessary

The concept of natural occlusion

1. Mutually protect occlusion (canine protection occlusion) (Organic Occlusion): the basic premise of canine protection occlusion is that:

A. On laterotrusive movements of the mandible, only the canines (possibly first premolars) contact & therefore protect the remaining dentition from adverse occlusal torsion forces on contacts to & from centric occlusion.

B. Furthermore, it is contended that canine protection occlusion is the ideal type of functional occlusion for the natural dentition & is the functional occlusion type toward which restorative & orthodontic treatments should be directed.

C. The advocates of canine protection occlusion argued that humans innately possess the long and dominant canine, they further argued that the canine is the strongest human tooth type & has the most sensitive proprioceptive fibers.

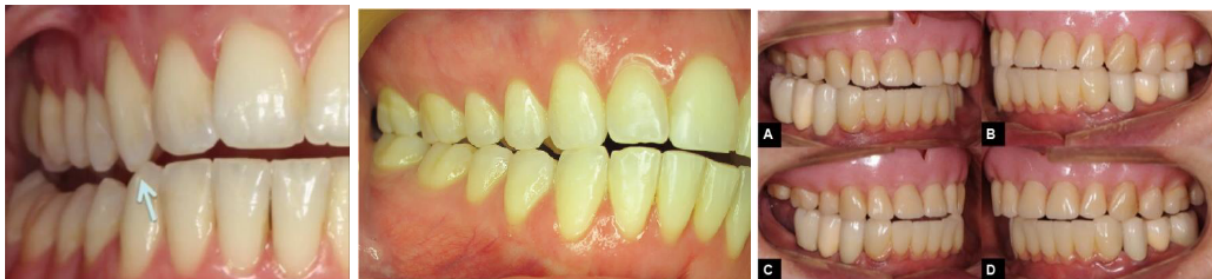* They therefore concluded that the canines are the best teeth to protect the occlusion from eccentric forces that occur on movements to and from centric occlusion.

2. Group function: exists when there are multiple contact relations between the maxillary & mandibular teeth in lateral movements on the working side where by simultaneous contact of several teeth acts as a group to distribute occlusal forces.

3. Balanced occlusion: this type of occlusion rarely found in natural dentition & considered as an occlusal interference:

a. The balancing contacts, for the most part, were contacts & not interferences.

b. Next, most balancing side contacts were on the distal sides of the posterior molars.



Principles of occlusion for complete dentures:

1. Complete denture patients must make initial and complete occlusal contact while in centric relation. This is called centric occlusion.
2. All anterior and posterior denture teeth inclines and surfaces must function as a “unit” during excursive movements.
3. Eliminate any prematurity preventing the movements described in principles 1 and/or 2.
4. Significant disclusion of posterior denture teeth when patient protrudes is contraindicated.
5. Anterior tooth contact is contraindicated in centric occlusion.

Objectives of occlusion in complete denture:

- Preservation of the remaining tissues
- Proper masticatory efficiency
- Enhancement of denture stability, retention and support
- Enhancement of phonetics and esthetics

Requirement of Complete Denture Occlusion

1. Stability of occlusion in centric relation.
2. Balanced for all eccentric contacts bilaterally for all eccentric mandibular movements.
3. Unlocking the cusp mesiodistally to allow for gradual but inevitable settling of the bases due to tissue deformation and bone resorption.
4. Control of horizontal forces by buccoligual cusp height reduction according to the residual ridge resistance and interridge space.
5. Functional lever balance by favorable tooth to ridge crest position.
6. Cutting and shearing efficiency of the occlusal surface (sharp cusps or ridges).
7. Anterior clearance of teeth during mastication. Minimum occlusal.
8. Contact between the upper and lower teeth to reduce pressure during function (lingualized occlusion).

Theories of occlusion:

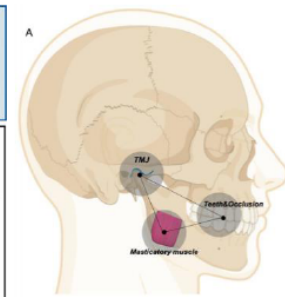
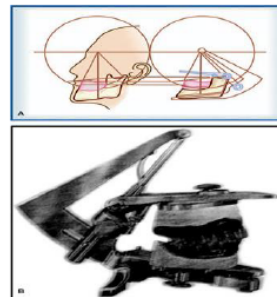
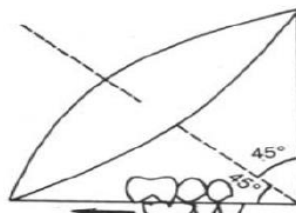
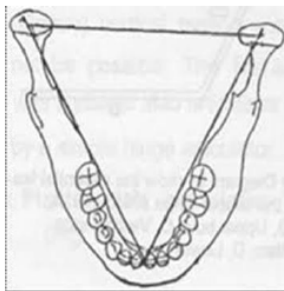
1. Bonwill theory (triangular theory): According to Bonwill theory of occlusion, the teeth move in relation to each other as guided by incisal and condylar guidances. The theory is also known as *theory of equilateral triangle* according to which, the distance between the condyles is equal to the distance between the condyle and the midpoint of the mandibular incisor (incisal point). An equilateral triangle is formed between the two condyles and the incisal point. Theoretically, the dimensions of equilateral triangle is 4 inches.

2. Conical theory: This theory proposed by RE Hall. The conical theory of occlusion claimed that, the lower teeth moves over the surface of upper teeth as over the surface of the cone, generating an angle of 45-degree with the central axis of the cone tipped 45- degree to the occlusal plane.

3. Spherical theory of Monson for occlusion: Monson proposed in 1920 that, the lower teeth moves over the surface of upper teeth as over the surface of sphere with a diameter of 8 inches (20 cm). The centre of sphere is located in the region of Glabella and the surfaces of sphere passes through the Glenoid fossa along the articular eminence.

According to this concept the anterioposterior (*spee curve*) and mediolateral (*Wilson curve*) incline of artificial teeth should be arranged in harmony with a spherical surface.

4. Organic concept of occlusion: the aim of this concept is to relate the occlusal surface of the teeth so that the teeth are in harmony with the muscles and joints during function. The muscle and joint determine the mandibular position of occlusion without any tooth guidance. The mandibular position of occlusion is terminal hinge position .In function the teeth should always be passive to the paths of mandibular movement. The condyle determines the direction of the ridges and grooves of the teeth and the mandibular movements determine other factors like cusp height, fossa, depth of the fissure, and concavity of the lingual surfaces.



Types of complete denture occlusion: (Balance, Monoplane and Lingualized occlusion).

I. Balance occlusion in complete dentures can be defined as stable simultaneous contact of the opposing upper and lower teeth in centric relation position and a continuous smooth bilateral gliding from this position to any eccentric position within the normal range of mandibular function.

In lateral excursion: (working side) *Include the canine s & the posterior teeth*

- Anterior teeth- the maxillary & mandibular anterior teeth contact on the working side.
- Posterior teeth- the buccal & lingual cusps of the maxillary & mandibular posterior teeth are in contact. If lingualized occlusion, the maxillary lingual cusp will be in contact with the mandibular lingual cusp.

In lateral excursion: (balancing side) *Include the canine s & the posterior teeth*

- Anterior teeth- the maxillary & mandibular anterior teeth contact on the balancing side.
- Posterior teeth- the lingual cusps of the maxillary teeth will be in contact with the buccal cusps of the mandibular teeth. With monoplane balanced occlusion, usually only the second molars are in contact or the balancing ramp.
- In many techniques, balancing contacts are necessary only on the second molars, to decrease the cuspal interference.

In protrusive excursion: (Incising units) *Include all the four incisors*

- The unit should not contact during mastication except during protrusion incising function.
- They should have as flat incisal guidance as possible considering esthetics and phonetics.
- They should have horizontal overlap to allow for base settling without interference.
- Posterior teeth, the distal slopes of upper cusps contact mesial slopes of the lower cusps.
- *Functional Incline (FI)* indicates contact cusp inclines in excursive movements so that the palatal maxillary anterior and labial mandibular anterior teeth slopes contact in protrusive.

Advantages of Balance occlusion:	Disadvantages of Balanced Occlusion
1. Distribution of load 2. Stability 3. Reduced trauma 4. Functional movement 5. Efficiency 6. Comfort	1. More occlusal disharmony during setting of teeth and difficult to correct by djustment. 2. Stable bases and precise jaw closer is required. 3. Increased horizontal forces due to the presence of incline plane of the cups. 4. Difficult to adapt in jaw relation other than class I.

Evaluation of the balanced occlusion

- ✓ During rest position teeth are not in contact.
- ✓ During chewing the food separating the teeth.
- ✓ So balanced articulation appears to be more important when no food in the mouth so it may be of value in nonfunctional activities when the patient is bruxing.

Significance of the balanced occlusion

Normal individual makes masticatory tooth contact only for 17.5 minutes in one day compared to 2–4 hrs of total tooth contact during other functions. So, for these 4hrs of tooth contact, balanced occlusion is important to main denture stability.

Prime gave the concept of “ENTER BOLUS EXIT BALANCE” which implies that introduction of food on one side will prevent the teeth of opposite side from contacting and hence occlusal balance is impossible during mastication.

However **Sheppard** (1964) later gave the concept of ENTER BOLUS ENTER BALANCE according to which even while chewing, the teeth cut through the bolus and come in contact with each other, for few fractions of a second. Hence the stability of the denture is maintained during various movements of mandible during chewing, reduce resorption of the residual ridge and soreness and improve oral comfort & well-being of the patient.

A balanced occlusion is required for two specific groups of patients, who with a steep, vertical overlap of the anterior denture teeth (steep incisal guidance) and patients who require opposing anatomic or semi-anatomic denture teeth for esthetics or other reasons.

Factors affecting the balanced occlusion (Laws of Articulation Hanau quint)

1. Condylar guidance
2. Incisal guidance
3. The occlusal plane
4. The compensatory curves
5. Cusp angulation

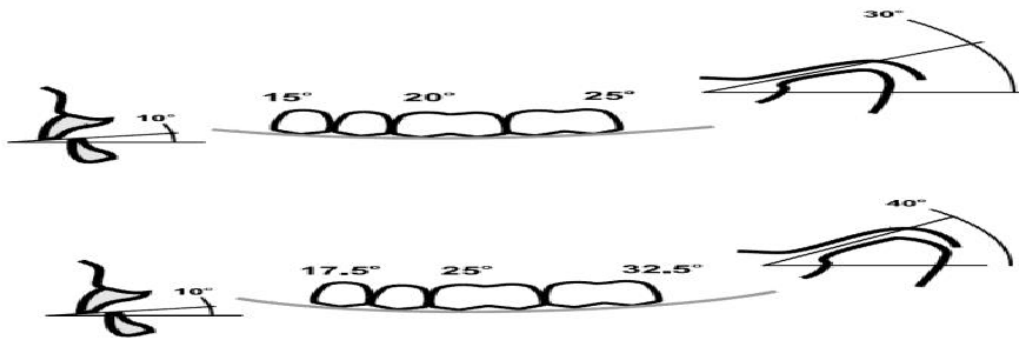
Inter relation between these factors may be described by Theilman's formula

$$\text{Balanced occlusion} = \frac{\text{condylar inclination} \times \text{Incisal guidance}}{\text{Occlusal plane} \times \text{compansatory curve} \times \text{cusps angulation}}$$

1. Condylar guidance: The angle formed by an imaginary horizontal line at the superior head of the condyle and the path that the condyle will pass through during function. It varies from individual to individual because of anatomical differences. The average is about 33° .

Components of condylar guidance:

- a. *Horizontal condylar guidance:* guides the forward movement for protrusive balance.
- b. *Lateral condylar guidance:* guides the sideward or lateral movement of the mandible.
 - The first factor of occlusion is the condylar guidance, this factor recorded from the patient. So it is fixed factor cannot be modified by the dentist.
 - The steeper the condylar guidance, the more separation of the teeth that will occur when the mandible moves in a protrusive or lateral movement (**Christensen's phenomenon**).
 - So compensation large space created posteriorly should be made by altering the other factors to obtain the desired balance.



2. Incisal guidance: the influence of the contacting surfaces of the mandibular and maxillary anterior teeth on mandibular movements. It is usually expressed in degrees of angulation from the horizontal by a line drawn in the sagittal plane between the incisal edges of the upper and lower incisor teeth when closed in centric occlusion.

- Incisal guidance:-the influences of the contacting surfaces of the guide pin and guide table on articulator movements.

Incisal guidance depends on the:

1. Over jet.
2. Over bite.



- This angle varies directly with the vertical overbite and inversely with the horizontal over jet.
- This angle is set to 10° in CD and not exceeding 20° .
- This angle determined by esthetic, phonetic, ridge relation, arch shape, inter-alveolar distance, this means it is under the control of the dentist.
- If the incisal guidance is steep, steep cusps or occlusal plane or steep compensatory curve is needed to balance occlusion.

3. Plane of occlusion: It is imaginary surface related anatomically to the cranium and theoretically touches the incisal edge of incisors and the tip of occluding surface of posterior teeth. Tilting of the plane $>10^\circ$ is not advisable.

- Maxillary occlusal plane should parallel to interpapillary line ,posteriorly usually parallel to the ala-tragus line.
- In the mandible established anteriorly by the cusp height of lower canine near the commissure of the mouth(corner) and posteriorly by the retromolar pad.

4. The compensating curve: the arc introduced in the construction of complete removable dental prostheses to compensate for the opening influences produced by the condylar and incisal guidance's during lateral and protrusive mandibular eccentric movements.

❖ Determined by inclination of posterior teeth and their vertical relationship to occlusal plane.

There are two types of curves:

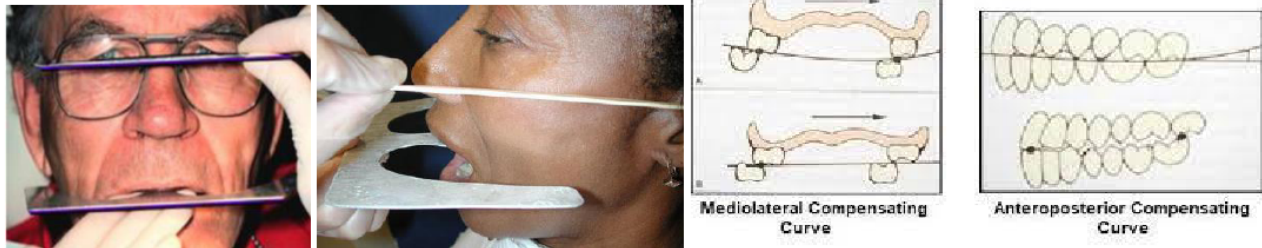
a. Anteroposterior compensating curve for Curve of spee: Anatomic curvature of the occlusal alignment of teeth beginning at the tip of lower canine and following the buccal cusps of the natural premolars and the molars, continuing to the anterior border of the ramus” as described by Graf Von Spee. When the patient moves his mandible forward, the posterior teeth set on this curve will continue to remain in contact. Thus avoiding disocclusion.

b. Lateral compensating curves for Monson curve: It is a curve extends mediolaterally from one side of the arch to the other side that touches to a segment of the sphere of 8” in diameter with its center at glabella”

5. Cuspal angulations or inclination of cusplless artificial teeth: It depends on several factors residual ridge, neuromuscular control, esthetics, etc) however, it's better to reduce the cuspal inclination to help reduce horizontal forces of occlusion.

Interaction of the five factor Of the four that he can control two of them (the incisal guidance and the plane of occlusion) can be altered only a slight amount because of esthetic and physiologic factors. The important working factors for the dentist to manipulate are the compensating curve and the inclinations of cusp on the occlusal surfaces of the teeth.

Angulation of functional inclines (AFI) must match incisal guidance and condylar inclination.

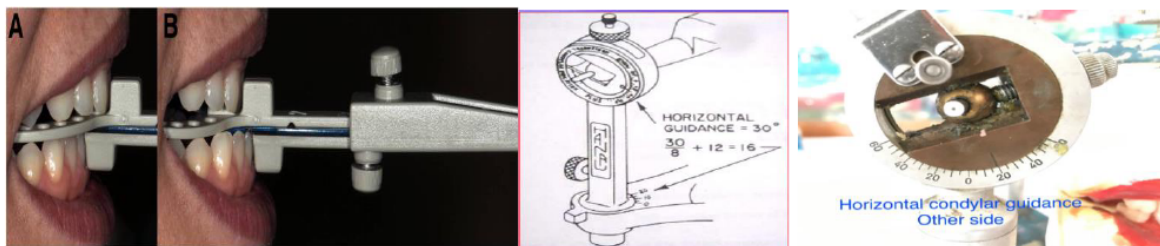


For the balanced occlusion, it is important to use adjustable articulator

How to record the condylar guidance?

After recording of jaw relation (orientation relation, vertical ,centric jaw relation)then a protrusive record should be made, in order to **set the condylar guidance on articulator according to the following steps:-**

1. Place V shape notch.
2. Allow the patient protrude aminimum of 5-6mm , but less than 12mm.
3. Place elastomeric registration material between occlusal rim while the patient close in protrude position.
4. After complete set of material, record base and registration removed, place on articulator.
5. On the articulator the condylar element release from hinge position, instrument protrude ,they record approximated. The condyle element are rotated untile there is maximum interdigitating of the registration and opposing occlusal rim.



II. Monoplane or occlusion (neutrocentric) :

- ♣ Flat occlusal plane set with non-anatomic teeth.
- ♣ The antero-posterior occlusal plan parallel to the denture foundation area.
- ♣ There is no vertical overlap of anterior teeth.
- ♣ Tooth Contact should occur only when mandible in centric relation. .
- ♣ Opposing artificial teeth should not contact when jaws in eccentric relation.
- ♣ In protrusion there is disclosure of posterior teeth as a result of arrangement in single plane. The patient is instructed not to incise the bolus.
- ♣ There is no curve of spee or curve of Wilson (compensating curves).
- ♣ When setting these teeth horizontal and lateral condylar guidances should be set at zero.

Indications:

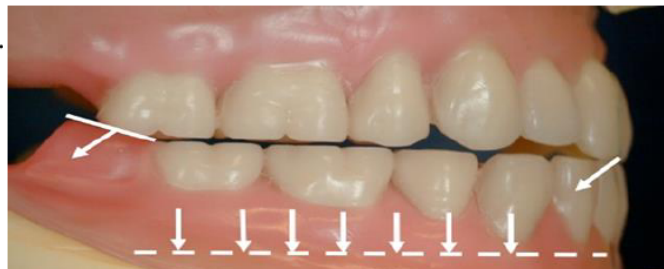1. Jaw size discrepancies CI II, CI III ,malocclusion and cross bite.
2. Uncoordinated jaw movement.
3. Mostly for geriatric patients.
4. minimal ridge ,resorbed ridge ,it reduces horizontal forces—implant may help.

Advantages: 1. Simple technique and less time consuming.

2. Less precise jaw relation records.
3. Lateral forces are reduced by eliminating Cuspal inclines.
4. Simpler and easier occlusal adjustments.
5. Occlusion is not locked.

Disadvantages: 1. Least esthetic.

2. Poor bolus penetration.
3. Cannot be balanced in eccentric excursions

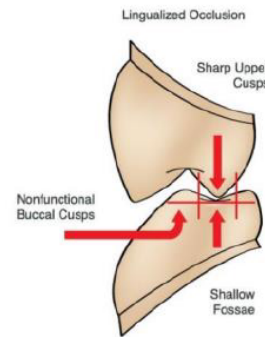


III. Lingualized occlusion: It involves use of large upper palatal cusp against wide shallow lower central fossa.

- The buccal cusps of upper and lower teeth do not contact each other.
- The maxillary palatal cusp tip should contact opposite mandibular central fossa.
- The cusp incline of mandibular teeth relatively flat result in less lateral force and displacement during function.

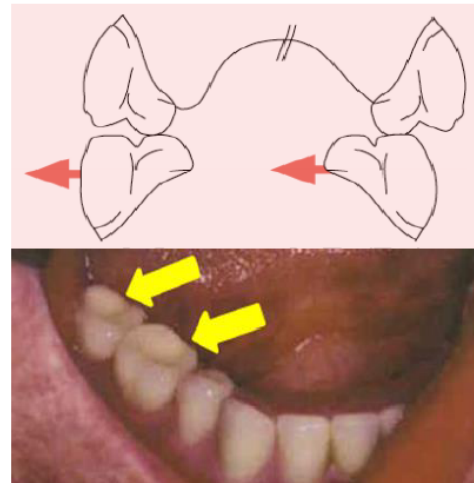
Indication:

- 1.High esthetic needed.
- 2.Weak muscle of mastication.
- 3.Displaceable supporting tissue.
- 4.Severe alveolar bone resorption.
- 5.Discrepancy in jaws size. Narrow upper arch and wide lower arch.
- 6.implant supported over denture.
- 7.Previous successful denture with lingualized occlusion.



Advantages: 1. Simpler technique. Less precise CR records.

2. Esthetics.
3. Better penetration of the food bolus.
4. easier to adjust occlusion
5. it may be used in cII, classIII and cross bite.
6. Centralization of vertical forces.
7. Minimizing tipping force.
8. Potentially of bilateral balance.



Disadvantages:-

- 1.Difficulty in obtaining repeatable centric record (incoordination, jaw malrelation).
2. Severe ridge resorption (lateral forces displace the denture) may more easily be handled with a monoplane scheme.

Types of Occlusal Scheme:

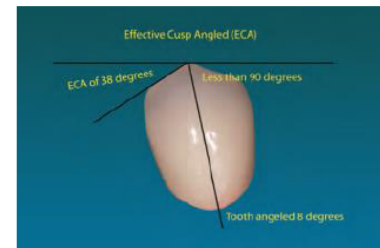
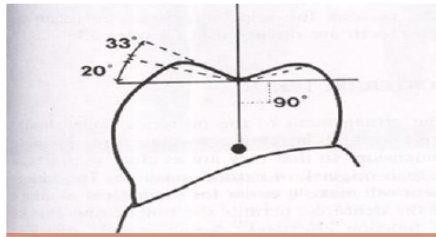
As manufactured, posterior denture teeth exhibit differing cusp angles and cusp heights. Some have minimal or no cuspal angles and are called nonanatomic teeth, while the cuspal angles of semi-anatomic and anatomic teeth vary from approximately 10° to 45° .

The cusp angle is only accurate when the denture tooth is placed so that the long axis of the tooth is perpendicular to the plane of occlusion, if it is altered; the cusp angle of the tooth relative to the occlusal plane is also changed. This altered cusp angle has been termed the **effective cusp angle** of the tooth (ECA).

1. Anatomic teeth: Simulate the natural teeth form with inclination approximately 33°

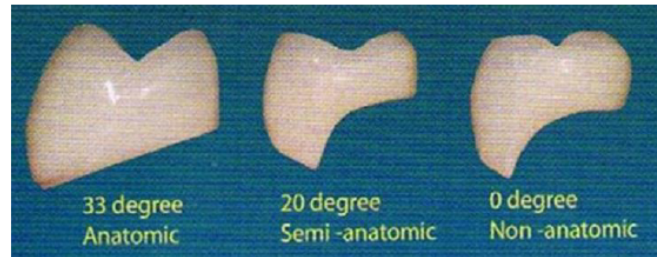
Advantages:

1. Esthetic.
2. Better food penetration.
3. Vertical stress decrease.
4. Harmony with TMJ and muscle of mastication.
5. Balance occlusion in eccentric position



Disadvantages:

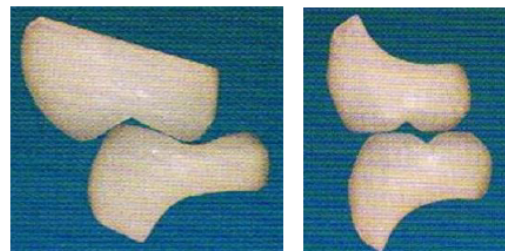
1. Precise technique requires.
2. More time.
3. Difficult teeth position in CL II & CL III.
4. Greater lateral force.



2. Semi anatomic: teeth Cusp incline less steep than anatomical teeth called modified anatomical teeth (less than 33°).

Advantages:

1. Esthetic.
2. Good chewing efficacy.
3. Less lateral force.
4. Balance occlusion.



Disadvantages:

1. Least esthetic. 2. Poor bolus penetration. 3. Cannot be balanced in eccentric excursions

3. Non anatomical teeth: - Flat and without cusp height.

Advantages:

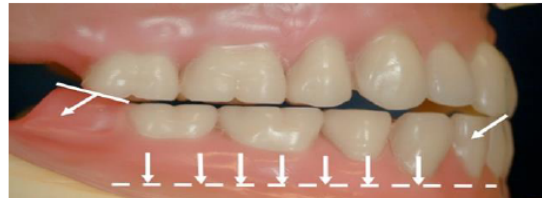1. Used for patient with poor neuromuscular coordination.
2. Used for patient with malrelation jaws.
3. Used for patient with cross bite or class III.
4. More comfortable.
5. Less time required in set up.
6. Slightly more esthetic than neutrocentric occlusion.

Disadvantages:

1. Use of compensatory curve may cause the same damaging effects as cuspal inclines.
2. Occlusal adjustment are more difficult to accomplish.

Balance occlusion for non-anatomic teeth may be accomplish by:

1. Compensating curve.
2. Tilting the second molar.
3. Placing the balancing ramp.

**Factors influencing the selection of selection of occlusal scheme:**

1. Characteristics of occlusal scheme:
 - Tooth form and arrangement
 - Balanced or not
2. Characteristics of the patient:
 - Height and width of the residual ridge
 - Aesthetic demands of the patient
 - Skeletal relations
 - Neuromuscular control
 - Tendency for parafunctional activity