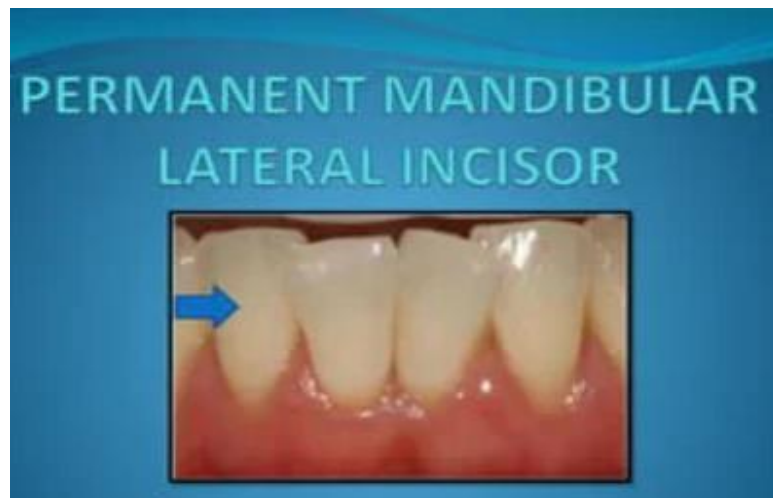

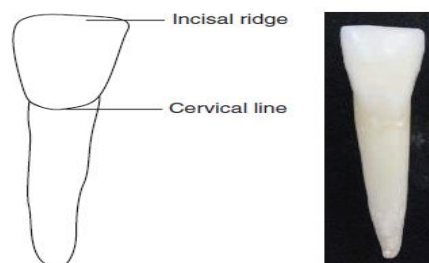
## MANDIBULAR LATERAL INCISORS

The mandibular lateral incisors are located in mesial relation to the central incisors and distal to the canines. These are similar to the mandibular central incisors but have increased mesiodistal and inciso-cervical height in comparison.



### Labial Aspect

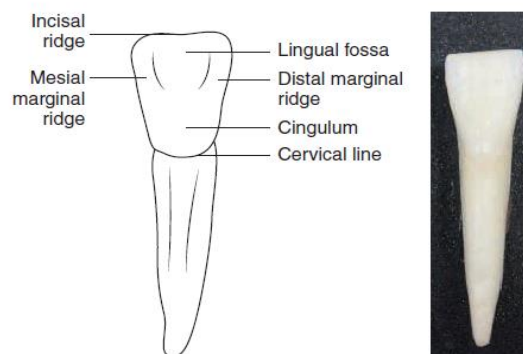
1. Shape of the crown: The shape of the crown is trapezoidal.
2. Labial surface: The labial surface is more rounded mesiodistally than the mandibular central incisors. Developmental grooves are present on the labial surface.
3. Shape of the root: The root is cone-shaped and has a blunt apex.



**Figure 14.23** Labial aspect of the mandibular lateral incisor.

## Lingual Aspect

1. **Shape of the crown:** The shape of the crown is trapezoidal as in the labial side.
2. **Outlines of the crown:** The outlines are similar to the labial aspect.
3. **Lingual surface:** The lingual surface exhibits a cingulum and a lingual fossa bordered by marginal ridges, and these are more prominent than those present in the mandibular central incisors. The mesial marginal ridge is longer than the distal marginal ridge.
4. **Outlines of the root:** The outlines are similar to the labial aspect, but there is a lingual taper along the entire length of the root because of the lingual convergence.



**Figure 14.24** Lingual aspect of the mandibular lateral incisor.

## Mesial Aspect

1. **Shape of the crown:** The crown is triangular or wedge-shaped from this aspect.
2. Outlines of the crown
  - (a) Labial outline: The labial outline from the crest of curvature is straight from the incisal edge to the cervical third and is slightly convex in the cervical third.
  - (b) Lingual outline: The lingual outline is S shaped.
  - (c) Cervical outline: The cervical curvature is convex towards the incisal edge.

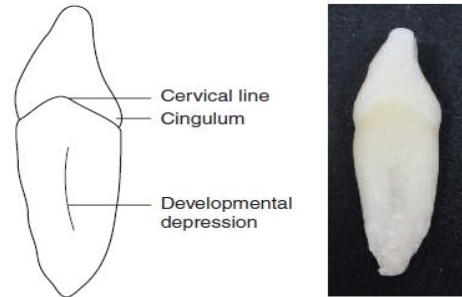
(d) Incisal outline: The incisal ridge forms the apex of the triangular shape of the mesial aspect of the crown and is situated lingual to the root axis.

3. Contact area: The contact area in the mesial aspect is present at the incisal third.

4. Outlines of the root

(a) Labial outline: The labial outline of the crown is straight from the cervical third to the middle third and tapers to the apex.

(b) Lingual outline: The lingual outline is straight from the cervical third to the middle third, and there is a gradual taper to the apical third.



**Figure 14.25** Mesial aspect of the mandibular lateral incisor.

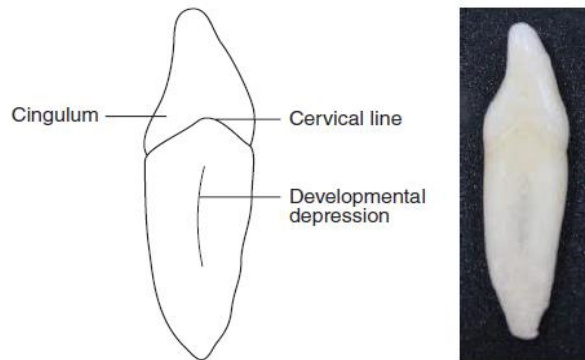
## Distal Aspect

1. **Shape of the crown:** The crown is triangular or wedge-shaped from this aspect.

2. **Outlines of the crown:** The outlines of the crown are similar to the mesial aspect.

3. **Contact area:** The contact area is located at the incisal third.

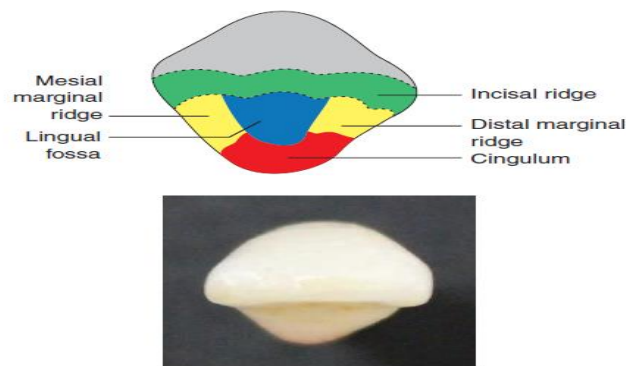
4. **Outlines of the root:** The outlines of the root are similar to those of the mesial aspect.



**Figure 14.26** Distal aspect of the mandibular lateral incisor.

### Incisal Aspect

1. **Shape of the crown:** The crown is roughly ovoid in this aspect.
2. **Outlines of the crown:** The crown is not bilaterally symmetrical, unlike the crown of the mandibular central incisors.
  - a. *Labial outline:* The labial outline curves towards the distal side because of the distal developmental lobe and is not straight as in the mandibular central incisor.
  - b. *Lingual outline:* The lingual outline is convex, with the mesial and distal marginal ridges converging towards the cingulum. The marginal ridges are more prominent, and the lingual fossa is slightly deeper than that of the mandibular central incisors.



**Figure 14.27** Incisal aspect of the mandibular lateral incisor.

**Table 14.1** Differences Between Mandibular Central and Lateral Incisors

Aspect	Mandibular Central Incisor	Mandibular Lateral Incisor
Incisal aspect	Mesiodistal width is lesser than that in the lateral incisor	Mesiodistal width is more than that in the central incisor
Labial aspect	Mesioincisal and distoincisal angles are at right angles	Distoincisal angle is rounded
	Bilaterally symmetrical	Bilaterally asymmetrical
Lingual aspect	Cingulum is centred	Cingulum is slightly distal
	Mesial and distal marginal ridges are equal in length	Mesial marginal ridge is longer than the distal marginal ridge