

## Periodontics with other aspect of dentistry

### Periodontal – Orthodontic Interaction:

The key element in orthodontic management of adult patients with periodontal disease is to eliminate or reduce plaque accumulation and gingival inflammation. This requires great oral hygiene instruction, appliance construction, and periodontal check-up throughout the treatment.

### Orthodontic tooth movement in adults with periodontal tissue breakdown:

Poorly executed orthodontic treatment in periodontal patients can certainly contribute to further periodontal tissue breakdown. In particular, the combination of plaque retention, orthodontic forces, and occlusal trauma may produce a more rapid destruction than would occur with inflammation alone. However, with properly performed treatment, orthodontic tooth movement can be made in adults with a reduced but healthy periodontium without further periodontal deterioration.

### Factors enhancing plaque retention during orthodontic treatment:

- ☒ Complicated appliance design
- ☒ Hooks
- ☒ Elastomeric rings associated with plaque retention more than stainless steel ligatures
- ☒ Excess bonding resin outside bracket base
- ☒ Banding of molars is associated with increased interproximal plaque accumulation than bonding.

However, bonding is unavoidable in case of amalgam restorations and crown-and-bridge restorations made of porcelain or precious metals.

### Orthodontic treatment considerations:

Renewed oral hygiene instruction and motivation is made after placement of the orthodontic appliances. During the treatment period professional tooth cleaning by a dental hygienist or periodontist may be performed at 3-month intervals, or after regular examination updates at 6- and 12- month intervals, depending on the situation. Professional scaling may be indicated during active intrusion of elongated maxillary incisors, since orthodontic intrusion may **shift** supragingival

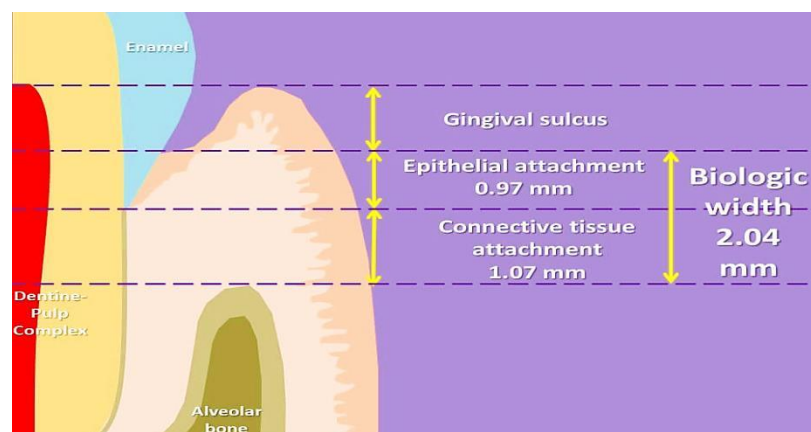
plaque to a subgingival location. The re-examinations should include recordings of probing depths, mobility, bleeding on probing, suppuration, gingival recessions, bone levels, etc. If efforts at maintaining excellent to good oral hygiene are unsuccessful, orthodontic treatment should be terminated. After appliance removal, reinstruction in oral hygiene measures should be given. Otherwise, subsequent labial gingival recession may be risked due to overzealous tooth brushing, since cleaning is now easier to perform.

**Minor surgery associated with orthodontic therapy:** Several forms of minor periodontal surgery may be used to improved, or stabilize the results achieved by orthodontic treatment of malocclusion.

- ☒ **Frenectomy:** this type of surgery indicated in case of very hyperplastic type of frenum, with a fan like attachment, which may obstruct diastema closure so the frenum should be removed
- ☒ **Fiberotomy:** include the removal of supra-crestal gingival tissues which seems to contribute to rotational relapse after orthodontic treatment.
- ☒ **Gingivectomy:** it may be used to increase the clinical crown during or after ortho treatment and in case of gingival discrepancy is apparent
- ☒ **Use of implants:** in orthodontic treatment, osseointegrated implant may be used. This technique is expensive and if this has to be done, close cooperation between orthodontist, periodontist, and oral surgeon is important for optimal treatment planning and implant positioning.

### **Periodontal – Restorative Interaction:**

The **biological width** is defined as the dimension of the soft tissue, which is attached to the portion of the tooth coronal to the crest of the alveolar bone



## **Margin placement guidelines or restorative margin location:-**

### **Supragingival margin:**

- Least impact on the periodontium.
- Preparation of the tooth and finishing of the margin is easiest
- Duplication of the margins with impressions can be done with ease.
- Fit and finish of the restoration and removal of excess material is easiest
- Verification of the marginal integrity of the restoration is easiest

**Equigingival margin:** Previously it was thought that it retains more plaque than supra & sub gingival margins therefore result in greater gingival inflammation.

### **Subgingival margin:**

- Greatest biologic risk.
- Not as accessible as supra or equi for finishing procedures.

## **Location of restorative margins is determined by many factors**

1. Esthetic concerns.
2. Need for increased retention form
3. Refinement of pre-existing margins.
4. Root caries.
5. Cervical abrasion
6. Root sensitivity.

When determining where to place restorative margins relative to the periodontal attachment, it is recommended that the patient's existing **sulcus depth** is used as a guideline in assessing the biologic width requirement for that patient. The extension of any restorative margin into the gingival sulcus should be considered a compromise, but esthetic or retentive demands often make it necessary.

Hence, **subgingival margin** should be considered a **compromise**, and **supragingival margins** are **preferred**. The marginal fit should be optimal because rough restorations or open margins lead to an accumulation of bacterial pathogens that are associated with inflammatory periodontal diseases. Subgingival margins demonstrated increased plaque, gingival index score and probing depths. Furthermore, more spirochetes, fusiforms, rods and filamentous bacteria were found to be associated with subgingival margins.

## **Crown Contour**

When the gingiva contacts a flat (**noncontoured**) tooth surface, there is a tendency to develop a thick free gingival margin. **Overcontouring** of restorations or faulty placement of contour is a much greater hazard to periodontal health than is lack of contour, since both supra- and subgingival plaque accumulation may be enhanced by overcontoured margins. The greater the convexity, the more difficult it is to remove the plaque. The facial or lingual surface of a restoration **should not have more than 0.5 mm** bulge adjacent to the gingival margin because this may interfere with adequate plaque removal. It has been hence opinioned that buccal and lingual crown contours should be 'flat', not 'fat' usually less than 0.5 mm wider than the cemento-enamel junction, and those furcation areas should be 'fluted' or 'barreled out' to accommodate oral hygiene in these areas.

## **Interproximal Contacts and Embrasure Space:**

Normally, there must be a positive contact relation mesially and distally of one tooth with another in each dental arch. The areas of contact are small and not mere points of contact. Contact areas keep food from being trapped between the teeth and help to stabilize the dental arches by the combined anchorage of all teeth in either arch in positive contact with each other. In order to maintain the healthy gingiva in the interdental areas, the contact points should be located incisally or occlusally and buccally.

## **Hazards of contact when placed:**

- Occluso-gingivally
- Narrow Contact
- Contact too far gingivally
- Contact too far occlusally
- Too far buccal/ lingual
- Open Contact

**Any change in shape or form of embrasure form of the papilla. → Food impaction → Change in height & Accumulation of micro-organisms & Plaque accumulation.**

Too Wide Embrasure	➡	Flattened & Blunt Papilla
Narrow Embrasure	➡	Inflamed Papilla
Ideal Embrasure	➡	Healthy & pointed Papilla

### **Pontic Design**

Pontic should be both esthetically and functionally replace lost teeth, and at the same time be nonirritating to the mucosa and allow effective plaque control. Classically, **four options** should be considered in evaluating pontic design: Sanitary, ridge lap, modified ridge lap and ovate designs.

**The sanitary and ovate pontic** have convex undersurfaces that facilitate cleaning. **The ridge lap and modified ridge lap** designs have concave surfaces that are more difficult to access with dental floss.

A **modified ridge lap design** can be given where there is inadequate ridge to place an ovate pontic. Whereas the facial aspect of the undersurface has a concave shape, adequate access for oral hygiene is allowed by the more open lingual form.

**Hypersensitivity to Dental Materials:** More importantly, tissues respond more to the differences in **surface roughness** of the material rather than its composition. The rougher, the surface of the restoration subgingivally, the greater the plaque accumulation and gingival inflammation. Non-Precious alloys show hypersensitive inflammatory response.

Restorative Materials whenever the material is smooth, its ability to retain plaque is less (but not less than enamel). Restorative materials are not themselves injurious to the periodontal tissues. The surface of restorations should be as smooth as possible to limit plaque accumulation. Resins are highly polishable, but have deficiencies in strength, porosity and wear. Glass ceramics and porcelain veneers offer a clear advantage over any other type of restorative materials in the maintenance of gingival health. All restorations should be with no overhang or poor margins by using matrix retainer and good condensation. Whatever the restoration that we made, we have to make it like natural tooth by carving, so the forces of occlusion will be directed more vertically than laterally on this restoration which in turn better accommodated by the PDL.

## **Sub-gingival debris**

Leaving debris below the tissue during the restorative procedure can cause adverse PDL changes.

Causes:

- Retraction cords
- Impression material
- Provisional material
- Cements

## **Endodontic –Periodontic Interaction**

### **Anatomic Considerations**

There is an intimate relationship between the periodontium and pulpal tissues. As the tooth develops and the root is formed, 3 main routes for communication are created: 1-Apical Foramen 2-Lateral and Accessory Canals 3-Dentinal Tubules

### **Apical Foramen**

It is the principal and the most direct route of communication between the pulp and periodontium. Bacterial and inflammatory byproducts may exit readily through the apical foramen to cause periapical pathosis. The apex may also serve as a portal of entry of inflammatory byproducts from deep periodontal pockets to the pulp.

### **Lateral and Accessory Canals**

These may be present anywhere along the root. Patent accessory and lateral canals may serve as a potential pathway for the spread of bacterial byproducts. 30-40% of all teeth have lateral or accessory canals and the majority of them are found in the apical third of the root.

### **Dentinal Tubules**

Exposed dentinal tubules in areas of denuded cementum may serve as communication pathways between the pulp and PDL. In the root, dentinal tubules extend from the pulp to the dentinocemental junction. They range in size from 1 to 3 microns in diameter (bacteria and their toxins are smaller in size). The tubules may be denuded of their cementum coverage as a result of periodontal disease, surgical procedures or developmentally when the cementum and enamel do not

meet at the CEJ thus leaving areas of exposed dentin. Patients experiencing cervical dentin hypersensitivity are examples of such a phenomenon. Additional Avenues of communication between the Pulp and the Periodontium

**Developmental malformations** such as **palatogingival grooves** of maxillary incisors. These usually begin in the central fossa, cross the cingulum, and extend apically with varying distances. **Perforations** these may result from extensive carious lesions, resorption, or from operator error. **Vertical root fractures** – these can produce deep periodontal pocketing and localized destruction of alveolar bone. The fracture site provides a portal of entry for irritants from the root canal to the PDL

### **Differential Diagnosis of Endo/Perio Lesions**

The following classification system was developed by Simon, Glick and Frank in 1972:

- Primary endodontic disease
- Primary periodontal disease
- Primary endodontic with secondary periodontal disease
- Primary periodontal disease with secondary endodontic disease
- True Combined Lesions

### **Primary endodontic disease**

Typically, endodontic lesions resorb bone apically and laterally and destroy the attachment apparatus adjacent to a **non-vital tooth**. It is possible for an acute exacerbation of a chronic periapical lesion on a tooth with a necrotic pulp to drain through the PDL into the gingival sulcus. This clinical presentation mimics the presence of a periodontal abscess, or a deep periodontal pocket. When endodontic infection **drains through the PDL, the pocket is very narrow and deep**. In reality, it is a sinus tract of pulpal origin that opens through the PDL, and not breakdown due to periodontal disease. A similar situation can occur where drainage from the apex of a **molar tooth extends coronally into the furcation area**. These cases **resemble** a “through-and-through” furcation defect (Grade III) of periodontal disease.

**For diagnostic purposes**, it is imperative to trace the sinus tract by inserting a gutta-percha cone and exposing one or more radiographs to determine the origin of the lesion. The sinus tract of endodontic origin is readily probed down to the tooth apex, where no increased probing depth would otherwise exist around the tooth. Primary endodontic disease **will heal** following root canal treatment . The sinus tract extending into the gingival sulcus or the furcation area disappears at an early stage once the necrotic pulp has been removed and the root canals are well sealed.

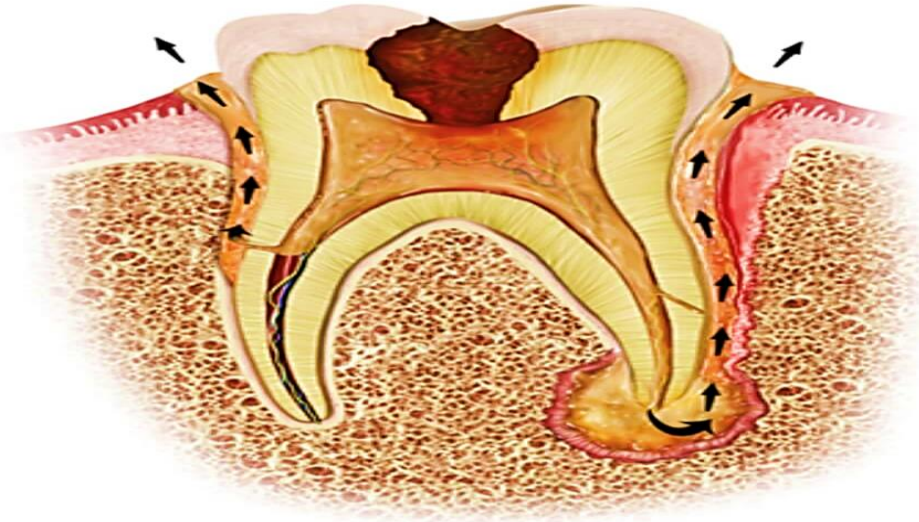
**Primary periodontal disease** Caused by periodontal pathogens. It is the result of progression of chronic periodontitis apically along the root surface. **Pulp tests yield a clinically normal pulpal reaction** . Frequently accumulation of plaque and calculus are seen throughout the dentition. Periodontal pockets are wider, and generalized The prognosis depends on the stage of periodontal disease and the efficacy of periodontal treatment

#### **Primary endodontic disease with secondary periodontal disease**

This happens with time as suppurating primary endodontic disease remains untreated, it may become secondarily involved with periodontal breakdown. Plaque forms at the gingival margin of the sinus tract and leads to plaque induced periodontitis in the area. The pathway of inflammation into the periodontium is through the apical foramen, accessory and lateral canals.

The treatment and prognosis are now different than those of teeth simply having endodontic or periodontal disease. The tooth now **requires** both endodontic and periodontal treatments. If the endodontic treatment is adequate, the prognosis depends on the severity of the plaque-induced periodontitis and the efficacy of periodontal treatment. With endodontic treatment alone, only part of the lesion will heal to the level of the secondary periodontal lesion Root fractures and perforations may also present as primary endodontic with secondary periodontal involvement.



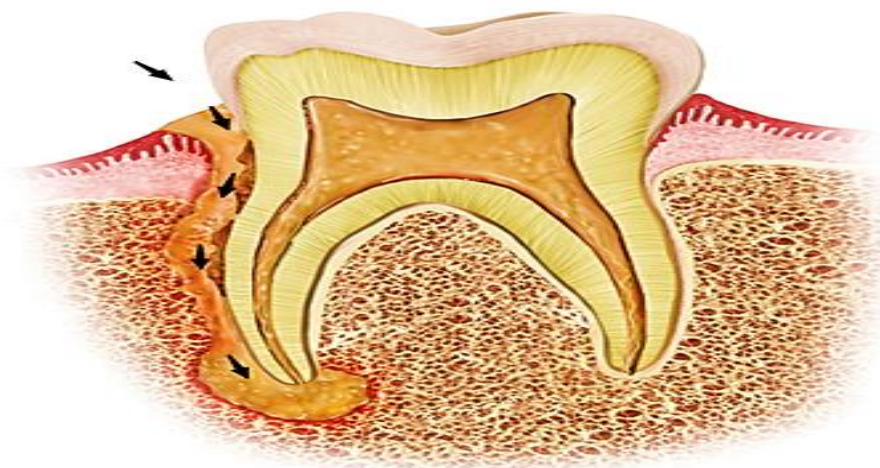


Primary endo/secondary perio lesion

### Primary periodontal disease with secondary endodontic disease

In this case, the apical progression of a periodontal pocket continues until the apical tissues are involved. The pulp may become necrotic as a result of infection entering via the apical foramen or progression of periodontitis by way of lateral canal and apex to induce a secondary endodontic lesion.

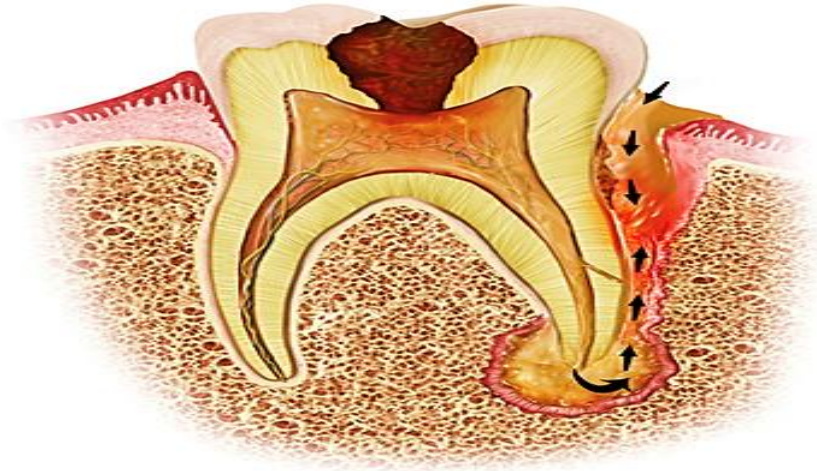In **single-rooted teeth** the **prognosis** is usually poor, as the periodontal breakdown is very severe, necessitating extraction. In **molar teeth** the prognosis may be better, since not all the roots may suffer the same loss of supporting periodontium. Root resection may be considered as a treatment alternative.



Primary perio/secondary endo lesion

## True Combined Disease

True combined endodontic/periodontal disease occurs less frequently than other problems. It is formed when an endodontic disease progressing **coronally** joins with an infected periodontal pocket progressing **apically**. The degree of attachment loss in this type of lesion is large and the prognosis is poor, particularly for single-rooted teeth.



True combined lesion

## Diagnosis

A thorough clinical and radiographic examination is imperative for developing a diagnosis

Data collected must include:

- ☒ **Periapical radiographs**
- ☒ **Pulp vitality testing: cold, EPT, cavity test**
- ☒ **Percussion**
- ☒ **Palpation**
- ☒ **Pocket probing**
- ☒ **Sinus tract tracking**
- ☒ **Cracked tooth testing: transillumination, tooth-sloth, staining.**

## Treatment Decision-Making and Prognosis

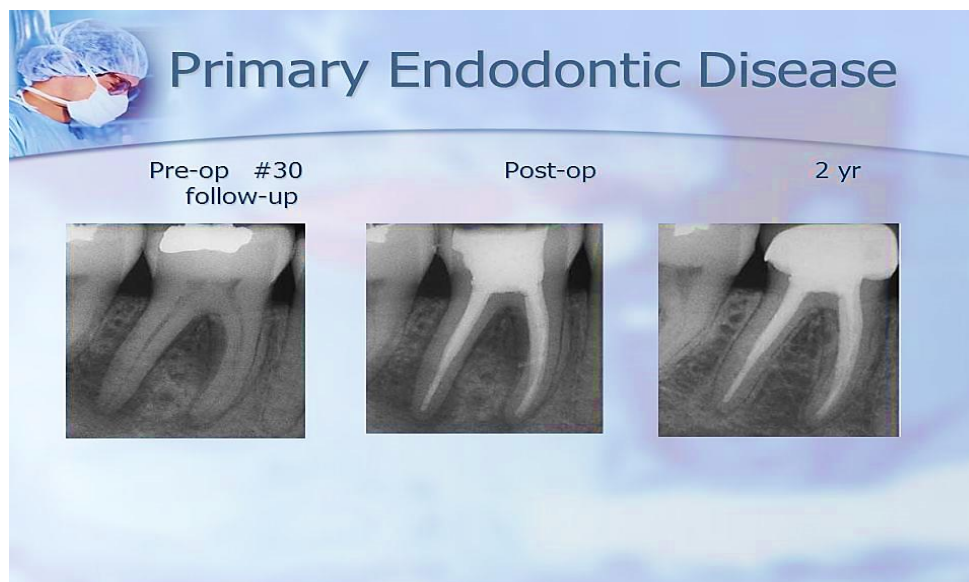
Treatment decision-making and prognosis depend primarily on the diagnosis of the specific endodontic and/or periodontal disease. The main factors to consider are pulp vitality and type and extent of the periodontal defect. Diagnosis of primary endodontic and primary periodontal disease usually present no clinical difficulty.

**In primary endodontic**, the pulp is nonvital while in **primary periodontal** the pulp is vital. However, the diagnosis of the combined endo/perio lesions could present a challenge as they present clinically and radiographically very similar. The prognosis and treatment of each endo/perio disease type varies.

**Primary endodontic disease** should only be treated by endodontic therapy and has a good prognosis.

**Primary periodontal** should only be treated by periodontal treatment. The prognosis depends on severity of the periodontal disease and patient response to treatment.

**Combined lesions** should be treated with endodontic therapy first. Treatment should be evaluated in **2-3 months**, and only then should periodontal treatment be considered. This sequence allows for sufficient time for initial tissue healing and better assessment of the periodontal condition to determine if the tooth needs scaling/root planing only or surgical treatment. Prognosis depends on the periodontal involvement and treatment. Cases of true combined disease usually have a poor prognosis.



## **Prosthodontic & periodontic interaction**

The acrylic partial denture is transient not permanent denture. It is made of acrylic which will become in intimate contact with the gingival tissues and it is documented that acrylic has **a good ability for plaque retention** so there will be increased in severity of gingival disease. Most of the forces applied by the partial denture is of **lateral direction** that cause PDL destruction. Thus, the new direction of knowledge now is toward the fixed bridge. In case of free end extension, the denture will focus the torqueing forces on anterior teeth only and in years we will face mobile anterior teeth due to PDL destruction . It is recommended to use chrome-cobalt partial denture rather than acrylic one in all cases except immediate one. A special instruction and motivation for the patient is mandatory for proper oral hygiene.