

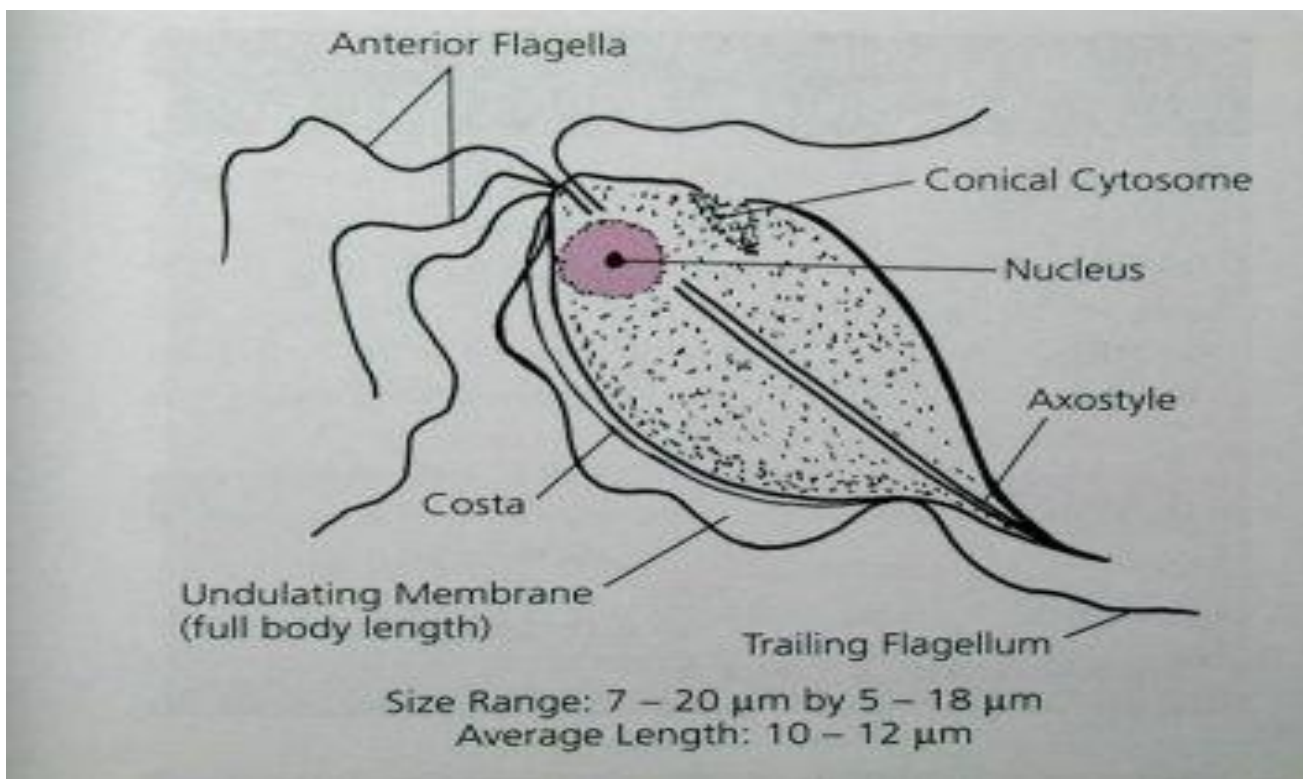
## Practical parasites

### Lab.-7 ( *Trichomonas species* )

Subphylum: Mastigophora

Class: Zoomastigophora

1-*T. hominis* Non-pathogenic .The natural habitat is the lumen of the cecum. Trophozoite is pear shaped(1nucleus at anterior end," 3-5flagella 3anti.,1 post", central karyosome, axostyle in the middle and undulating membrane is the whole length).There is no cyst stage. Laboratory diagnosis by stool examination. Transmission occurs by ingesting trophozoites.

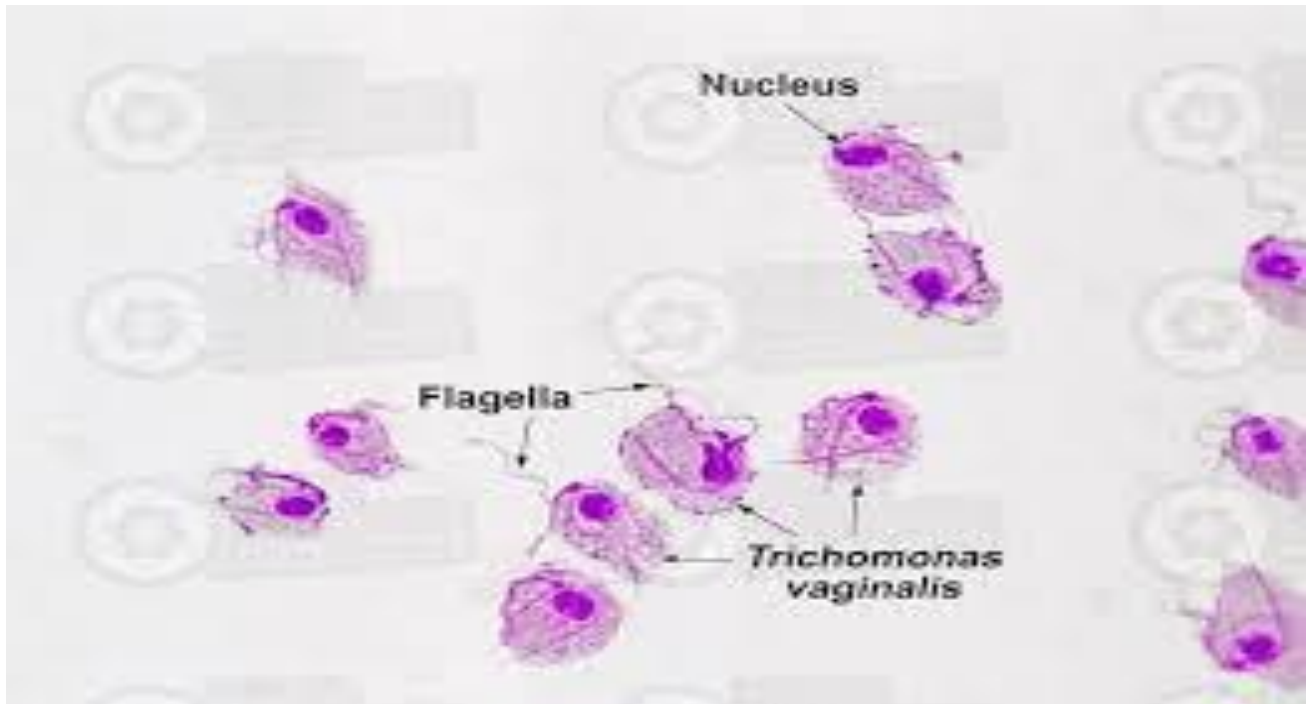
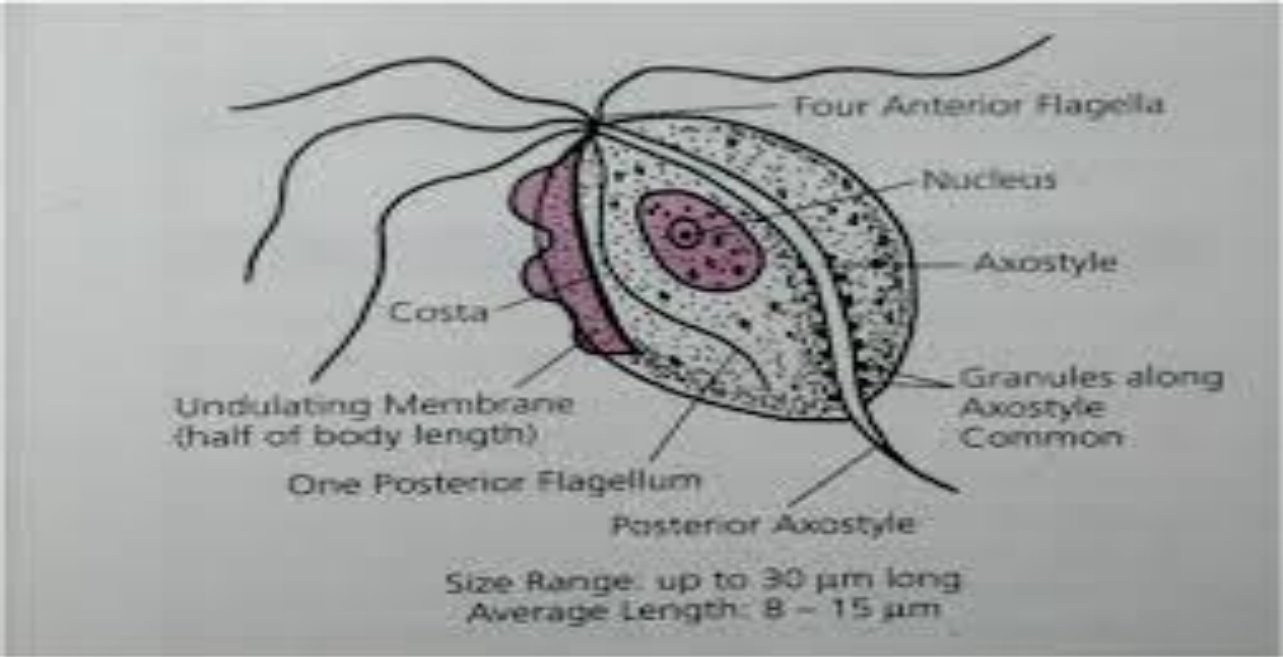


*T.hominis* (Trophozoite Diagram)

**2-T.tenax** Non-pathogenic .The natural habitat is the mouth particularly gums and teeth. Life cycle consist of trophozoite(5 flagella "4 to anterior end and 1 to post.", containing undulating membrane extend 2/3 body length gives the wave like and there is no cyst stage. Laboratory diagnosis by mouth scrapings.

**3-T.vaginalis** Caused Trichomoniasis.) The life cycle consist of trophozoite and there is no cyst stage. The natural habitat is mucosa surface of the vagina in infected women. The most infection site in males is the prostate gland and epithelium of urethra. The mode of transmission is sexual intercourse, contaminated toilet articles or underclothing, communal bathing. These trophozoites may also migrate through a mother's birth canal and infect\_ the unborn child.

**Trophozoites:** Ovoid, round or pear like in shape jerky motility contain 4-6 flagella originated from anterior end only one extends posterior. The undulating membrane fis short,extend only 1/2of body length. The single nucleus is ovoid (Axostyle that often curves /around the nucleus and extends posterior beyond the body. Granules/may be found along the axoctyle/



## **Laboratory diagnosis**

**1-Trophozoite may be recovered in urine vaginal discharges, urethral discharges and prostatic secretions.**

**2-Phase-contrast microscopy.**

**3-Fluorescent stains.**

**4-Monoclonal antibody assays( MAA).**

**5-Enzyme immunoassays/(EIA). 6-Cultures.**