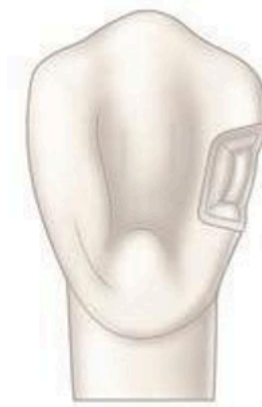

## CL III amalgam restoration

CLIII restoration indicated for defects in the proximal surface of incisors and canines without Incisal edge involvement fig1.



a



b

Fig1: a. Cl III caries, b. Cl III cavity

### **Indications:**

It is generally reserved for **the distal surface of maxillary and mandibular canines** if Moisture control is difficult.

For esthetic reasons, amalgam rarely is indicated for the proximal surfaces of incisors and the mesial surface of canines.

### **Contraindications:**

Class III amalgam restorations usually are contraindicated in **esthetically** important areas because many patients object to metal restorations that are visible

**Advantages:**

1. Amalgam restorations are stronger than other Class III direct restorations.
2. They are generally easier to place.
3. Less expensive to the patient.
4. Amalgam restorations are usually easier to finish and polish without damage to the adjacent surfaces.

**Disadvantage:**

1. Metallic color.
2. Less conservative cavity preparation when compared to that of esthetic restorative materials.

**Outline form:**

The outline form of the Class III amalgam preparation may include only the proximal surface fig2a. A lingual dovetail may be indicated if one existed previously or if additional retention is needed for a larger restoration fig 2b.

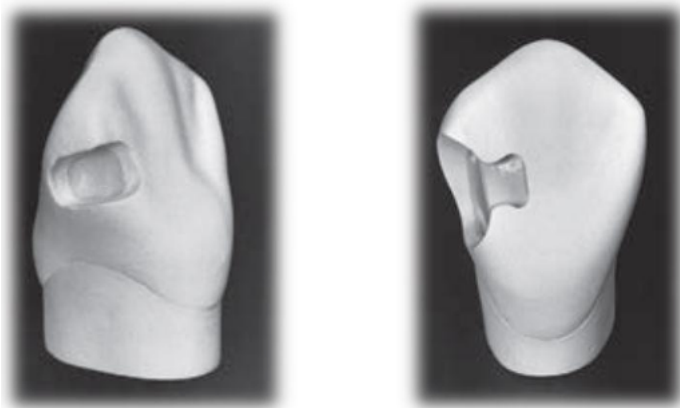


Fig2: a. Cl III preparation from proximal view, b. Cl III with dovetail.

**Resistance form:**

Resistance form against post-restorative fracture is provided by

- (1) Cavosurface and amalgam margins of 90 degrees.
- (2) Removal of unsupported enamel.
- (3) Sufficient bulk of amalgam (minimal 1-mm thickness).
- (4) Rounded internal angles.
- (5) Conserve the disto-incisal tooth structures as possible to reduce the risk for fracture

**Retention form:**

Retention form for Cl III preparation is provided by:

- (1) The box-like preparation form.
- (2) Gingival groove, incisal cove, and sometimes a lingual dovetail.

**Tooth Preparation**

A lingual access preparation on the distal surface of the maxillary canine is described here for esthetic reasons. fig3.

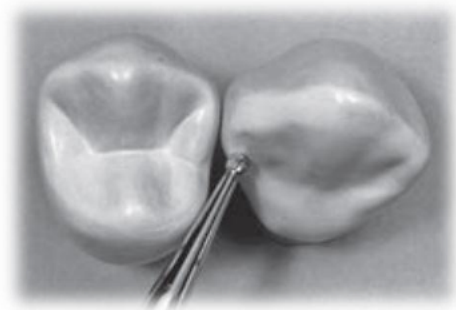


Fig3: initial entry for Cl III which conserve the marginal ridge.

Bur size selection depends on the size of the lesion, bur options may include a round bur, the bur is positioned so that the entry cut penetrates into the caries lesion, Ideally, the bur is positioned so that its long axis is perpendicular to the lingual surface of the tooth, but directed at a mesial angle as close to the adjacent tooth as possible, this position conserves the marginal ridge enamel fig3.

Initial axial depth (0.5 mm) inside the DEJ or 0.75 mm axial depth when the gingival margin is on the root surface (in cementum)

(Infected dentin that is deeper than this limited initial axial depth is removed later during final tooth preparation) the cavity of CI III is made in a box-like preparation.

The **gingival retention groove** is prepared by placing a no.14 round bur (rotating at low speed) in the axio-facio-gingival point angle, It is positioned in the dentin to maintain 0.2 mm of dentin between the groove and the DEJ, the rotating bur is moved lingually along the axio-gingival line angle fig4.

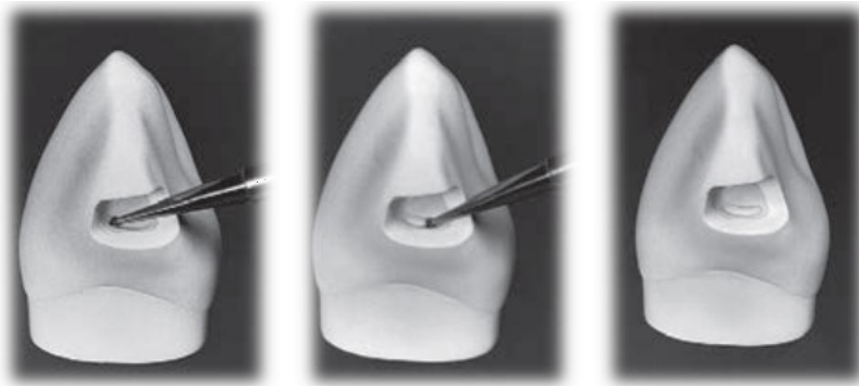


Fig4: Preparing the gingival retention form. A, Position of No. 14 round bur in axio-facio-gingival point angle. B, advancing the bur lingually to prepare the groove along the axio-gingival line angle. C, Completed gingival retention groove.

If less retention form is needed, two gingival **coves** may be used, as opposed to a continuous groove placed in the axio-gingivo-facial and axio-gingivo-lingual point angles, the diameter of the 14 round bur is 0.5 mm, and the depth of the groove should be half this diameter (0.25 mm).

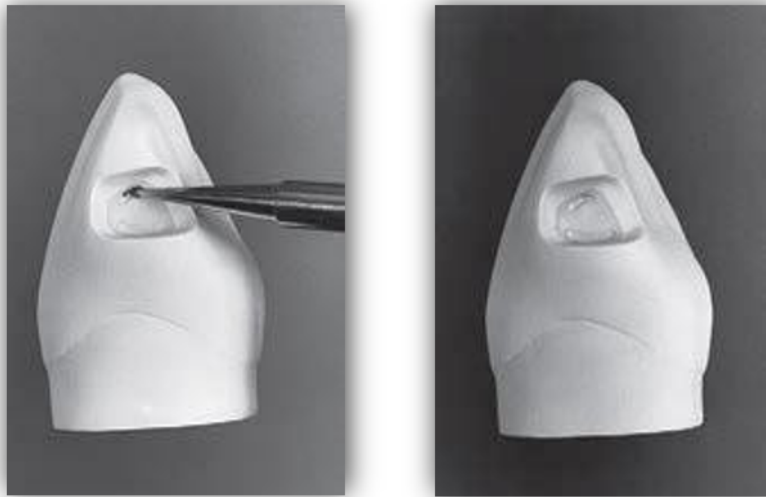


Fig5: Preparing the incisal retention cove. A, Position of No. 14 round bur in the axio-incisal point angle. B, Completed incisal cove.

If a lingual **dovetail** is needed fig6:

- It is prepared only after initial preparation of the proximal portion has been completed.
- The lingual dovetail should be conservative, generally not extending beyond the mesio-distal midpoint of the lingual surface; this varies according to the extent of the proximal caries.
- The axial depth of the dovetail should approximate 1 mm.

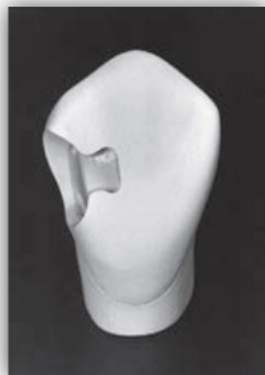

fig 6: lingual dovetail in Cl III

