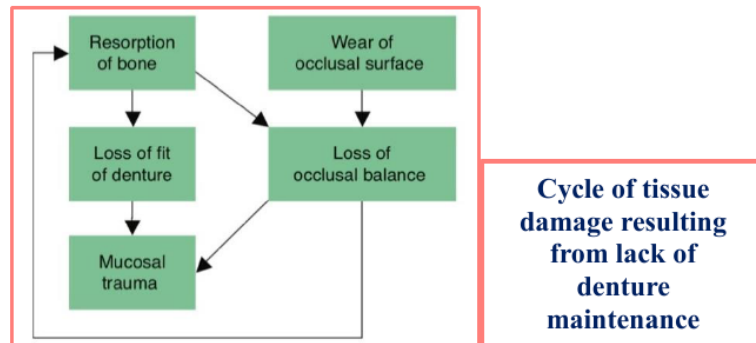


Complications in complete denture wearers

In this lecture, we stress the importance of planning a program of recall appointments after fitting complete dentures, to ensure that the tissues are not being damaged and that the dentures are functioning efficiently and comfortably. A recall visit also gives the patient an opportunity to seek advice over any concerns. To reduce the risk of mucosal damage and bone resorption in complete denture wearers, a check should be made every year. It is important that the patient is not under the mistaken belief that once the artificial substitute for the natural teeth has been provided there will be no further problems, and no need for further maintenance. Epidemiological studies of edentulous population have shown that most patients with complete dentures have pathologic tissue changes that require treatment.

Long term recall appointments done because the following changes occurred

- Mucosal changes
- Bone resorption
- Occlusal changes
- Adaptation of patient.



Mucosal changes

The need to carry out periodic checks with respect to oral cancer was stressed. In 2007, in the UK, there were 5325 new cases and 1841 deaths, with an increased prevalence in deprived communities. It should be emphasized that the typical edentulous patient falls into a risk group, as a retrospective study of patients with oral cancer showed that 59% were edentulous, tended to be older than 60 years, were tobacco and alcohol users, had a lower socioeconomic status and had a somewhat negative attitude to recall appointments.

Bone resorption

The long-term changes in shape of the residual ridges and the consequent effect on dentures have been studied extensively. A continuing reduction in height of the alveolar ridges over a period of 25 years has been observed. There appears to be a marked reduction in the first year of denture wearing and in the next few years a continuing loss averaging 1 mm each year. Over periods of time, the loss in height of the anterior lower ridge is four times that of the upper. As the lower denture covers a much smaller area, the functional stress transmitted to

the underlying tissues is greater than that to the upper tissues; thus, it is likely that the greater loss of mandibular bone is due to the physiological limit of this tissue being exceeded. The resorption of bone brings loss of both occlusal vertical dimension and rest vertical dimension. The former dimension is reduced to a greater extent and thus the freeway space is increased.

Occlusal changes

The progressive loss of fit of dentures, resulting from resorption of bone, also leads to deterioration in occlusal balance. In the case of dentures with acrylic teeth this occlusal deterioration can be aggravated by occlusal wear. The combination of loss of fit and occlusal imbalance encourages mucosal inflammation and further bone resorption, thus establishing a vicious cycle. It is clearly important, if oral health and function are to be maintained, that this cycle is broken by regular denture review and effective maintenance.

Adaptation of the patient

The progressive long-term deterioration of dentures that has been described is not invariably associated with a complaint. This is because adaptive changes can occur and a tolerance can develop which allows patients to continue wearing the dentures. Thus, a considerable amount of tissue damage can go unnoticed. Whereas successful adaptation to new dentures is a prerequisite for success, a patient who tolerates slowly developing faults beyond a certain point will store up troubles for the future.

The first long-term recall appointment should be made no more than a year after the dentures were first fitted. Thereafter, an appointment every 2 or 3 years to check on tissue health and quality of the dentures, understanding that the patient will attend sooner if problems develop in the meantime. The clinician should make the point that the dentures have a limited life and should stress to patient potential dangers of wearing dentures that have become inadequate.

Treatment at long-term recall appointments will be one, or a combination, of following:

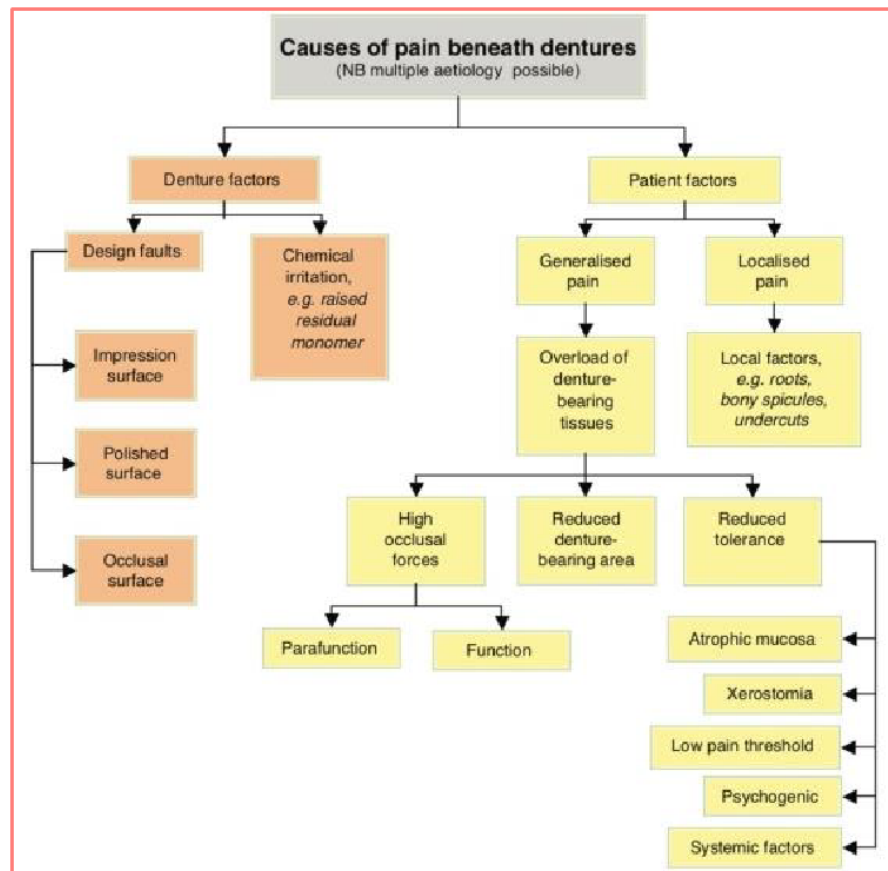
- Adjustment of the impression surface
- Correction of denture base extension
- Occlusal adjustment with or without a check record
- Reline or rebase of the dentures
- Construction of replacement dentures.

Following prosthetic complications have been recorded as a result of research done by Hakan B. et al 2012 for complete denture wearers:

1. Loss of retention (62.5%)
2. Existence of any denture irritation or ulceration (51.6%)
3. Existence of any fracture in the denture base (31.3%)
4. Existence of any debonded/fractured artificial teeth (26.6%)
5. Existence of denture stomatitis (9.4%)
6. Existence of epulis fissuratum
7. Existence of inflammatory papillary hyperplasia

Some Clinical Problems and Solutions associated with complete denture

- Pain and instability
- Oral mucosal lesions
- Hard and soft materials
- Lack of saliva
- Midline fracture
- Debonding of teeth
- Gagging reflex
- Disturbance of speech.



• **Pain and instability:** The most common problems associated with complete dentures are pain and instability of the dentures. They are summarized in the table above. The most likely main complaints have been indicated in each case. However, it should be remembered that there is considerable overlap between the two columns, as any cause of instability may additionally give rise to a complaint of pain. It should also be stressed that there may be more than one cause of a complaint.

Persistent pain: This problem is more often seen in the lower jaw where the area available for distribution of the occlusal load is relatively small. As noted in the table above, there are many possible causes of this complaint, which may be attributed to the denture design and to the patient.

Discomfort can arise from overloading of the mucosa as a result of clenching or grinding the teeth. These occlusal habits are caused by increased activity of the masticatory muscles produced during stressful situations.

In treating parafunction, the patient must be made aware of the problem and should be told that teeth should be out of contact for most of the time. It is important to reassure the patient, describe the link between stress, parafunction and pain under dentures and point out that there is no change in the oral mucosa. The importance of conscious relaxation should be emphasized and the patient should be strongly encouraged to leave both dentures, or at least the lower denture, out at night.

• **Oral Mucosal Lesions Induced by Removable Dentures**

Lesions of the oral mucosa associated with the wearing of removable dentures may represent acute or chronic reactions to microbial denture plaque, a reaction to constituents of the denture base material or a mechanical denture injury.

Causes of Mucosal Irritation

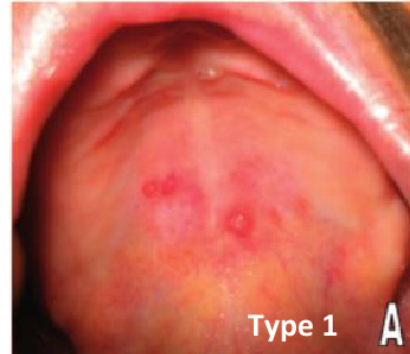
1. Mechanical irritation by denture
2. Accumulation of microbial plaque on denture
3. Toxic or allergic reaction to constituents of denture material

* Local irritation of mucosa, increase mucosal permeability to allergens or microbial antigen.

Types of these lesions:

1. Denture stomatitis: also termed:

- ✓ Denture sore mouth
- ✓ Denture- induced stomatitis
- ✓ Chronic atrophic candidiasis
- ✓ Candida-associated denture induced stomatitis
- ✓ Denture-associated erythematous stomatitis



Is a common condition where mild inflammation and redness of the oral mucous membrane occurs beneath a denture. In about 90% of cases, *Candida* species are involved. This is normally a harmless component of the oral microbiota in many people.

It is usually painless and asymptomatic. The appearance of the involved mucosa is erythematous (red) and edematous (swollen).

Classification

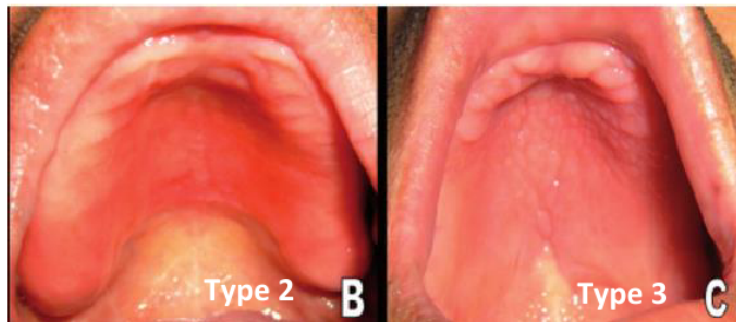
The Newton classification divides denture-related stomatitis into three types based on severity. Type one may represent an early stage of the condition, while type two is the most common and type three is uncommon.

Type 1 - Localized inflammation or pinpoint hyperemia

Type 2 - More diffuse erythema (red) in part or all of mucosa which is covered by denture

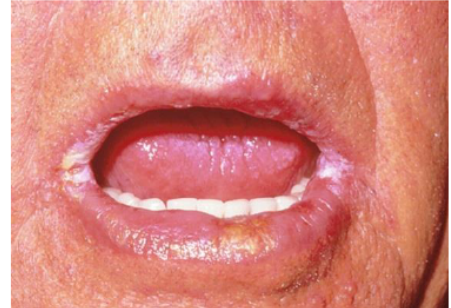Type 3 - Inflammatory nodular/papillary hyperplasia usually on the central part of hard palate and the alveolar ridge. This type often is seen in association with type 1 or type 2. This condition is multifactorial, **the causes include:**

1. Ill fitted denture.
2. Disharmonious occlusion.
3. Nutritional deficiencies.
4. Poor oral hygiene.
5. Candidal infection.
6. Wearing the denture continuously.



2. Angular Cheilitis: also called (angular stomatitis) is inflammation of one or both of the corners (angles) of the mouth. There are many possible causes, including:

- ✓ Nutritional deficiencies (iron, B vitamins, folate)
- ✓ Contact allergy
- ✓ Infection (Candida albicans, Staphylococcus aureus or β -hemolytic streptococci, often with overclosure of the mouth and associated with denture-related stomatitis).

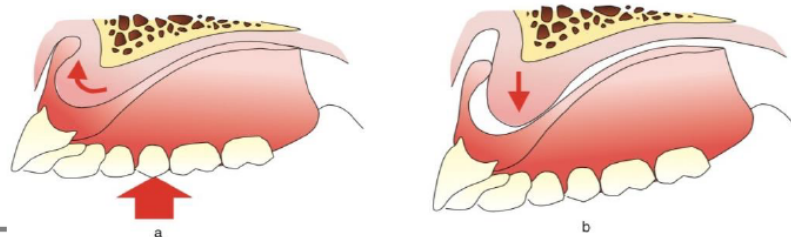


3. Flabby ridge: Also called **alveolar fibrosis** i.e. removable and extremely resilient alveolar ridge, is due to replacement of bone by fibrous tissue, in a generalized and localized form, it is seen most commonly in the anterior part of the maxilla, particularly when there are remaining anterior teeth in the mandible that condition, called the 'combination syndrome'. Flabby ridges provide poor support for the denture; it is probably wise to keep such patients under regular review to ensure that a dramatic level of damage is not occurring.

Management Approaches: is somewhat controversial, opinion falling into two camps.

In one, surgical removal of the fibrous tissue is favoured in every case where the health of the patient allows. This approach produces a firm ridge which is reduced in size. Advocates of the opposing view suggest that surgical removal should rarely, if ever, be carried out because the fibrous tissue may have a cushion effect which reduces trauma to the underlying bone. If the tissue is removed, it must be replaced by denture base material with consequent increase in the bulk and weight of the prosthesis.

Second, Non-surgical treatment: A key aspect in the non-surgical management of the flabby ridge is the choice of impression technique employed; to employ a mucodisplacive impression technique which compresses the flabby tissue in order to try and obtain maximum support from it or, to use a mucostatic impression technique with the aim of achieving maximum retention.

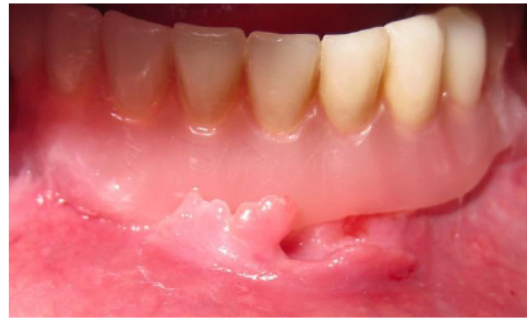

4. Denture irritation hyperplasia: A common tissue reaction to ill-fitting denture is the occurrence of tissue hyperplasia of the mucosa in contact with denture border. They includes:

A- Epulis fissuratum: usually asymptomatic and clinically appear as numerous folds or highly vascular tissue in the labial or buccal vestibule and ulceration might occur at the mucobuccal fold commonly in the maxillary arch. Usually it occur as a result of reduction of the residual alveolar ridge especially in case of immediate denture when bone loss is rapid and the patient fail to make a new denture or relining within 6 months and due to the overextended flanges of the denture. Its treatment includes **conservative** or **surgical**.

The conservative treatment includes:

- 1- Using of tissue conditioning material with shortening & smoothing overextended border.
- 2- Construction of a new denture.
- 3- Massage of the tissue with a piece of gauze.

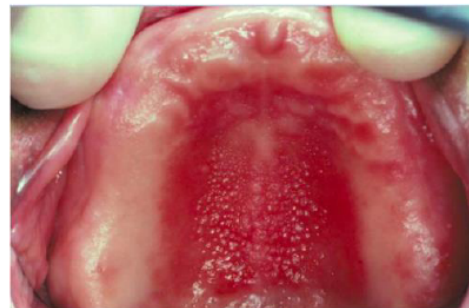

B- Papillary hyperplasia: or nodular hyperplasia appears as multiple nodules in the palate under maxillary denture. **The causes are:**

- 1- Patients having a relief chamber for retention.
- 2- Patient wearing the denture continuously.

The treatment include:

- a- using tissue conditioning material.
- b- Construction of a new denture with relieve of pressure areas on these lesions.



5. Traumatic ulcer Or sore spots, most commonly develop within 1-2 days after insertion of new denture. Appear either as red area (erythema) or with even break of continuity of the epithelium, the associated symptom is slight to sever pain depending on the pain threshold of the patient. **The possible causes are:** a. overextended denture.

- b. When the mucosa is squeezed between spinus bone and denture base (pressure area).
- c. Rough surface of the denture.
- d. Inharmonious occlusion may cause scattered traumatic ulcers.

6. Burning mouth syndrome (BMS) is a chronic, painful condition characterized by burning sensations in tongue, lips, palate (roof of the mouth), gums, inside of the cheeks and the back of the mouth or throat. Oral mucosa appears healthy, feeling of dry mouth with persistent altered taste perception, headache, irritability, depression. Burning mouth syndrome appears to affect women seven times more often than men with a mean age of approximately 60 years. Often appears for the first time in association with the placement of new denture.

The most common sites of the complaint are the tongue and the upper denture bearing tissues. Rather less common are the lips and lower denture-bearing tissues.

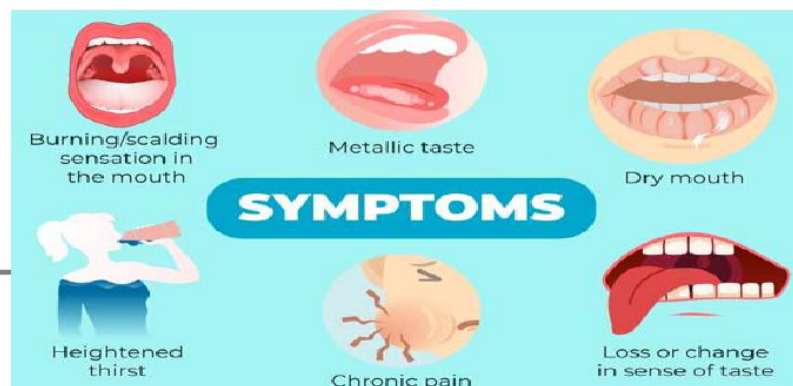
Many of the BMS patients have consulted a number of health care professionals before seeking help from the dentist or dental specialist. They know of no other people with the complaint and therefore feel quite isolated. If several professionals have stated that the mouth looks normal the patient may start to feel as if 'it is all in the mind'. The level of anxiety is consequently raised and cancerphobia may well develop.

Classification Three types of BMS have been described. The classification is useful as it points the way towards appropriate treatment and a probable prognosis.

Type 1 There are no symptoms on waking. A burning sensation then commences and becomes worse as the day progresses. This pattern occurs every day. Approximately 33% of patients fall into this category and are likely to include those with hematinic deficiencies and defects in denture design.

Type 2 Burning is present on waking and persists throughout the day. This pattern occurs every day. About 55% of patients are placed in this category, a high proportion of who have chronic anxiety and are the most difficult to treat successfully.

Type 3 Patients have symptom-free days. Burning occurs in less usual sites such as the floor of the mouth, the throat and the buccal mucosa. This category is made up of the remaining 12% of patients. A study of this group has shown that the main causative factors are allergy and emotional instability. The investigation of these patients is likely to include patch testing.



Aetiology: BMS has been attributed to a multitude of causes and these broadly fall into three groups:

- Local irritants including denture faults
- Systemic factors
- Psychogenic factors.
- Idiopathic: This is when careful investigation fails to reveal an etiology for BMS.

Local irritation:

Denture faults errors in denture design: which causes a denture to move excessively over the mucosa, which increase the functional stress on the mucosa or which interfere with the freedom of movement of the surrounding muscles may initiate a complaint of burning rather than frank soreness. Denture design errors have been discovered in 50% of BMS patients.

Residual monomer: High levels of residual monomer in the denture base have been reported and the tissue damage produced is considered to be the result of chemical irritation rather than a true allergy. It is possible that high levels of residual monomer, which have ranged from three to ten times the normal value, are due to errors inadvertently introduced into the short curing cycles which are popular with manufacturers and dental laboratories. If the requisite curing temperature of 100°C is not achieved in the relevant part of the short curing cycle, there is a marked increase in residual monomer content.

Some authorities may not consider this condition to be an example of BMS where, classically, the mucosa looks normal. However, a patient who reacts to a high level of residual monomer complains of a burning sensation and so we feel justified in including it.

Micro-organisms: The role of micro-organisms in burning mouth syndrome is controversial and studies have not shown a link between presence of *Candida albicans* and the complaint.

Smoking and mouthwashes: Smoking and the regular use of some mouthwashes are irritants that have been implicated in BMS.

Systemic causes:

Nutritional deficiencies: Contributions from nutritional deficiencies such as iron, vitamin B complex and folic acid should be highlighted. An example of BMS caused by a deficiency is Iron deficiencies have been found in 8% and folic acid deficiencies in 6% of BMS patients. Low blood levels of vitamin B1 and B6 were found in 40% of patients.

Endocrine disorders: What is apparent is the relative unimportance of the climacteric as a causative factor, a modern viewpoint which is at variance with past clinical opinion. On rare occasions, the symptoms are found to be linked with an undiagnosed *diabetes mellitus*. Treatment of the medical condition invariably results in complete resolution of BMS. *Xerostomia*, frequently associated with BMS. One that should be highlighted here is drug-induced xerostomia. Recent investigations have produced evidence of a link between BMS and reduced parotid gland function and antidepressant medication reducing the salivary flow. It should be recognized that the presence of a dry mouth is capable of accentuating the symptoms initiated by any of the causes of local irritation. This is an example of the multifactorial nature of BMS.

Hypersensitivity: True hypersensitivity to constituents of denture base polymer is rare and usually results in local symptoms such as burning or itching. In one instance where there were systemic symptoms of nausea, dizziness and general malaise the patient was found to have reacted to dyes used to colour the polymer so dentures made of clear polymer.

Parkinson's disease: It has been reported that the prevalence of BMS was 24% in people suffering from Parkinson's disease;

Psychogenic causes: The more common disorders associated with BMS are anxiety, depression, cancerphobia and hypochondriasis. The associated parafunctional activities such as bruxism and abnormal and excessive tongue movements are capable of inducing mucosal irritation.

Management: Faced with a multitude of causative factors, it will be recognized that the process of diagnosis and treatment is usually a time-consuming affair.

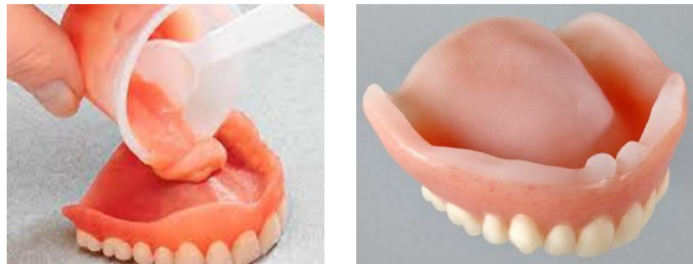- Initial assessment (history/examination/special tests).
- Provisional diagnosis.
- Initial treatment (e.g. elimination of local irritants and investigating and treating hematinic deficiencies).
- Assessment of initial treatment.
- Definitive diagnosis.
- Definitive treatment (local/systemic correction/psychological therapy).
- Follow-up.

7- Hypersensitivity: Very rare, induced by continuous or frequent repeated exposure to an allergic substance. The patient complains from swollen tissue underneath the denture, sometimes accompanied by a metallic taste. This allergic reaction may be early (anaphylactic reaction) or delayed reaction. To diagnose this condition we do the patch test for the skin. The condition is treated by change the denture base material other than methacrylate like (Cr/ Co) base denture.

• **Hard and soft materials for modifying the impression surface of dentures**

Materials which can be used to modify the impression surface to overcome some of these problems; these materials can either be applied by the dentist at the chairside or by the dental technician in the laboratory. The materials may be classified as follows:

- Hard materials
- short-term soft lining materials
- long-term soft lining materials.



• **Hard materials**

Recent years have seen development of a group of useful materials, frequently described as chair side reline materials, can be used to modify impression surface of an existing denture.

Composition: Commonly these materials consist of a powder containing polyethylmethacrylate together with a liquid monomer, butylmethacrylate. The important point to make is that monomeric methylmethacrylate, a tissue irritant, is avoided. Many of the products include a primer to enhance the adhesion of the material to the existing denture polymer. The available materials vary in working time, setting time and viscosity. These materials useful for relining dentures, can be used at chairside a 'one-stop' reline technique.

Clinical applications: This has great benefits in the following situations:

1. A laboratory reline would require the patient to be without any denture for period of time (socially unacceptable to be without denture and in case of immediate denture patient).
2. A reline is required, but it is not necessary for it to last for much longer than a year. The immediate denture patient is likely to fall into this category, as after a year the chairside reline will usually need replacing by a permanent rebase or by a replacement denture.
3. Where a direct technique is indicated (chair side reline).

• Short-term soft lining materials

Most materials are supplied in a powder/liquid form. An alternative presentation is in a ready-to-use sheet form which can be found in one product available to the dental profession and in several 'over the counter' products available directly to the general public. It is essential that traumatized tissue is examined by the dentist and that rational, rather than empirical, treatment is prescribed.

The **composition** of the powder/liquid types is as follows:

- (1) Powder. Polyethylmethacrylate, or copolymers of polyethyl/methylmethacrylate.
- (2) Liquid. A mixture of:
 - (a) an aromatic ester, such as dibutyl phthalate which acts as plasticizer.
 - (b) ethyl alcohol.

Clinical applications

Short-term soft lining materials are placed in existing dentures for the following reasons:

- (1) **Tissue conditioning**. For tissue conditioning, the material is applied for a period of a few days to the impression surface of a denture when the mucosa is traumatised and inflamed. The tissue conditioner acts as a cushion absorbing the occlusal loads, improving their distribution to the supporting tissues and encouraging healing of the inflamed mucosa.
- (2) **Temporary soft reline**. A short-term soft lining material can be used to improve the fit of a denture, typically an immediate restoration.
- (3) **Diagnosis**. A short-term soft lining material can be used as a diagnostic aid where the dentist wishes to check the reaction of the patient and the tissues to an improvement in fit of a denture.
- (4) **Functional impression**. A short-term soft lining material can be used as a functional impression material applied to the impression surface of a denture for the purpose of securing an impression under functional stresses.
- (5) **Recording the neutral zone**. The ability of these materials to be molded by the oral musculature over an extended period of several minutes allows them to be used to record the neutral zone.

•Long-term soft lining materials

Long-term soft lining materials distribute stress more evenly under dentures than do the hard denture base materials. They also absorb impacts that can arise from masticatory function. They can therefore be said to have a shock-absorbing or cushioning effect. As a consequence long-term soft lining improves the ability to bite and chew and provides general improvement in comfort when compared with hard relines.

Indications for use

- (1) Persistent pain under a denture.
- (2) Thin atrophic mucosa.
- (3) Parafunction.

It is important to make two points; first, the problem is almost always found in the lower jaw and, second, it is essential to ensure that all existing denture faults have been eliminated before deciding to proceed with a long-term soft lining.

- (4) Replacing an existing denture which has a soft lining. Once a patient has successfully worn a lower denture with a soft lining and has got used to its 'feel' it is often wise to repeat the prescription. If this is not done and the new denture is made with a hard base.
- (5) Sharp bony ridges or spicules. The problem might be overcome, at least in the short term, by surgically smoothing the bone. However, there are often occasions where poor health or a strong preference by the patient to avoid surgery are contraindications to this approach. There is also the danger that surgical interference with the mandible will speed up resorption of the bone. An alternative, conservative approach is to provide a soft lining.
- (6) Superficially placed mental nerve. In advanced resorption of the mandible the nerve is traumatised during function. This typically gives rise to a complaint of a severe, sharp, stabbing pain from the area of the mental foramen which is brought on by biting. A soft lining restricted to the problem area may provide relief. If this is the case it may be necessary to cut the denture away in the area of the nerve to eliminate pressure on the nerve altogether.

Types of long-term soft lining: Soft linings are made either of silicone rubber or soft acrylic. The silicone materials may be cold-curing or heat-curing. Soft acrylics are heat-curing; cold-curing soft acrylics have a very limited life span and are best used as temporary soft linings.

• Lack of saliva**Functions of saliva in the edentulous patient:**

- **Denture retention** – saliva is an essential in physical retention of complete dentures.
- **Lubrication** – the glycoproteins in saliva facilitate movement of the soft tissues during speech, mastication and the swallowing of food.
- **Cleansing** – saliva physically washes food and other debris from the soft tissues and from the polished surfaces of prostheses
- **Taste** – flavours are perceived only when substances are in solution in saliva or other fluids. It prepares food for swallowing and facilitates the sense of taste
- **Digestion** – digestion during mastication, salivary amylase starts to breakdown glucose.
- **Antimicrobial** – there are antimicrobial components, such as antibodies, in saliva which help to maintain a normal balance of the oral flora.

Problems of reduced salivary flow

A reduction, or absence of saliva (xerostomia), is likely to cause problems with all the functions listed above so that a general, and significant, reduction in the quality of life results. Reduced retention of dentures is a particular problem for edentulous patients. There may also be an increased susceptibility to denture trauma resulting in complaints of pain and in some case the burning mouth syndrome.

Aetiology of reduced salivary flow

Medical History: A full history is taken including a 'I'm taking an antidepressant and question on current medication a diuretic 'For how long have you been 'One year' DRY MOUTH is a possible taking these tablets?' contributory factor to the oral complaint.

Social History: The history has revealed a number of possible causes of the persistent pain. The diagnosis can be established only after a careful examination of the patient, the mouth and the various sets of dentures in order to confirm or deny the various possibilities. The point should be made that unless a full history is obtained some of the possible causes might never be revealed. The provision of new dentures would do little to eliminate the problem if the persistent pain was due to a dry mouth and to parafunction. However, the condition is relatively common in middle-aged and older people, the main candidates for complete dentures, with between 12% and 16% complaining of a dry mouth.

The commonest causes of dry mouth (Niedermeier et al. 2000; Field et al. 2001) are:

- Adverse effects of drug therapy, e.g. tricyclic antidepressants, beta-blockers
- Depression and chronic anxiety
- Dehydration & Mouth breathing
- Salivary gland inflammation and fibrosis
- Auto-immune disease like Sjögren's syndrome
- Head and neck radiotherapy
- Poorly controlled diabetes
- Smoking.

* A complaint of dry mouth can occur in the absence of the clinical signs of dryness ('symptomatic xerostomia'). Under such circumstances the physical retention of the dentures would not be expected to be diminished.

Symptoms & Management of dry mouth

In clinical xerostomia there are intra-oral signs of dryness such as a dry, atrophic mucosa and lack of saliva pooling in the floor of the mouth. The dentist can check the dryness of the buccal mucosa simply and quickly during the examination of the patient by carrying out the 'mirror test'. For this the dentist lightly presses the face of the mirror against the buccal mucosa and then tries to remove it. If the mirror comes away easily the mucosa is still covered by a substantial film of saliva; if the mucosa adheres to the mirror then it is dry.

Close collaboration with the patient's general medical practitioner or with a specialist in oral medicine is often necessary. It might be possible, for example, to change an existing xerostomic drug to one less liable to reduce salivary flow. As there is a definite relationship between fluid intake and secretory performance it is essential that the patient is kept well hydrated.

Chewing and energetic exercise improve salivary flow, possibly because of improved blood circulation to the glands. In cases where flow rate cannot be improved limited relief may sometimes be obtained by the use of artificial saliva.

Measures for managing xerostomia (may be local or systemic):

Local measures:

1. **Artificial saliva.** In cases where the salivary flow rate cannot be improved limited relief may sometimes be obtained by the use of artificial saliva.
2. **Denture and oral hygiene.** It is very important for a denture patient with a dry mouth to maintain an excellent level of denture hygiene. The likelihood of the proliferation of *Candida albicans* and other microorganisms is increased in xerostomia and therefore unless denture hygiene is maintained at a high level the denture is likely to be rapidly colonised by the micro-organism, resulting in denture stomatitis. Motivation and instruction of the patient, followed by monitoring the quality of denture hygiene are essential.
3. **Denture adhesive.** Dry mouth gives rise to a persistent problem of loose dentures a denture adhesive will usually provide some improvement in denture function.

Systemic measures:

1. **Treatment of an underlying disease.** It might be possible, for example, to change an existing xerostomic drug to one less liable to reduce salivary flow. Also if the patient is diabetic, an improved glycaemic control will alleviate the xerostomia.
2. **Increasing fluid intake.** As there is a relationship between fluid intake and secretory performance, it is essential that the patient is kept well hydrated.
3. **Sialogogues.** *Pilocarpine* can stimulate salivary flow where some functional salivary tissue remains, particularly in drug-related xerostomia, but it commonly has unpleasant side effects such as increased sweating. The dry mouth may also be occasionally alleviated by sialogogues such as sugar-free chewing gum, glycerine or sorbic acid and lemon mouthwash.

Cleaning dentures it should be done for **deposits form on dentures** such as:

- Microbial plaque
- Calculus
- Food debris.

These deposits may be responsible for a variety of problems including:

- Denture stomatitis
- Angular stomatitis
- Unpleasant tastes
- Odours
- Unsightly appearance
- Accelerated deterioration of some denture materials such as short-term soft lining materials.
- Inflammatory Papillary Hyperplasia, Candidiasis and Wearing illfitting dentures 24h/7 days, are contributing factors. Resolve before making new dentures because, if left as it, new dentures will be loose after placement, as inflammation resolves. Treatment by:
 - a. Leave dentures out at night.
 - b. Reline with tissue conditioner.
 - c. Nystatin mouth rinse

* The effective cleaning of dentures is therefore of considerable importance to the patient's general well-being and oral health.

- **Denture breakages**

Midline fracture of the complete upper denture accounts for 29% of all repair work in dental laboratories, while teeth debonded from complete dentures account for 33%. These two common problems will be considered.

Types of fracture:

- **Fatigue of the acrylic resin:** Fatigue fracture results from repeated flexing of the denture by forces too small to fracture it directly. Failure of the denture base is due to the progressive growth of a crack originating from a point on the surface where an abrupt change in the surface profile causes a localized concentration of stress many times that applied to the bulk of the denture. The crack often starts palatally to the upper central incisors, grows slowly at first but undergoes an enormously increased rate of growth just before the denture fractures. A failure of this type most commonly occurs in dentures that are about 3 years old. Midline fracture due to fatigue of the acrylic resin is the commonest type of denture breakage.

- **Impact:** Denture breakage might occur, for example, if the patient accidentally drops the denture while cleaning it. It might also result from an accident in which the patient receives a blow to the mouth.

Whenever possible, the cause, or causes, of the fracture must be identified before the denture is repaired or replaced. Unless this is done and the cause attended to, the denture is likely to fracture again within a short period of time.

Causes of fracture:

A. Denture factors

- Stress concentrators.
- Absence of a labial flange.
- Incomplete polymerisation of the acrylic resin.
- Previous repair.
- Shape of the teeth on the denture.
- Poor fit.
- Lack of adequate relief.

B. Patient factors:

- *Anatomical factors:* a prominent labial frenum will require a deep notch in the flange resulting in stress concentration in that area.
- *High occlusal loads:* These may occur in patients with powerful muscles of mastication, or whose natural lower teeth are still present, or who are bruxists.

• **Debonding of teeth**

The usual reasons for a weak bond between tooth and denture base are:

- The presence of tin-foil substitute on the ridge-lap surface of the tooth
- The presence of residual wax on the same surface
- The use of cross-linked teeth which are incompatible with particular denture base polymer.

Of the various recommendations that have been made for minimising the risk of debonding the following have received fairly widespread support:

- (1) Choose artificial teeth and denture base polymer which are compatible by checking sheets provided with the products or by seeking information from manufacturers. Conventional denture teeth tend to achieve higher bond strength than cross-linked teeth (porcelain).
- (2) Ensure all traces of wax and tin-foil substitute are removed. The complete removal of wax not achieved with boiling water alone, but also the use of a wax solvent is recommended.
- (3) Drill small channels into the palatal surface of the teeth to increase the area available for the polymerizing denture base resin. However, such recesses in the ridge-lap surface of the teeth make complete wax removal more difficult. Therefore care needs to be taken when removing wax; otherwise the adjustments can result in a weaker, rather than a stronger bond.
- (4) Apply a solvent such as dichloromethane to the ridge-lap surface of teeth. Solvent creates microscopic pores and channels which promote diffusion of the polymerisable materials.
- (5) Use a heat-curing denture base polymer. This material polymerises more slowly than a cold-curing material and ensures better penetration into the tooth substance.

• **Gagging reflex (retching)**

Is a protective reflex which guards the airway and posterior oropharynx. It may occur during prosthetic procedures such as impression taking, or when dentures are worn or, in extreme cases, when a mouth mirror is placed on the lips or tip of the tongue.

Aetiology: There are a number of causes that may be conveniently grouped together as follows.

- (1) **Somatic.** The term 'somatic' covers those situations where the reflex is triggered by tactile stimulation of the soft palate, posterior third of the tongue.
- (2) **Iatrogenic.** Iatrogenic causes, which are related to the dentures, are numerous. Some patients begin to retch after new dentures are inserted, but in most cases this reflex soon disappears as they adapt to the dentures. However, the reflex may persist if there are faults with the dentures such as an excessive occlusal vertical dimension, or if the dentures are stimulating the sensitive areas of the soft palate and tongue directly. This stimulation may be caused by palatal over-extension, a posterior border which is too thick or poorly adapted, the teeth encroaching on tongue space or indeed by any factor producing denture instability.

An upper denture whose posterior border is under-extended posteriorly can provoke gagging because as the edge of the denture terminates on relatively incompressible mucosa a satisfactory post-dam cannot be produced. This results in poor retention, which increases denture instability, stimulates the tongue and palate, and causes apprehension in the patient. When this diagnosis is established, it requires a very careful explanation by the dentist to convince the patient that to cure the problem it will be necessary to cover more, rather than less of the palate.

(3) **Psychogenic.** Psychogenic causes may arise from sight, sound or thought. They include the sight of impression material being mixed or the sound of another patient retching. The patient may be extremely apprehensive because of an unhappy first experience of dental procedures or as a result of disturbing stories from friends. In rare instances, retching may be a manifestation of a psychological disturbance which is not primarily related to the patient's dental treatment.

(4) **Systemic.** Less frequently, the causative factor may be systemic disease, particularly conditions affecting other regions of the gastrointestinal tract; for example, the link between retching and alcoholism may be related to the persistent gastritis found in such patients. Persistent catarrh will prevent nose breathing and may contribute to the problem of retching.

Patient management:

- **Assessment of the severity of the problem:** A carefully taken history will reveal the severity of the problem and provide clues as to the cause. For example, a situation where a patient has been able to tolerate the clinical stages of denture construction, but then has difficulty in wearing the finished dentures, points to an iatrogenic cause which should be treated relatively simply by correcting the error in denture design.

- **Impressions:** Most of individuals find impression taking unpleasant. However, retching during impression taking can usually be prevented by the following:

(1) **Reassurance and relaxation.** It is very important that the dentist has a confident and relaxed chairside manner. It is essential that the anxious patient is reassured and encouraged to relax both physically and mentally. The dental nurse can also play a major role in creating an appropriate state of mind in the patient.

(2) **Position of the patient.** The dental chair should be adjusted so that the patient is sitting comfortably in the upright position.

(3) **Breathing through the nose.** Instructing the patient to breathe through the nose while the tray is being tried in the mouth or the impression is being taken is one of the most helpful methods of preventing retching. During nasal breathing the soft palate remains stationary in its low position and the tongue in its 'guarding' position, protecting the nasopharynx from the threat of the foreign body in the mouth. If the patient breathes through the mouth, this protection is lost and movement of the soft palate results in intermittent contact with the setting impression material, increasing stimulation.

(4) **Impression technique.** Impression trays should be well fitting. As close-fitting special trays are less bulky than spaced trays, they are better tolerated and should be used whenever possible. When trying trays in the mouth, firm, positive movements should be used. Most patients tolerate the lower impression better than the upper one, so if the lower impression is taken first, the success of the procedure is likely to reassure the patient. The impression material should be mixed or prepared out of sight of the patient and the amount placed in the tray kept to the minimum necessary to record the relevant structures. A saliva ejector should be used if copious amounts of saliva collect in the floor of the mouth.

(5) **Distraction.** It is during the insertion of the impression and while the material is setting that it is particularly important to distract the patient's attention from what is going on. This may be achieved by the dentist talking about something that is known to be of particular interest to the patient, or by reinforcing the requirement that the patient continues to breathe slowly and steadily through the nose. It has even been suggested that the patient be asked to raise one leg and to concentrate on not lowering it until the impression has set!

The severe gagging reflex

The **first** challenge when trying to treat a patient who has this problem is to obtain an accurate impression so that a well-fitting denture base can be constructed.

The **second** challenge is to provide a prosthesis worn by the patient for a reasonable time.

The following approaches to management of this difficult problem have been found useful:

(1) **Conscious sedation**

(2) **Acupuncture.** The gag reflex has been shown to be capable of being controlled by acupuncture. Although there is evidence to show that the technique is of assistance when undertaking the various clinical stages of denture construction there is, as yet, no evidence that it can be used by the patient to allow the denture to be worn.

- (3) **Hypnosis.** Hypnosis has been used in the treatment of severe cases its success is dependent upon the patient being well motivated and being able to practice self-hypnosis, thus enabling a denture to be worn outside the dental surgery
- (4) The **training denture.** The training denture approach may be of value when treating any patient with a long history of difficulties which suggest frank denture intolerance, including retching.

• Disturbance of speech

The presence of complete dentures can modify speech by affecting articulation and by altering the degree of oral resonance. A number of sounds are articulated by contact of the tongue to the palate and to the teeth. A change in speech that may be quite marked when the dentures are first inserted will usually disappear completely within a few days. However, if the changes in the contact surfaces require a modification of tongue behaviour that is beyond the adaptive capability of an individual patient, a speech defect will persist. It should also be remembered that the tongue of a patient who is wearing complete dentures has a dual function – to take part in speech articulation and to control the dentures. If the dentures are loose, the demands of this latter function may be so great that there is a general deterioration in the quality of speech.

The following relationships are particularly important to the production of clear speech.

(1) Tip of the tongue to the palate. Contact between the tip of the tongue and the palate is required in the production of /s/, /z/, /t/, /d/ and /n/. Consequently, a change in the shape or thickness of the denture contact surface resulting from the fitting of new dentures will require a modification of tongue behaviour in order to produce sounds which are the same as before. In the vast majority of cases, the necessary modification occurs without any difficulty in a relatively short period of time.

The sound most commonly affected in this way is /s/, a sound which is generally produced with the tongue tip behind the upper anterior teeth. A narrow channel remains in the center of the palate through which air hisses. If the palate is too thick at this point, or if the incisors are positioned too far palatally, the /s/ may become a /th/. If the denture is shaped so that it is difficult for the tongue to adapt itself closely to the palate, a channel narrow enough to produce the /s/ sound will not be produced and a whistle or /sh/ sound may result. This is most likely to be the consequence of excessive palatal thickening laterally in the canine region.

(2) Lower lip to incisal edges of upper anterior teeth. The lower lip makes contact with the incisal edges of the upper anterior teeth when the sounds /f/ and /v/ are produced. If the position of these teeth on a replacement denture is dramatically different to that on the old denture there is likely to be a disturbance in speech.

(3) Lateral margin of the tongue to posterior teeth. Contact between the lateral margins of the tongue and the posterior teeth is necessary to produce the English consonants /th/, /t/, /d/, /n/, /s/, /z/, /sh/, /zh/ (as in measure), /ch/, /j/ and /r/ (as in red). Air is directed forwards over the dorsum of the tongue and may be modified by movement of the tongue against the teeth or anterior slope of the palate to produce the final sound. If the contact can only be achieved with difficulty, movement of the tip of the tongue may be restricted with consequent impairment of speech. This difficulty arises if the posterior contact surfaces are too far from the resting position of the tongue as a result of the occlusal plane being too high, the occlusal vertical dimension too great or the posterior teeth placed too far buccally.

In extreme cases, it may not be possible for the tongue to produce a complete lateral seal and so a lateral sigmatism develops.

(4) The relationship of mandible to maxilla. The mandible moves closest to the maxilla during speech when the sounds /s/, /z/, /ch/ and /j/ are made. Normally, at this time, there will be a small space between the occlusal surfaces of the teeth. However, if the occlusal vertical dimension of the dentures is too great, the teeth may actually come into contact so that the patient complains that the teeth clatter.

- 1: maxillary alveolar ridge
- 2: buccal mucosa
- 3: tongue margin
- 4: mandibular alveolar ridge
- 5: hard palate
- 6: floor of mouth

s/-, anterior /r/
sounds

retroflex, palatal
sounds

Location	Structures	Consonants
1 labial	upper lip- lower lip	b/m/p
2 labio-dental	upper tip – maxillary incisors	f/v/w
3 linguo-dental	tip og tongue – maxillary incisors	s
4 alveolar	tip of tongue – maxillary alveolar ridge	d/t; r (anterior)
5 retroflexal	tip of tongue to dorsal	r (dorsal)
6 palatal	back of tongue – hard and soft palate	j/g/k/r/ch

