

## *Anatomical landmarks (anterior teeth)*

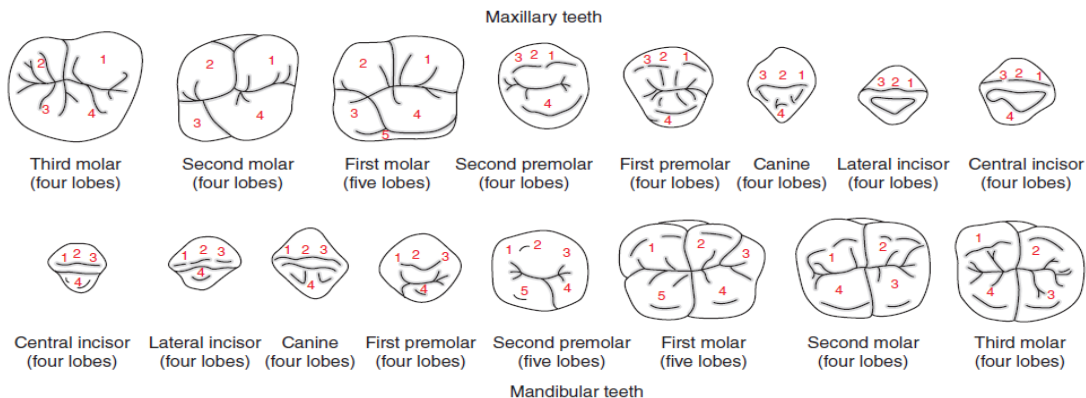
Landmarks mean Elevations, depressions, and grooves are present on the surfaces of teeth, and different terminologies are used to describe these landmarks.

To study an individual tooth intelligently, we must be able to recognize all landmarks of importance by name. These include

- **Concave:** A curvature that leans inward
- **Convex:** A curvature that extends outward. The opposite of concave.

### Anatomical Landmarks on the Crown Surface:

1. **Lobe:** The developmental lobe is the growth center in the development of the tooth's crown.
  - ❖ Each tooth begins to develop from four or more growth centers
  - ❖ These centers, known as developmental lobes, unite to form the crown of the tooth.
  - ❖ Cusps and mamelons are representative of lobes.



**Figure 9.16** Developmental lobes.

2. **Mamelons**: are the protrusions seen in the incisal ridges of newly erupted permanent incisor teeth.

✚ They represent the three lobes from which the labial surface forms, and developmental grooves separate them.

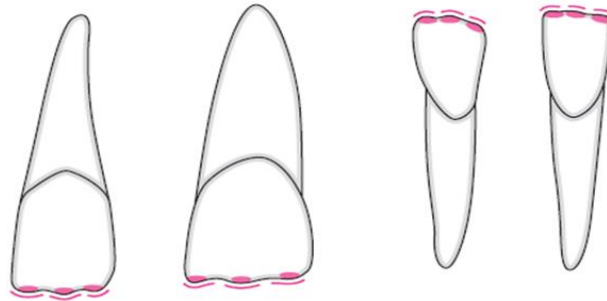


Figure 9.17 Mamelons in the anterior teeth.

### 3. **Cingulum** (Latin word for girdle)

- It is the lingual lobe of an anterior tooth.
- It makes up the bulk of the cervical third of the lingual surface (a prominence of enamel).
- Its convexity mesiodistally resembles a girdle encircling the lingual surface at the cervical third

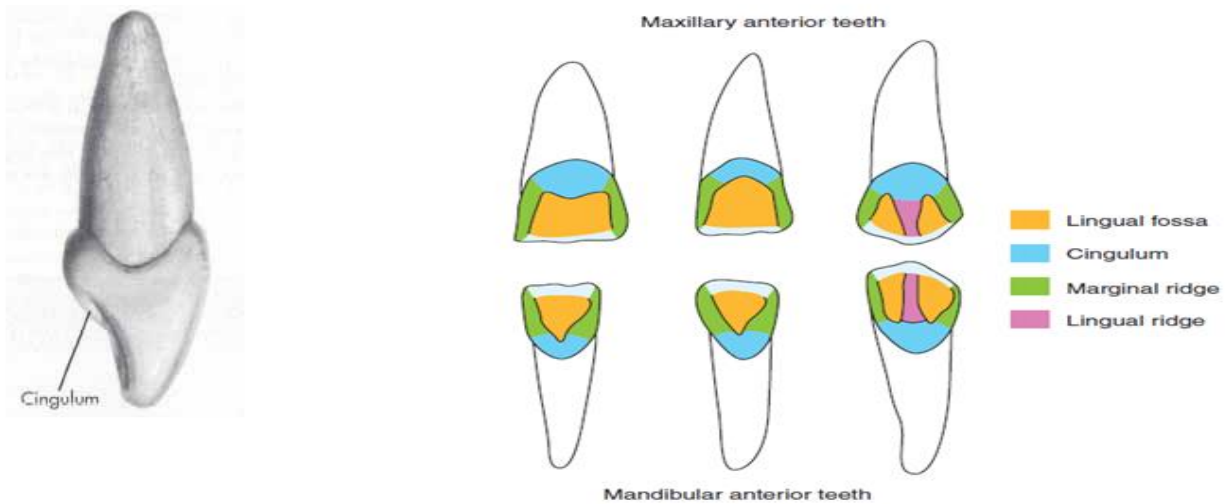


Figure 9.15 Lingual aspect of the anterior teeth.

#### 4. **Tubercle:**

- It is a small, rounded prominence on the surface of a tooth resulting from the extra formation of enamel.

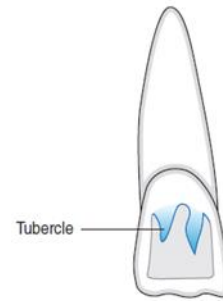
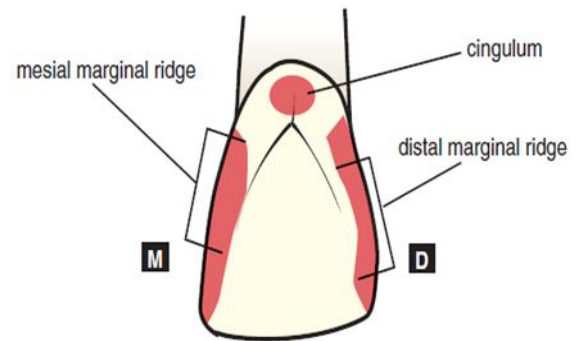


Figure 9.14 Permanent maxillary lateral incisor with tubercles.

#### 5. **Ridge:**

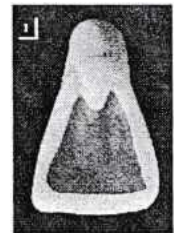
Ridges are any linear, flat elevations on teeth, and they are named according to their location or form.

**Marginal ridges:** these are rounded borders of the enamel that form the mesial and distal margins of the lingual surfaces of the incisors and canines.



6. **Fossa:** it is an irregular depression or concavity.

**Lingual fossa:** it is located on the lingual surface of anterior teeth.



7. **Pits:** often occur at the depth of a fossa where two or more grooves join

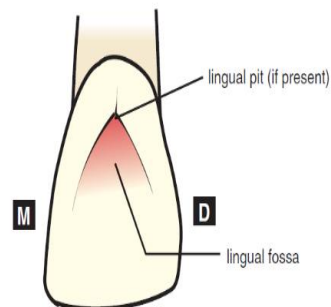


FIGURE 1-30. The lingual surface of an incisor shows the shallow lingual fossa and an adjacent lingual pit.

## Maxillary central incisor

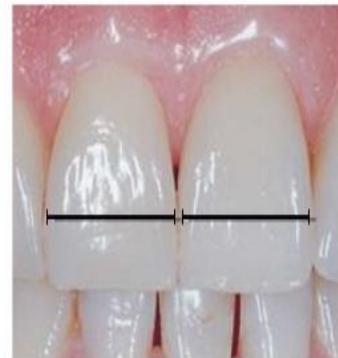The maxillary central incisor, or first incisor, is the first tooth in the maxilla to the right or left of the median line.

The crown length is as great as, or greater than, any of the other anterior teeth excepting the mandibular canine, and its mesiodistal width is greater at the cervix and contact areas than in any other anterior tooth.

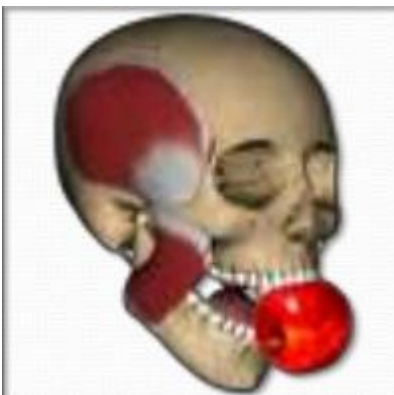The maxillary central incisor is the most prominent tooth and therefore the most noticeable in the dental arches. In general, they are 2 in number.

### Function:

- 1- Biting, cutting, tearing
- 2- Esthetic
- 3- Phonetic

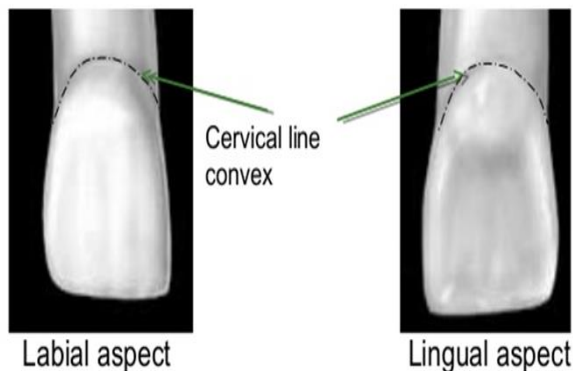
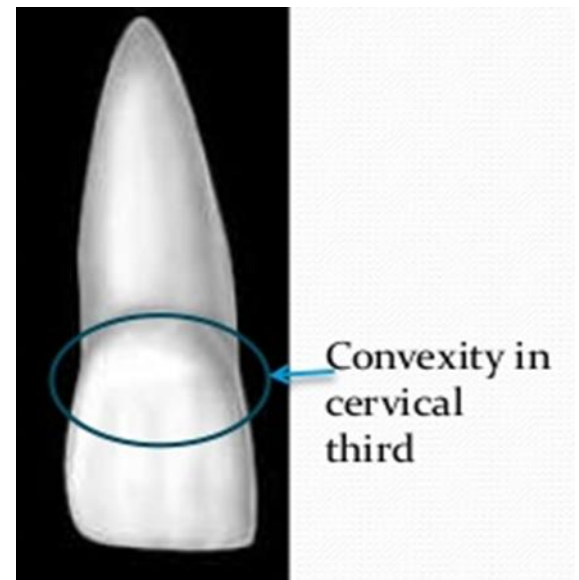
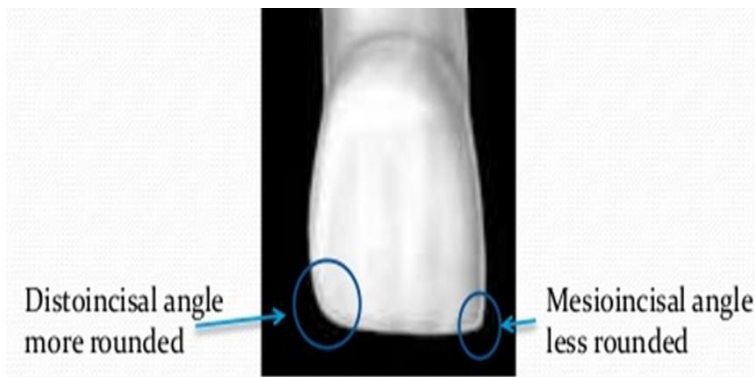


Widest anterior teeth



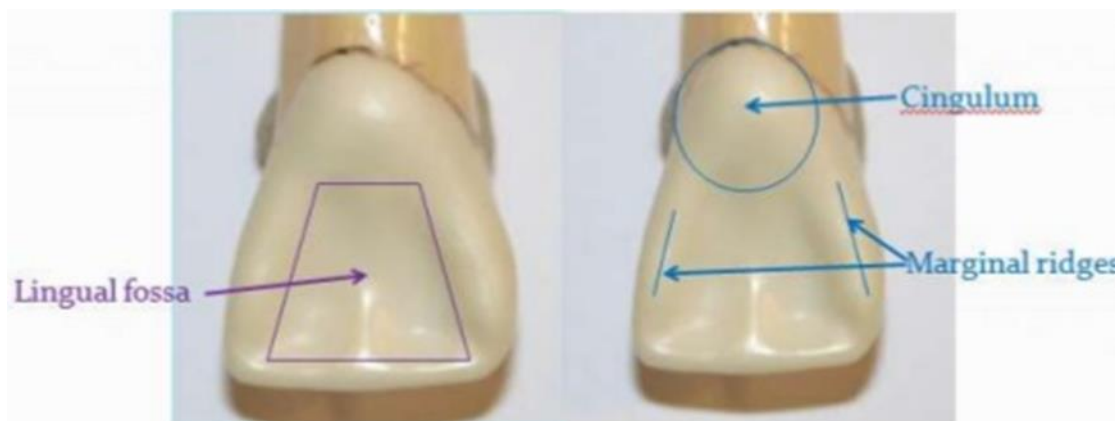
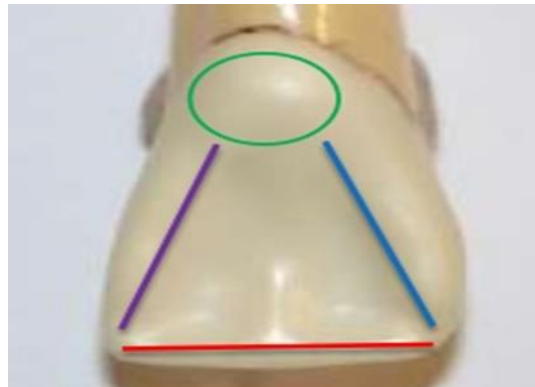
### Labial Aspect: -

- 1- The cervical third of the crown is semi-circular in outline.
- 2- Its square crown appearance.
- 3- The mesio-incisal angle of this incisor approaches a right angle in the outline.
- 4- Contact area with the other central incisor near the incisor edge.
- 5- The disto-incisal angle is much more rounded than the mesio-incisal angle.
- 6- The incisor edge outline is usually regular and straight.
- 7- The root is a conical shape with a blunt or curvature apex.
- 8- The length of the root is longer than the crown from 2---3 mm.
- 9- Smooth and convex labial aspect.
- 10-The labial aspect is slightly divided by two shallow vertical developmental grooves



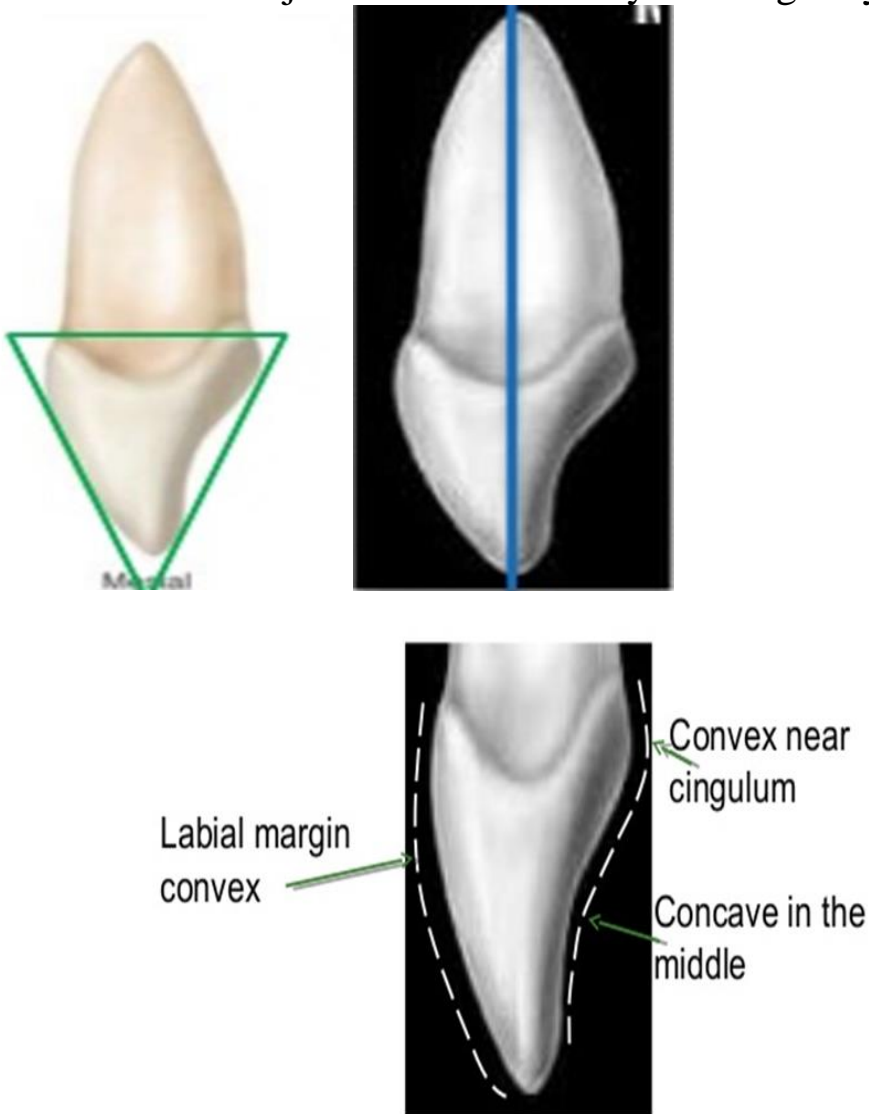
## Lingual Aspect: -

- 1- There is a small convexity below the cervical line to form the cingulum.
- 2- Distally and mesially confluent with the cingulum to form a marginal ridge.
- 3- Between the marginal ridge directly below the cingulum there is shallow concavity called lingual fossa.
- 4- The lingual incisal edge is raised with a level of marginal ridge mesially and distally.
- 5- There is a development groove extending from the cingulum into the lingual fossa.
- 6- The crown and the root tapered lingually making the lingual surface narrower than the labial surface.



## Mesial Aspect

- 1- The crown is wedge-shaped or triangular.
- 2- The labial outline from the crest of curvature to the incisal edge is slightly convex.
- 3- The lingual outline is convex at the crest of curvature at the cingulum then it becomes concave at the mesial marginal ridge.
- 4- The curvature of the cervical line on the mesial surface curves toward the incisal edge about one-third the length of the crown.
- 5- The mesial surface is longer than the distal surface.
- 6- The root may be outlined as a blunt cone from the points at which the crown joins the root labially and lingually to the apex.



## Distal Aspect

The distal aspect has a practically similar outline to that of the mesial aspect there is one important difference the cervical curvature of the cemento-enamel junction is less in extent than that on the mesial surface.



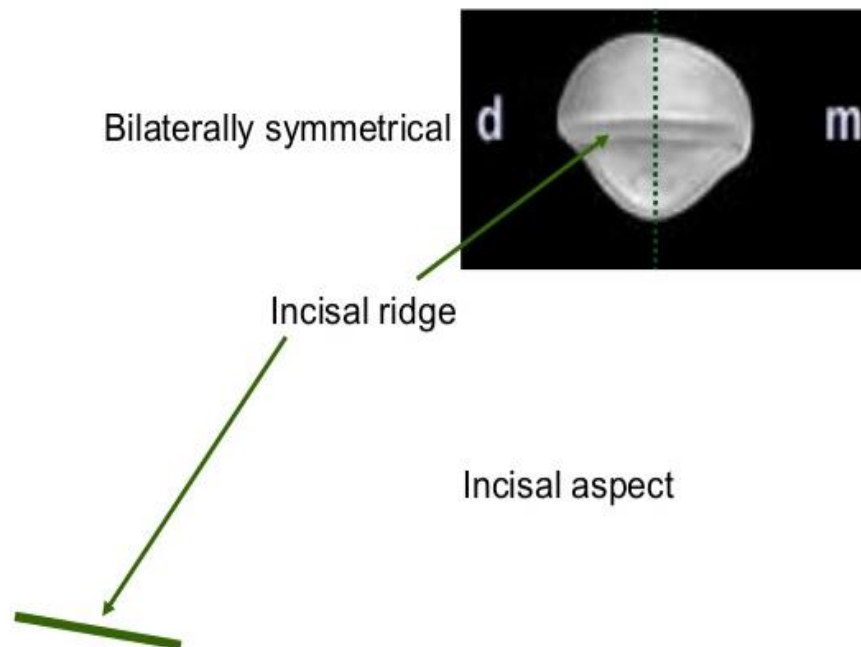
Distal

## Incisal Aspect:

1-Labial portion of the crown is broad and flat in comparison with the lingual portion.

2-outline of the lingual portion is tapered lingually toward the cingulum.

3- The cingulum of the crown makes up the cervical portion of the lingual surface.



**THANK YOU**