



جامعة المستقبل
قسم تقنيات البصريات

مشاكل العين بالامراض الباطنية و العصبية

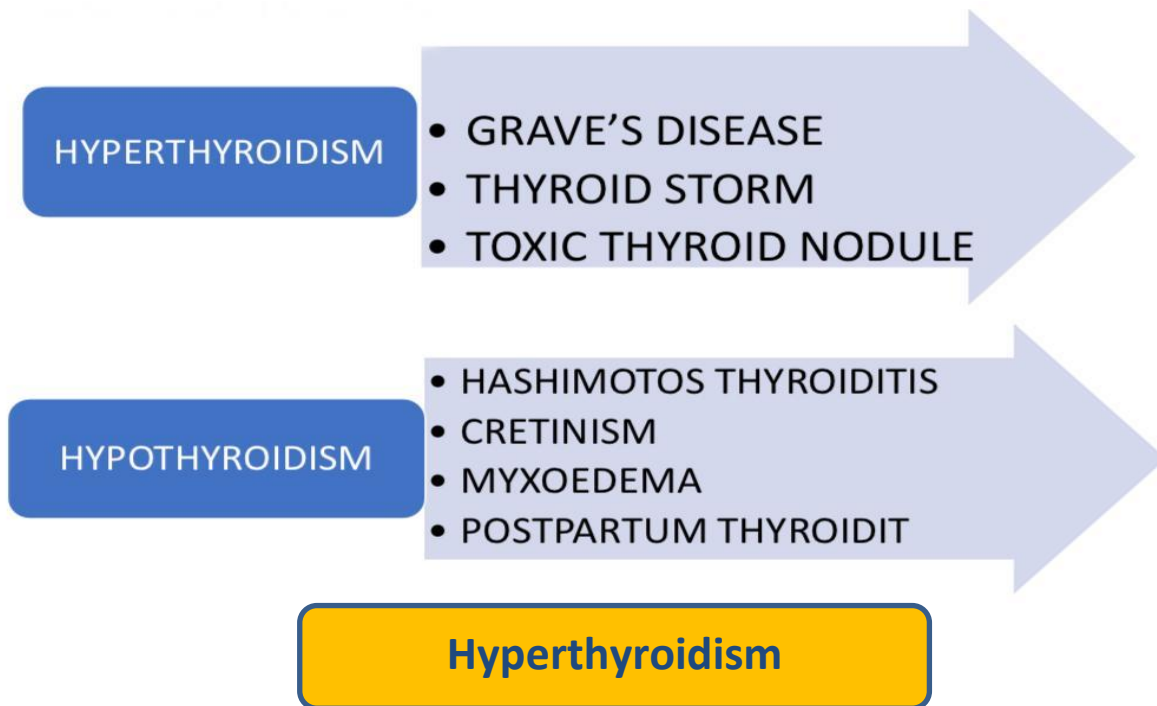
L10

Ocular manifestation in thyroid disorders

د. نيلوفر علي عوض

- THYROID DISORDERS:

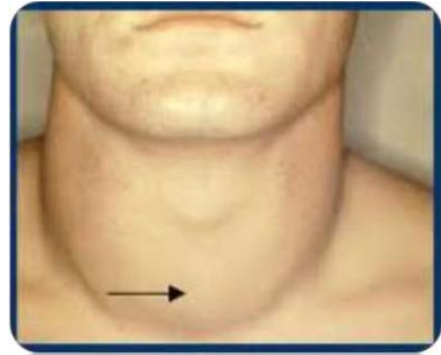
- Smokers 7x
- 30-50 Years:



- (hyperthyroidism) is a condition involving excessive secretion of thyroid hormones (T3 & T4).
- **Graves' disease:** the most common form of hyperthyroidism. Only Graves' disease has eye abnormalities.
- It is more common in females.
 - **Causes:** Autoimmune disease.

- Signs and symptoms

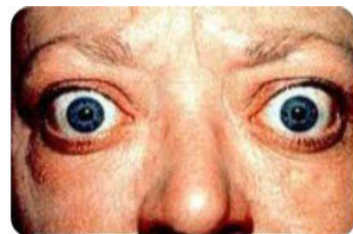- Weight loss
- Diarrhea
- Sweating
- Heat intolerance,
- Nervousness
- Palpitations,
- May be enlargement of the thyroid gland,
- Tremor
- Increased reflexes

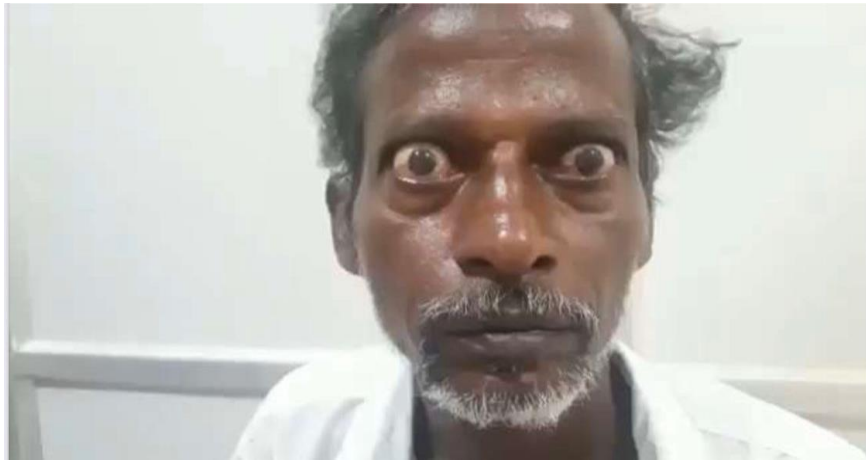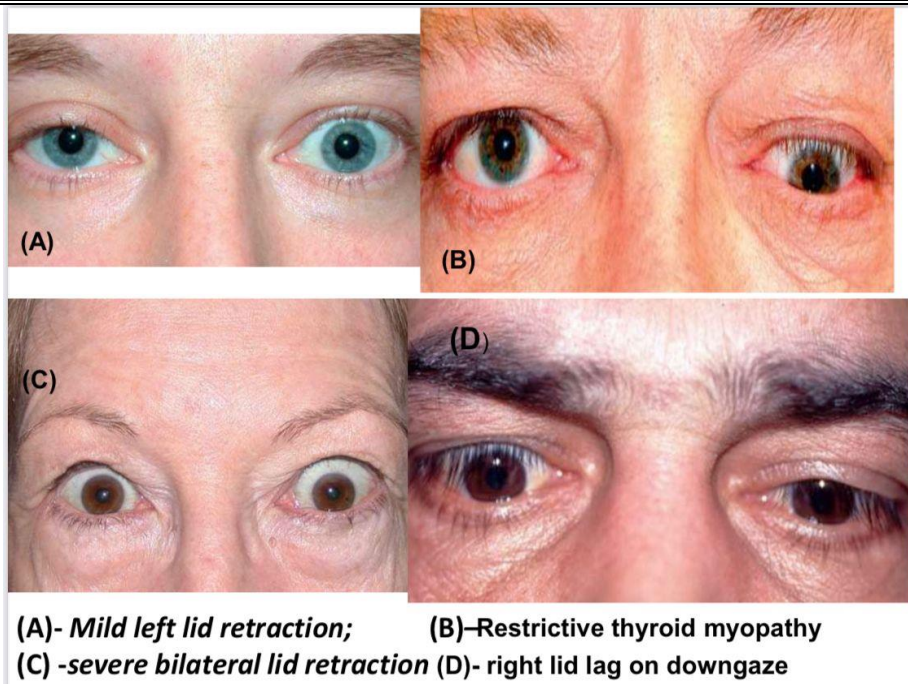


- Eye signs

- Eyes are red and painful lacrimation
- Lid lag.
- Proptosis.
- Optic neuropathy.
- Restrictive myopathy.
- Decreased frequency of blinking.
- Lid retraction exposing the upper sclera.
- Diplopia Proptosis in thyroid eye disease.

Proptosis in thyroid eye disease.





- Investigations

- T3 (triiodothyronine) & thyroxine (T4) levels. Have an elevated T4 level.
- Thyroid stimulating hormone (TSH)-Low
- Thyroid uptake of radio iodine.
- Presence of antibodies: TSH receptor antibody
- CT orbits
- Thyroid scans.

- Treatment

- Propranolol
- Anti-thyroid drugs – Carbimazole
- Radio iodine (Graves' disease)
- Surgery

- Graves Ophthalmopathy

- Steroids are the best, radiation in those not responding to steroids, severe cases may need surgery.