



جامعة المستقبل
قسم تقنيات البصريات

مشاكل العين بالامراض الباطنية و العصبية

Ocular manifestation of hypertension

L8

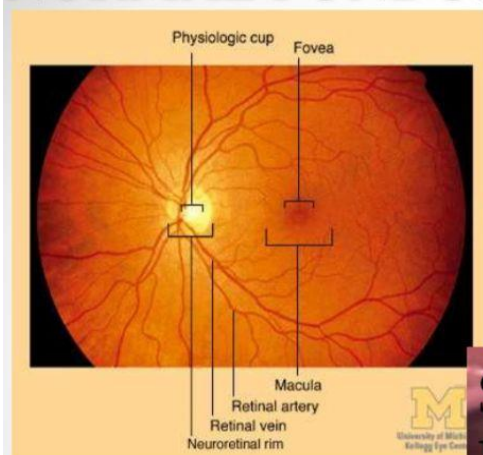
د. نيلوفر علي عوض

Ocular manifestation of hypertension

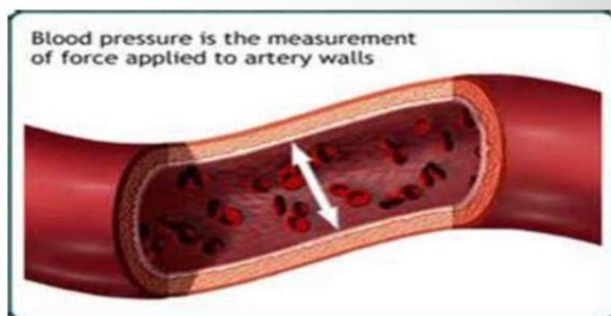
EFFECT ON EYE

- ❖ Hypertensive retinopathy
- ❖ Hypertensive choroidopathy
- ❖ Hypertensive optic neuropathy
- ❖ Subconjunctival haemorrhage in older individuals is prevalent, and blood pressure should be checked.
- ❖ Glaucoma

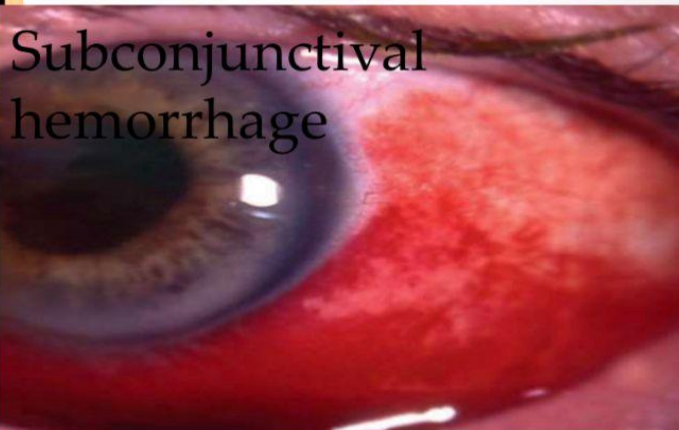NORMAL FUNDUS



HYPERTENSIVE RETINOPATHY



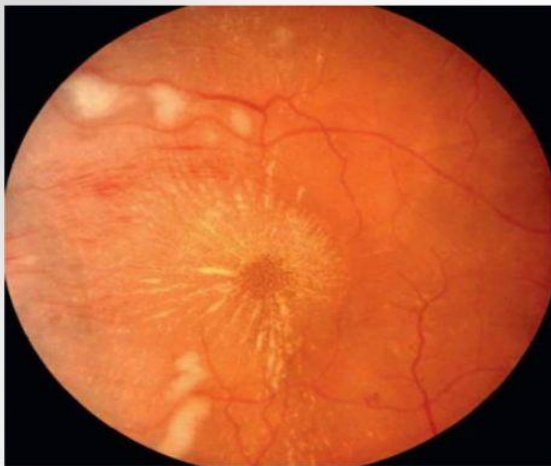Subconjunctival hemorrhage



FUNDUS CHANGES

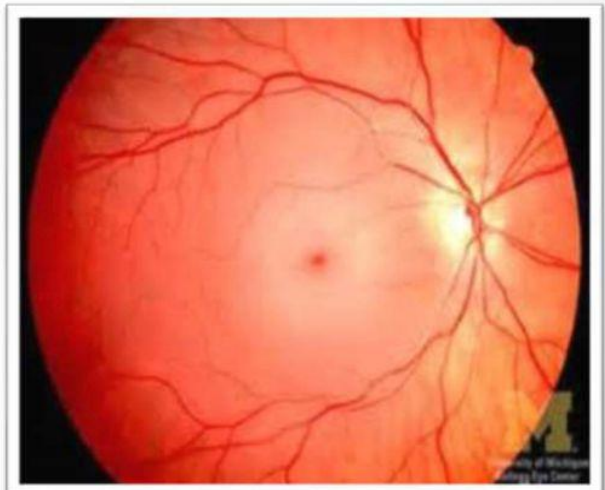
Prolonged systemic hypertension results in retinal vascular effects:

- ❖ Vessel narrowing
- ❖ Arterio venous crossings
- ❖ Microaneurysms
- ❖ Hemorrhages
- ❖ Cotton-wool spots
- ❖ Macular star
- ❖ Papilledema

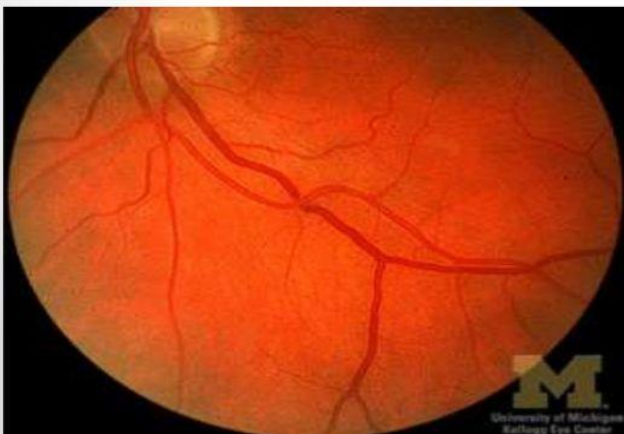

macular star

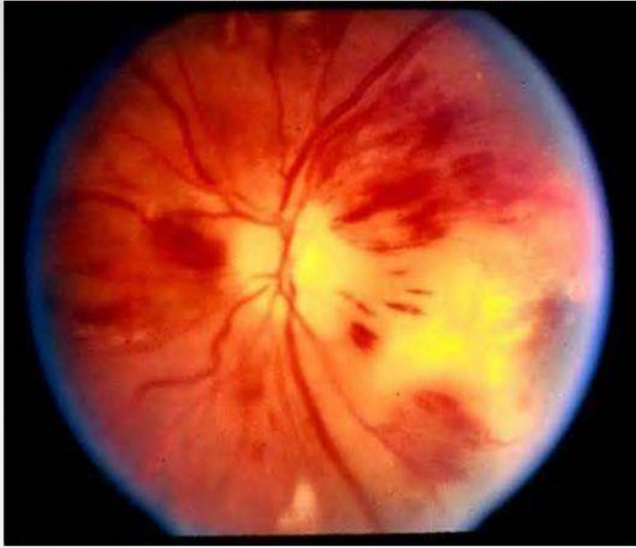VESSEL NARROWING



ARTERIO VENOUS CROSSINGS

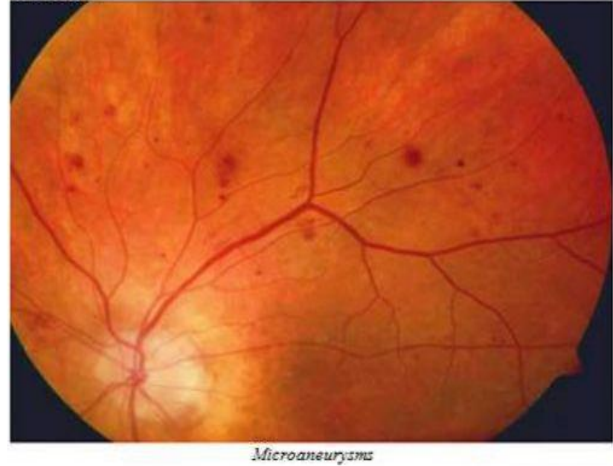


HEMMORRHAGES

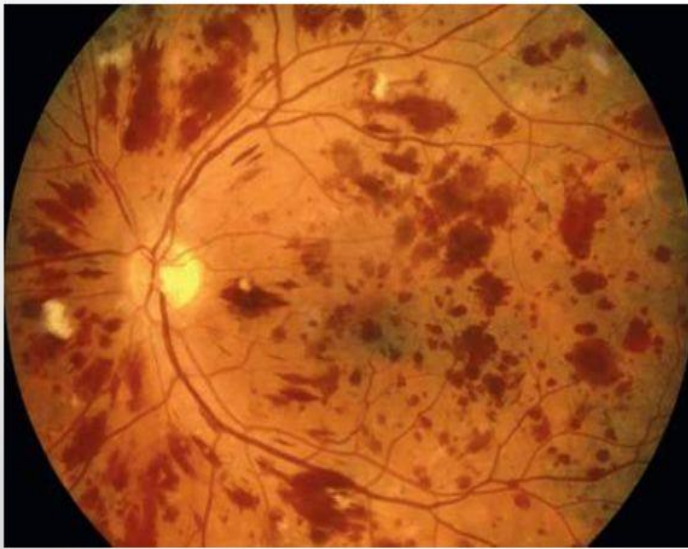

MICROANEURYSMS

FIGURE 2



Microaneurysms



cotton wool spots

HYPERTENSIVE CHOROIDOPATHY

- It's a rare.
- Choroidal vascular bed shows impaired circulation & extensive occlusive & ischemic changes.
- HYPERTENSIVE OPTIC NEUROPATHY(HTON)
- Optic disc edema has been described as an essential manifestation of malignant HTN.
- Optic disc edema is the initial manifestation of HTON.