

**Lecture# 2**

**semester# 2**

## **Head injury**

**Assistant lecturers**

**Sadiq Salam H**

**Hassanain Mohammed K.**

**Kareem Waheed .**

**Hussein Khadim H.**

**Al-Mustaqbal University College**

**Department of Nursing**

**2<sup>nd</sup> Class**

**Adult Nursing**

## **Head injury**

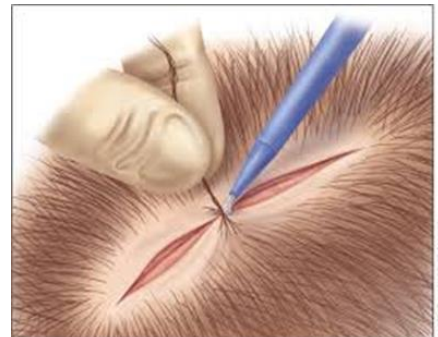
- is a broad classification that includes injury to the scalp, skull, or brain. It is the most common cause of death from trauma in the United States.
- Groups at highest risk for traumatic brain injury are persons age 15 to 24 years and males ,very young (under 5) and the very old (over 75)

## Causes of Head injury

- Motor vehicle accident
- Firearm-related injuries
- Fall
- Assault
- sports-related injuries
- Recreational accidents

## Types of head injuries

- Scalp lacerations
- The most minor type of head trauma
- Scalp- is highly vascular-profuse bleeding
- Major complications is infection



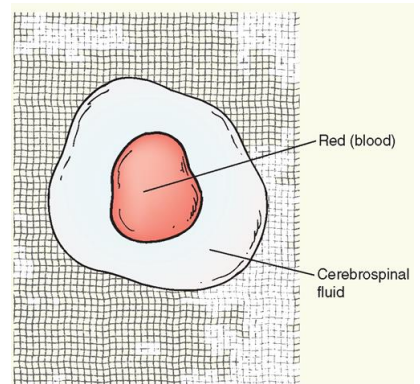
## Types of head injury

**Skull Fractures :-** is a break in the continuity of the skull caused by forceful trauma. It may occur with or without damage to the brain. are classified as:-

- ✓ **linear, comminuted, depressed, or basilar.**
- ✓ A fracture may be **open**, indicating a scalp laceration or tear in the dura (eg, from a bullet or an ice pick),
- ✓ **closed**, in which the dura is intact
- ✓ hemorrhage from the nose, pharynx, or ears
- ✓ ecchymosis (bruising) may be seen over the mastoid (Battle's sign)
- ✓ (CSF otorrhea) and the nose (CSF rhinorrhea).

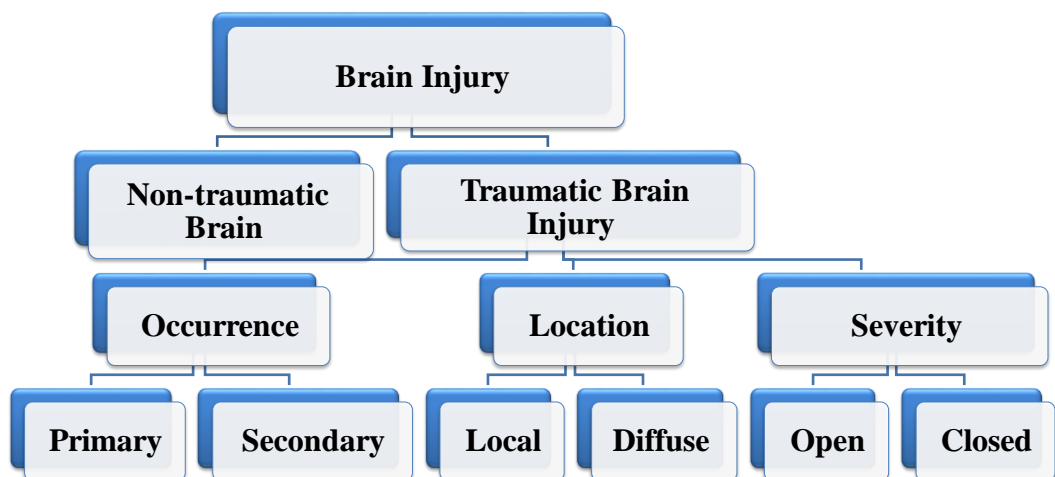
## Basal skull Fractures

- CSF leak ( extravasation) into ear (Otorrhea) or nose ( Rhinorrhea)
- High risk infection or meningitis
- HALLO sign ( Battle sign) on clothes of linen
- Possible injury to internal carotid artery
- Permanent CSF leaks possible



## Medical Management

- ✓ Nondepressed skull fractures generally do not require surgical Treatment
- ✓ close observation of the patient is essential.
- ✓ Many depressed skull fractures are managed conservatively;
- ✓ The head is elevated 30 degrees to reduce ICP
- ✓ Persistent CSF rhinorrhea or otorrhea usually requires surgical intervention.



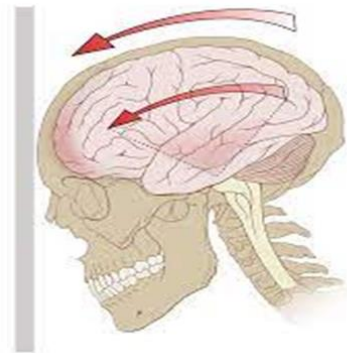
## Clinical Manifestations of Brain Injury

- Altered level of consciousness
- Confusion
- Pupillary abnormalities (changes in shape, size, and response to light)
- Altered or absent gag reflex
- Absent corneal reflex
- Sudden onset of neurologic deficits
- Changes in vital sign
- Vision and hearing impairment
- Sensory dysfunction
- Spasticity
- Headache & Vertigo
- Movement disorders
- Seizures

## Minor head trauma

### -Concussion

- A sudden transient mechanical head injury with disruption of neural activity and a change in LOC
- Brief disruption in LOC
- Amnesia
- Headache
- Short duration



## Major head trauma

### - Contusion

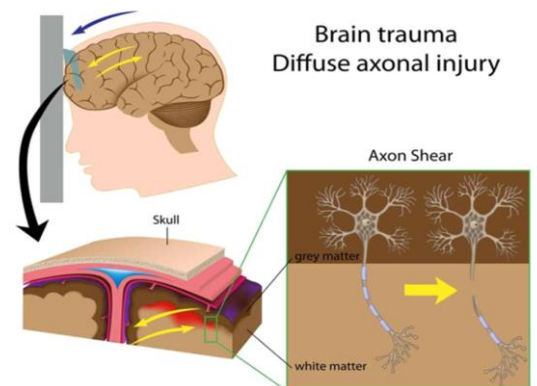
- The bruising of brain tissue with a focal area that maintain the integrity of the pia mater and arachnoid layers

### - Lacerations

- Involve actual tearing of the brain tissue
- Intracerebral hemorrhage is generally associated with cerebral laceration

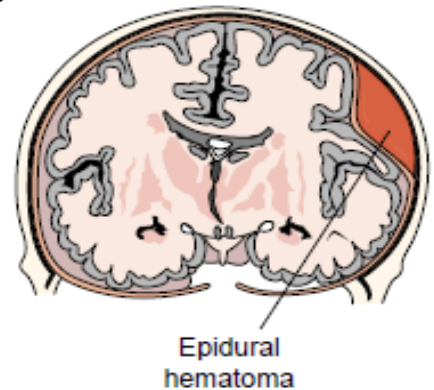
## Diffuse Axonal Injury

widespread damage to axons in the cerebral hemispheres, corpus callosum, and brain stem. Clinically, the patient experiences immediate coma, decorticate and decerebrate posturing



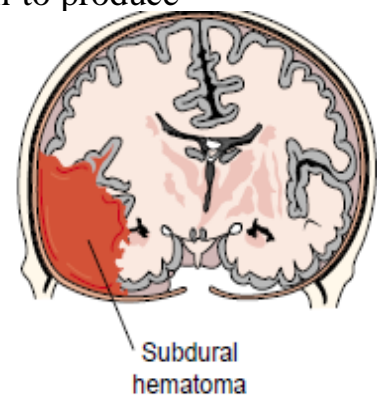
## Complication of head injury

- Epidural hematoma
- Results from bleeding between the dura and the inner surface of the skull.
- Neurologic emergency
- Venous or arterial origin



## Subdural hematoma

- Occurs from bleeding between the dura mater and arachnoid layer of the meningeal covering of the brain
- Usually venous in origin
- Much slower to develop into a mass large enough to produce symptoms
- May be caused by an arterial hemorrhage



## Subdural Hematoma

Acute	Subacute	Chronic
<p>symptoms develop over 24 to 48 hours. (LOC), pupillary signs, and hemiparesis. Coma, increasing blood pressure, decreasing heart rate, and slowing respiratory rate are requiring immediate intervention</p>	<p>less severe Clinical manifestations usually appear between 48 hours and 2 weeks after the injury. Signs and symptoms are similar to those of an acute subdural hematoma</p>	<p>The time between injury and onset of symptoms may be lengthy (eg, 3 weeks to months) There may be severe headache, alternating focal neurologic signs; personality changes; mental deterioration; and focal seizures.</p>

## Diagnostic study

- CT scan considered the best diagnostic test to determine craniocerebral trauma
- MRI
- Cervical spin X-ray
- Glasco Coma scale (GCS)
- Craniotomy
- Craniectomy
- Cranioplasty
- Burr-hole



## **Nursing management**

- **Nursing assessment**
- GCS score
- Neurologic statuses
- Presence CSF leak

## **Nursing diagnoses**

- Ineffective tissue perfusion
- Hyperthermia
- Acute pain
- Anxiety
- Impaired physical mobility

## **Planning**

- Maintain adequate cerebral perfusion
- Remain normothermic
- Be free from pain
- Discomfort and infection
- Attain maximal cognitive, motor and sensory function