

**الأمراض النسيجية**

**Histopathology**

Lecture: 2

**Acute Lung injury**

**Lecture (2)**

**Acute Lung injury**

An **acute lung injury (ALI)** is a condition in which the lungs are not able to provide the body with sufficient amounts of oxygen, resulting in **hypoxemia** (low levels of oxygen in the blood). ALI can occur at any age and is usually the result of **pneumonia** (lung inflammation caused by bacterial or viral infection, in which the air sacs fill with pus and may become solid.

Inflammation may affect

- a- Both lungs (double pneumonia),
- b- One lung (single pneumonia), or
- c- Only certain lobes (lobar pneumonia)

**sepsis** (widespread infection in the body), **direct trauma to the lungs, burns, near drowning**, and or any other situation that can cause inflammation or damage to the lungs.

Damage to the lungs can result in inflammation, and this inflammation can spread to the **alveoli** , decreasing the lung's ability to provide oxygen to the body and resulting in ALI. As ALI progresses, it can develop into **acute respiratory distress syndrome (ARDS)**, which is very similar to ALI but is associated with greater difficulty breathing and a lower concentration of oxygen in the blood.

## Histopathology

### Acute Lung injury

---

The term *acute lung injury* encompasses a spectrum of pulmonary lesions (endothelial and epithelial), which can be initiated by numerous conditions.

Clinically, acute lung injury manifests as:

1. The acute onset of dyspnea (difficult breathing),
2. Decreased arterial oxygen pressure (hypoxemia)  
an abnormally low concentration of oxygen in the blood.
3. Development of bilateral pulmonary infiltrates on radiographs, all in the absence of clinical evidence of primary left-sided heart failure.

### Diagnosis

Diagnosis of ALI is accomplished by using a couple different diagnostic techniques. Since ALI is associated with decreased levels of oxygen in the blood, measuring oxygen levels in the blood can help diagnose this condition. For example, the oxygenation of the blood can be measured by calculating the ratio of partial pressure of the oxygen in the arteries to the concentration of inhaled oxygen ( $\text{PaO}_2/\text{FiO}_2$ ). The ratio is usually around 500 for healthy lungs, and a ratio of less than 300 is associated with ALI.

CT scans, x-rays, and ultrasound images of the lungs can also help diagnose ALI. ALI often results in fluid accumulating in the lungs, and this

accumulation of fluid usually shows up as opaque in CT scans, x-rays, and ultrasounds.

**CLINICAL AND PATHOLOGIC OVERVIEW OF HISTOLOGIC  
PATTERNS ASSOCIATED WITH ALI/ARDS**

- 1- **Diffuse Alveolar Damage:** Diffuse alveolar damage is the classic histologic manifestation of ALI/ARDS. Clinically, patients present with severe hypoxemia and typically require mechanical ventilation. Histologically, DAD is typically divided into 2 phases: the acute/exudative phase and the organizing/proliferative phase. Hyaline membranes are composed of cellular and proteinaceous debris and appear as dense, glassy eosinophilic membranes lining the alveolar ducts and alveolar spaces (Fig.1)
  
- 2- **Acute Fibrinous and Organizing Pneumonia:** A histologic pattern associated with acute lung injury in which the alveolar spaces are filled with organizing fibrin balls, in contrast to the true hyaline membranes found in DAD. The process may be patchy or relatively diffuse. The alveolar septa may show mild interstitial widening or lymphocytic infiltrates, but significant eosinophils or neutrophils should not be seen (Fig. 2)

**3- Eosinophilic Pneumonia.**

Eosinophilic pneumonia in general is characterized by intra-alveolar fibrin and macrophages in variable proportions, admixed with numerous eosinophils. Eosinophils may also be present in the interstitial tissue and eosinophilic microabscess formation may be observed. In some cases, eosinophils may infiltrate blood vessel walls. In AEP, these features may be present to varying degrees with the additional finding of hyaline membrane formation identical to that seen in the acute phase of DAD (Figure 3).

**4- Diffuse Alveolar Hemorrhage With Capillaritis :** (Diffuse

alveolar hemorrhage (DAH) refers to a clinical syndrome resulting from injury to the alveolar capillaries, arterioles, and venules leading to red blood cell accumulation in the distal air spaces).

Capillaritis is evidenced by neutrophils within the alveolar septa with resultant vascular necrosis (Figure 4).

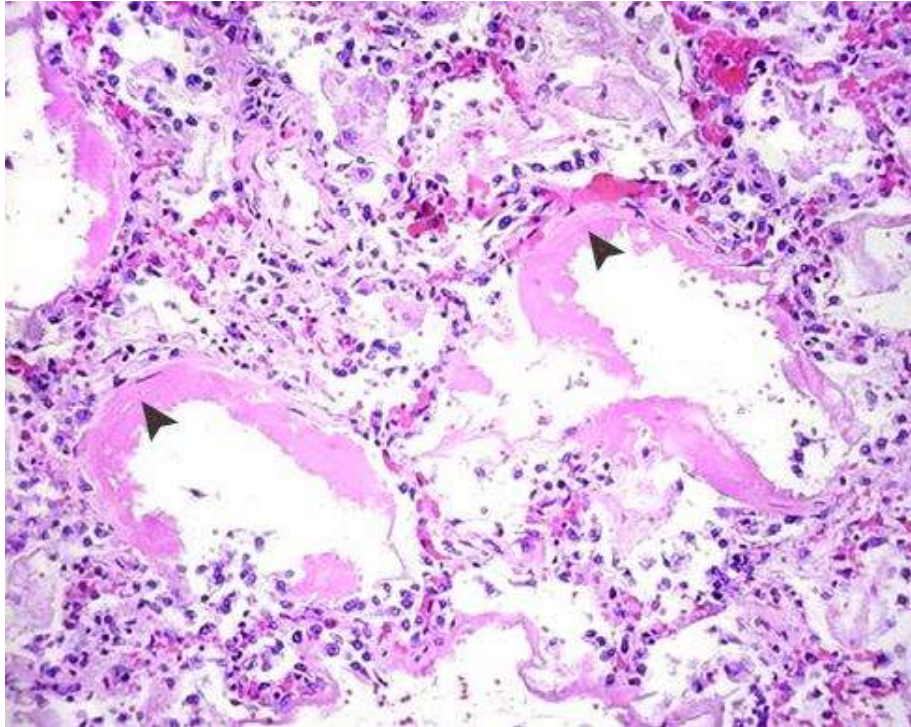
**5- Organizing Pneumonia:** Organizing pneumonia (OP) is an

interstitial lung disease, and OP patients present with characteristic clinical, radiological, and histological findings. Histopathologically, there are buds of granulation tissue, which are called Masson bodies and consist of exudative materials including connective tissue

## Histopathology Acute Lung injury

---

components, fibrin, and fibroblasts, in the alveolar ducts and alveoli). (Figure 5).



**Fig. 1.** Diffuse alveolar damage in acute lung injury and acute respiratory distress syndrome. Some alveoli are collapsed; others are distended. Many are lined by bright pink hyaline membranes (*arrow*).

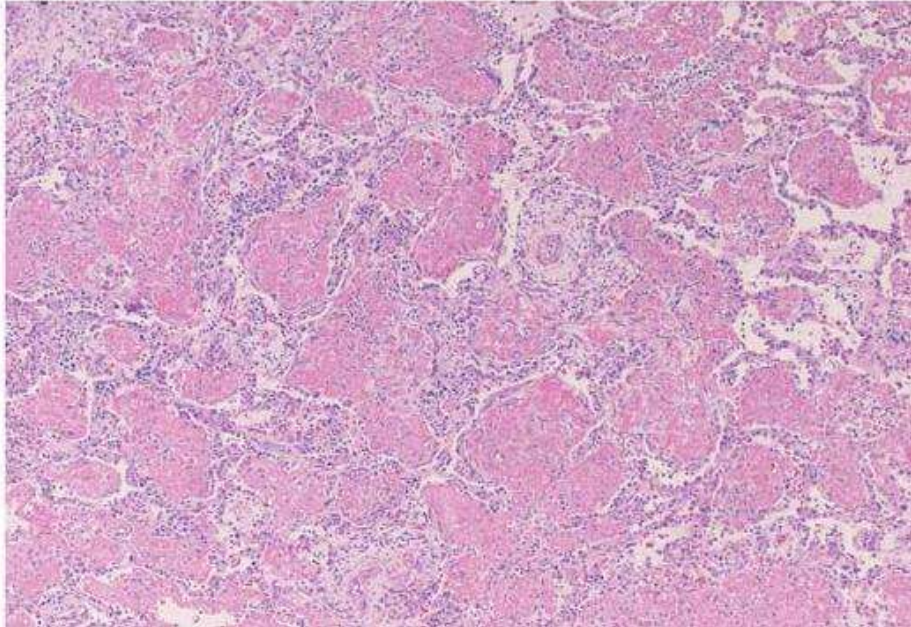


Fig. 2. Acute fibrinous and organizing pneumonia is characterized by intra-alveolar fibrin balls in contrast to classic hyaline membranes

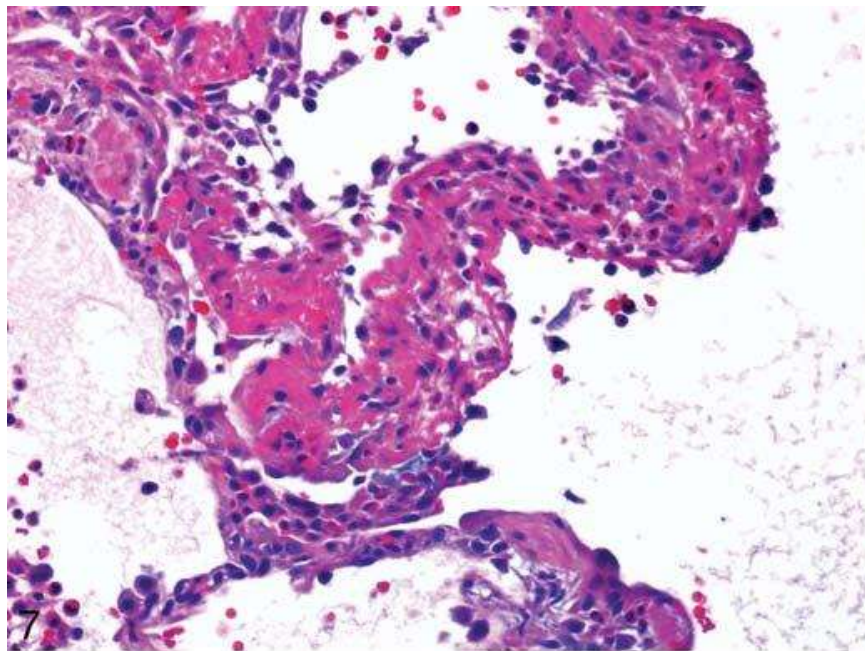


Fig. 3. Acute eosinophilic pneumonia. Hyaline membranes, essentially identical to those seen in diffuse alveolar damage, are present but contain numerous eosinophils on closer inspection.

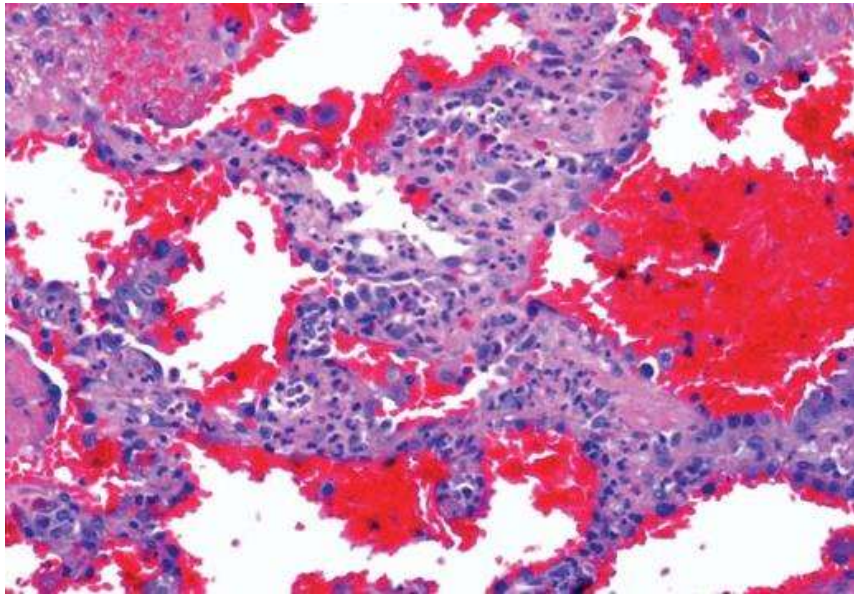


Fig. 4. Neutrophilic capillaritis is characterized by prominent neutrophils within the alveolar septa. Necrosis of the capillary may be difficult to visualize, but neutrophilic debris, as seen here, or fibrin thrombi suggest underlying vascular damage

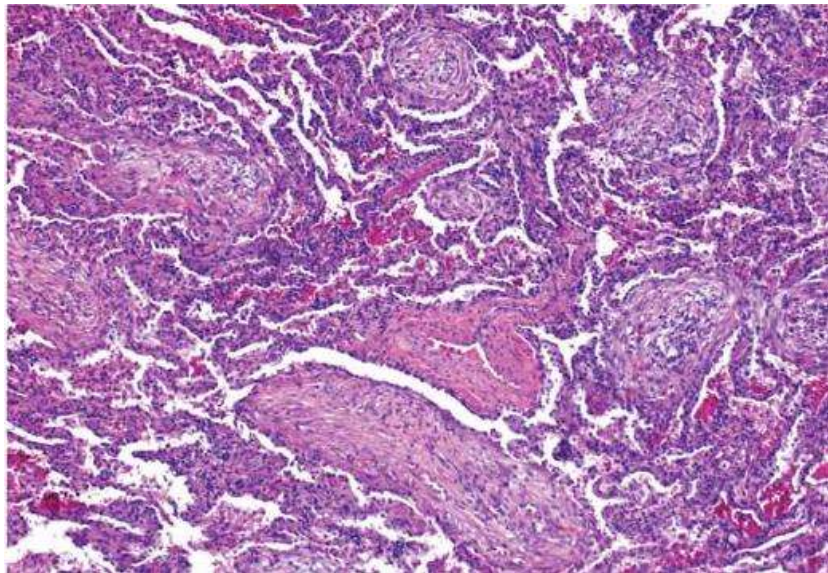


Fig.5. Organizing pneumonia is characterized by patchy intra-alveolar organizing fibroblastic tissue. The surrounding alveolar septa contain mild lymphocytic infiltrates