

الجامعة التقنية الوسطى  
كلية التقنيات الصحية والطبية/ بغداد  
قسم: تقنيات الاشعة المادة: التصوير بالرنين المغناطيسي  
المرحلة: الرابعة

**Title: MRI safety, preparation and contrast agent.:العنوان**

**Name of the instructor:**

**اسم المحاضر:**

م. حيدر عبد القادر طاهر

Lecturer. Haydar Abdul Kader Taher

**Target population:**

**الفئة المستهدفة:**

طلبة المرحلة الرابعة في قسم تقنيات الاشعة

## Introduction:

## المقدمة:

MRI is a valuable diagnostic tool, and safety measures are in place to ensure the well-being of patients and staff. Communication between patients and healthcare providers, as well as adherence to safety protocols, are essential for a safe MRI experience. Patients with concerns about MRI safety should discuss them with their healthcare team to address any specific risks or considerations.

## Scientific Content:

## المحتوى العلمي:

### **MRI Examination procedure patient preparation and safety**

#### **Identity**

Prior to any examination being performed, the identity of the patient must be checked by the technologist. Patients arriving into MRI Department are often worried or apprehensive and this may make it difficult for them to understand the instructions or may produce an apparently aggressive attitude. In such cases, the technologist should convince amicably and soft tone of voice often do a great deal of comfort and gives the patient confidence that he/ she is in an efficient hand. The technologist should make every effort to obtain the willing cooperation of the patient consent. Children and uncooperative patients should be sedated before examination.

- Before entering the equipment room, the patient must wear a hospital gown and should remove all personal possessions such as watch, wallet, keys, hair pins, jewels, coils, removable dental bridge work, etc. Even credit cards and cell phones must be secured as the scanner will erase the information on them.
- Wheelchair and trolleys (MR noncompatible) must always be kept outside the magnet room. The patient is made to lie down on a table. This table then passes through a tunnel within the equipment. Inside the tunnel, it is quite noisy when the scanning is going on.

The region of interest is positioned at the center of the magnet. The patient can hear the voice of the radiologist or technologist and can respond. While the patient lies within the tunnel, images of the interested regions are taken from different angles. These images can be seen on a computer screen. The entire procedure takes 30 to 45 minutes approximately depending upon the strength of the magnetic field and the parameters set on.

It is most important that the patient should remain relaxed and completely still during the scan. The patient can resume the routine activities after getting the scan done.

- The patient should always be informed as to what is going to happen and what he/she is expected to do, so that he/she can cooperate as much as possible.
- The patient should not wear makeup because some products may contain metallic particles.
- The patient should be covered with a lightweight blanket.
- The patient must be made comfortable as far as possible because if the patient is in pain or in distress, it is unlikely that he will be able to remain still for long.
- *Explanation:* A detailed explanation of the exam to be performed (to be informed to the patient) to give the patient, particularly as to how long the procedure will take.
- The technologist from the start of examination/procedure should make an effort to remember the name of the patient with whom he or she is dealing and use it.
- Clear instructions regarding breathing or swallowing should be given and rehearsed to ensure that the patient does hold his breath or swallow when required to do so.

Due to the high magnetic field strengths used during MRI examination, certain patients are unsuitable for imaging. These include patients who have:

- Aneurysm clips (Older Ferromagnetic types)
- Cardiac pacemakers
- Patients with otologic implants and ocular implants
- Cochlear implants
- Metallic foreign bodies, especially within the eye.

### **Patient Screening**

The following items can interfere with MR imaging and some can be hazardous to your safety. Please check if you have any of the following MR incompatible objects:

- Cardiac pacemaker/pacemaker lead wires
- Brain aneurysm clips
- Aortic clips
- Implanted neurostimulators or lead wires
- Artificial heart valve
- Insulin pump
- Electrodes
- Hearing aids
- IUD (Intrauterine Device)
- Shunts

- Joint replacements
  - Fractured bones treated with metal rods, metal plates, pins, screws, nails or clips
  - Harrington rod
  - Bone or joint pins
  - Metal silvers in the eyes
  - Cochlear implants
  - Tattoo eyeliner
  - Others
- On the drawing

### **Screening Prior to Scanning**

- Removable dental work
- Hearing aid
- Jewellery
- Watch
- Wallet or money clip
- Pens or pencils
- Keys
- Coins
- Pocket knife
- Metal zippers or buttons
- Belt buckle
- Shoes
- Magnetic strip cards
- Credit cards, bank cards
- Hair pins or barrettes
- Glasses

### **EFFECTS OF RF POWER**

The RF pulses used in MR causes tissues to absorb RF power under certain conditions. This may cause tissue heating. The amount of heating depends on several factors such as patient size and pulse-sequence timing.

Before the patient is being scanned, the computer estimates the level of heating and compares it to the predetermined exposure limits. If the scan exceeds these limits, the system then adjusts the scan parameters before starting the scan. The complete estimate is based partially on patient weight. Therefore, take care to enter the patient's weight correctly to prevent excessive RF.

## Claustrophobia and Sedation

Although not thought of as a main safety issue, patient anxiety and claustrophobia (specifically the fear of enclosed spaces) may be sufficient in some instances to prevent the completion of the scan. Published figures for the percentage of aborted scans in these situations vary widely from 1 to 20%. Undoubtedly, the type of scan (e.g., use of head coil) and the method of entry (head or feet first) makes a significant difference. Methods to improve patient comfort, not only to alleviate stress but also to minimize movement, include bore lighting, ventilation, and head coil mirrors to maintain visible contact with staff outside the scanner. For certain scans music may be played through headphones to further relax the patient.

Although the number of MR scans being performed continues to rise, modern scanner designs with shorter and wider bores, will help reduce the relative number of failed examinations.

## Emergency Preparedness:

MRI facilities have emergency procedures in place in case of accidents. This includes protocols for dealing with metal objects accidentally brought into the MRI room and for responding to medical emergencies that may occur during a scan.

## Contrast Agents and Kidney Function:

Gadolinium-based contrast agents are sometimes used in MRI to enhance the visibility of certain tissues. These agents are generally safe, but they can pose a risk to individuals with impaired kidney function. Patients with kidney problems should be closely monitored and may need to undergo alternative imaging tests.

## Pregnancy and MRI:

While there is no known harm to the fetus from the MRI magnetic field or radio waves, MRI during the first trimester is generally avoided unless medically necessary. Pregnant patients should inform their healthcare providers and MRI technologists before the scan.

## HAZARDS

Claustrophobia despite the fact that the patient lies in a confined space is rarely a serious problem. MRI has not been proved to have any adverse effects on fetuses. However, some teams avoid using during the first trimester of pregnancy.

Till date, no harmful effects have been observed from magnetic influences.

## Acoustic Noise

The most obvious dB/dt effect the patient will encounter is the loud noise in the scanner bore during the examination. It is a consequence of the force exerted on the gradient coils due to the rapidly varying current within them in the presence of the main field. The frequency of the current is such that the coils vibrate against their surroundings and produce noise at an acoustic level. This noise, which increases with field strength and varies considerably with the type of sequence being used, is sufficient to warrant ear protection for all patients. High field systems have had to be designed with methods of reducing this noise.

## QUENCHING

A magnet quench will result in several days of down time. So, do not press or push the button except in a real emergency. Do not test that button. It should be tested only by qualified service personnel. Quench button is located near the magnet.

### Magnet Quench Hazards

Magnetic quench is indicated by a loud noise, warning message, dense white vapor (with vent failure), helium meter dropping considerably or the tilting of an image on the image screen.

- If the patient needs medical attention, press an emergency stop button on the console or magnet and remove the patient from the scan room.
- Evacuate the patient and personnel from the scan room and close the scan room door.

## Contrast media:

### A-Mechanism of action

In order to increase contrast between pathology and normal tissue enhancement agents may be introduced that selectively affect the T1 and T2 relaxation times in tissues. Both T1 recovery and T2 decay are influenced by the magnetic field experienced locally within the nucleus. These molecules rotate and the rate of rotation of the molecules is a characteristic property of the solution. It is dependent on:

- the magnetic field strength;
- the viscosity of the solution;
- the temperature of the solution.

Molecules that tumble with a frequency at or near the Larmor frequency have more efficient T1 recovery times than other molecules.

### Types of main contrast media

#### \*Gadolinium

Gadolinium (Gd) is a paramagnetic agent. It has a large magnetic moment and when it is used the T1 relaxation times of nearby water protons are therefore reduced, resulting in an increased signal intensity on T1 weighted images. For this reason, gadolinium is known as a T1 enhancement agent.

Gadolinium is a rare-earth metal that cannot be excreted by the body and would cause long term side effects, as it binds to membranes.

#### Side effects

- A slight transitory increase in bilirubin and blood iron
- Mild transitory headaches
- Nausea
- Vomiting
- Hypotension
- Gastro-intestinal upset
- Rash

#### Contra-indications

- Haematological disorders
- Sick cell anaemia
- Pregnancy

### Administration

The effective dosage of Gd-DTPA is 0.1 millimole (mmol) per kilogramme (kg) of body weight (mmol/kg), (approximately 0.2 ml/kg)

### Clinical applications

Gadolinium has proven very useful in imaging the central nervous system because of its ability to pass through breakdowns in the blood–brain barrier (BBB). Clinical indications for gadolinium include:

- tumours pre and post surgery;
- pre and post radiotherapy;
- infection;
- infarction;
- inflammation;
- post-traumatic lesions;
- post operation lumbar disc;
- breast disease;
- prostatic disease;
- vessel patency.

### \* Iron oxide

Iron oxides shorten relaxation times of nearby hydrogen atoms and therefore reduce the signal intensity in normal tissues. This results in a signal loss on proton density weighted or heavily T2 weighted images. Super-paramagnetic iron oxides are known as T2 enhancement agents.

Iron oxide is taken up by the reticulo-endothelial system and excreted by the liver so that normal liver is dark and liver lesions are bright on T2 weighted images.

### Side effects

- Mild to severe back, leg and groin pain is experienced and, in a few cases, head and neck pain.
- Patients experience digestive side-effects including nausea, vomiting and diarrhea.
- Anaphylactic like reactions and hypotension have been reported in a few patients.

### Contra-indications

- Contra-indicated in patients with known allergies / hypersensitivity to iron.
- Since the infusion is dark in colour, skin surrounding the infusion site might discolour if there is extravascation.

### Administration

The recommended dose of iron oxide is 0.56 mg of iron per kg of body weight. If using Feridex® dilute in 100 ml of 50% dextrose and give I.V. over 30 min.



### Clinical applications

This is mainly used in liver imaging where normal liver is dark on T2 weighted images and lesions appear bright .

### \*Other contrast agents

Gastrointestinal contrast agents are sometimes used for bowel enhancement. These include barium, ferromagnetic agents and fatty substances. However due to constant peristalsis, these agents enhance bowel motion artefacts more often than enhancing pathologic lesions. The use of anti-spasmodic agents helps to retard peristalsis to decrease these artifacts. Other agents include helium which is inhaled and assists in the evaluation of lung perfusion.

### References:

### المصادر:

- **Step by step MRI Jagannmohan Reddy v parsed**
- **Mriquestions.com**
- **Questions and answers with MRI**

الجامعة التقنية الوسطى  
كلية التقنيات الصحية والطبية/ بغداد  
قسم: تقنيات الاشعة المادة: التصوير بالرنين المغناطيسي  
المرحلة: الرابعة

**Title: MRI of the brain** العنوان:

**Name of the instructor:** اسم المحاضر:

م. حيدر عبد القادر طاهر

Lecturer. Haydar Abdul Kader Taher

**Target population:** الفئة المستهدفة:

طلبة المرحلة الرابعة في قسم تقنيات الاشعة

**Introduction:** المقدمة:

Understanding brain MRI imaging is essential for MRI technologist to perform MRI exams effectively, interpret MRI results accurately, optimize MRI parameters, and keep up-to-date with MRI technology. Brain MRI imaging can provide information about the brain's anatomy, detect abnormalities, and measure blood flow and diffusion in the brain. MRI technologist can learn about brain MRI imaging through MRI tech programs, continuing education courses, and on-the-job training.

## Scientific Content:

## المحتوى العلمي:

### Common indications

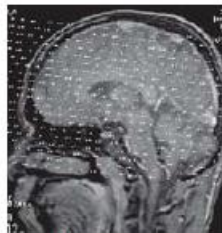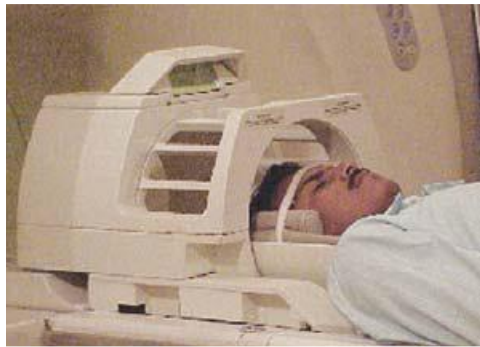- MS
- Primary tumour assessment and/or metastatic disease
- AIDS (toxoplasmosis)
- Infarction (cerebral vascular accident (CVA) versus transient ischaemic attack (TIA))
- Haemorrhage
- Hearing loss
- Visual disturbances
- Infection
- Trauma
- Unexplained neurological symptoms or deficit
- Preoperative planning
- Radiation treatment planning
- Follow-up (surgical or treatment)

### Equipment

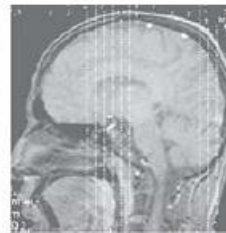- Head coil (quadrature or multi-coil array)
- Immobilization pads and straps
- Earplugs/headphones
- High-performance gradients for EPI, diffusion and perfusion imaging

## Patient positioning

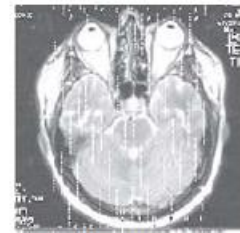
The patient lies supine on the examination couch with their head within the head coil. The head is adjusted so that the inter-pupillary line is parallel to the couch and the head is straight. The patient is positioned so that the longitudinal alignment light lies in the midline, and the horizontal alignment light passes through the nasion. Straps and foam pads are used for immobilization.



Sagittal localizer to obtain axial slices



Sagittal localizer to obtain coronal slices



Axial localizer to obtain sagittal slices

## Main MRI sequences of the brain

### 1- T1-Weighted Axial Imaging:

Parameters:

Slice thickness: 5-6 mm

Use: Provides detailed anatomical information of the brain, helps in detecting tumors, and is often used as a baseline for post-contrast imaging.

## **2-T2-Weighted Axial Imaging:**

Parameters:

Slice thickness: 5-6 mm

Use: Highlights lesions, edema, and cysts. Good for detecting white matter diseases and brain abnormalities.

## **3-T1-Weighted Coronal Imaging:**

Parameters:

Slice thickness: 5-6 mm

Use: Provides a different perspective of brain anatomy, especially useful for assessing the pituitary gland and other coronal structures.

## **4-Fluid-Attenuated Inversion Recovery (FLAIR) Imaging:**

Parameters:

Slice thickness: 5-6 mm

Use: Suppresses CSF signal and enhances lesion visibility, helpful in detecting multiple sclerosis (MS) lesions and vascular abnormalities.

## **5-Diffusion-Weighted Imaging (DWI):**

Parameters:

Slice thickness: 5-6 mm

b-values: Typically, 0 and 1000 sec/mm<sup>2</sup>

Use: Detects areas of restricted diffusion, valuable for diagnosing acute stroke and evaluating tissue damage.

## **6-Diffusion Tensor Imaging (DTI):**

Parameters:

Slice thickness: 2-3 mm

Use: Maps white matter tracts, assesses brain connectivity, and studies conditions like traumatic brain injury and white matter diseases.

## **7-Susceptibility-Weighted Imaging (SWI):**

Parameters:

Slice thickness: 1-2 mm

Use: Detects hemorrhages, microbleeds, and venous abnormalities, useful in cases of head trauma and vascular disorders.

## **8-Functional MRI (fMRI):**

Parameters:

Typically includes T2\*-weighted or BOLD (Blood Oxygen Level Dependent) sequences.

Use: Maps brain activity and connectivity during tasks or at rest, used in research and for preoperative planning in certain cases.

## **9-Magnetic Resonance Spectroscopy (MRS):**

Parameters:

Acquires spectra from specific regions of interest.

Use: Measures biochemical information about brain tissue, aids in characterizing brain lesions, tumors, and metabolic disorders.

## **10-Perfusion MRI (pMRI):**

### **Parameters:**

Uses dynamic contrast enhancement or arterial spin labeling.

Use: Measures blood flow to assess brain perfusion, valuable in diagnosing and monitoring acute stroke, vasculitis, and tumor response to treatment.

In Summary, these sequences offer a comprehensive view of the brain's structure, function, and blood flow, allowing for the diagnosis and evaluation of various neurological conditions and diseases. The choice of sequences and parameters may vary depending on the clinical indication and the patient's specific needs. Always consult with a medical professional or radiologist for the most appropriate MRI protocol.

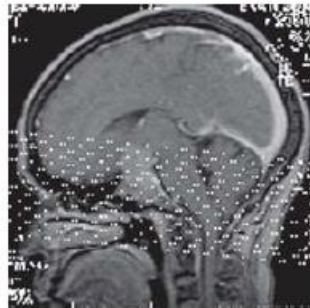
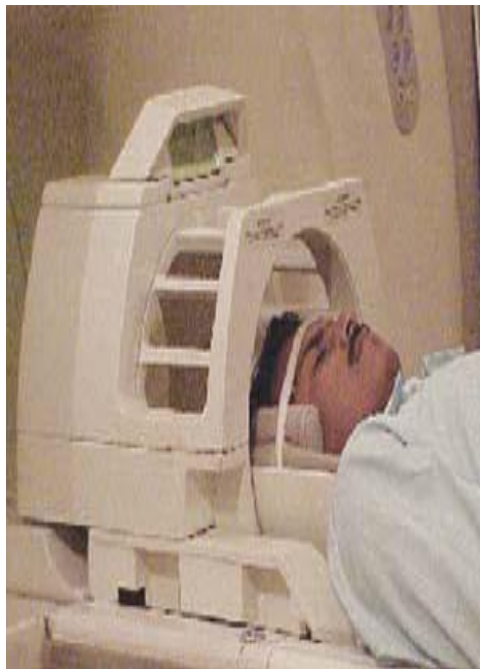## MRI of the Pituitary

### Common indications

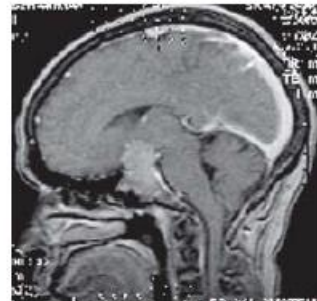
- Investigation of diseases related to pituitary function (hyperprolactinaemia, Cushing's disease, acromegaly, hypopituitarism, diabetes insipidus, amenorrhea)
- Hypothalamic disorders
- Visual field defect
- Post-operative assessment of pituitary adenomas

### Equipment

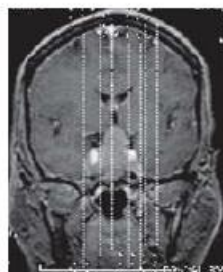
- Head coil (quadrature or multi-coil array)
- Immobilization pads and straps
- Earplugs/headphones



Sagittal localizer for axial slices



Sagittal localizer for coronal slices



Coronal localizer for sagittal slices



## Main MRI sequences of pituitary

### **1-T1-Weighted Axial Imaging:**

Parameters:

Slice thickness: 3-5 mm

Use: Provides anatomical details of the pituitary gland and surrounding structures. Useful for detecting pituitary tumors and assessing their size and extension.

### **2-T2-Weighted Axial Imaging:**

Parameters:

Slice thickness: 3-5 mm

Use: Helps in identifying abnormalities with different tissue contrasts. Useful for visualizing cystic or hemorrhagic changes in pituitary lesions.

### **3-T1-Weighted Post-Contrast Imaging:**

Parameters:

Slice thickness: 3-5 mm

Contrast agent: Gadolinium-based contrast agent

Use: Enhances the visibility of pituitary lesions by highlighting areas of contrast uptake. Particularly useful for detecting pituitary adenomas and assessing their characteristics.

### **3-Thin-Slice Dynamic Contrast-Enhanced Imaging:**

Parameters:

Slice thickness: 1-2 mm

Temporal resolution: 2-5 seconds

Contrast agent: Gadolinium-based contrast agent

Use: Evaluates the vascularity and blood flow of pituitary lesions over time, aiding in distinguishing between different types of pituitary tumors.

#### **4-Fat-Suppressed Imaging:**

Parameters:

Slice thickness: 3-5 mm

Use: Helps differentiate between fat and non-fat components within pituitary lesions, assisting in characterizing lesions such as craniopharyngiomas.

#### **5-3D Volumetric Imaging:**

Parameters:

High-resolution isotropic imaging

TR and TE similar to T1-weighted sequences

Use: Provides a three-dimensional view of the pituitary gland and surrounding structures, allowing for precise localization and assessment of lesions.

#### **6-Diffusion-Weighted Imaging (DWI):**

Parameters:

Slice thickness: 3-5 mm

b-values: Typically 0 and 1000 sec/mm<sup>2</sup>

Use: May help in characterizing pituitary lesions based on their cellularity and diffusion properties. Can be useful in differentiating pituitary adenomas from other lesions.

## **7-Magnetic Resonance Spectroscopy (MRS):**

Parameters:

Single-voxel or multi-voxel spectroscopy Use: Measures chemical composition within the pituitary gland, assisting in distinguishing between different types of pituitary lesions based on their metabolic profiles.

These MRI sequences and parameters provide a comprehensive evaluation of the pituitary gland, helping to diagnose and characterize various pituitary disorders, including adenomas, cysts, and other lesions. The choice of sequences may vary based on clinical indications and the suspected pathology. Always consult with a radiologist or healthcare provider for the most appropriate pituitary MRI protocol.

## **References:**

**المصادر:**

**Handbook of MRI Technique Catherine Senior 5<sup>TH</sup> EDITION 2022**

**Step by step MRI Jaganmohan Reddy v parsed**

**Mriquestions.com**

**Essential of body MRI 2018**

الجامعة التقنية الوسطى

كلية التقنيات الصحية والطبية/ بغداد

قسم: تقنيات الاشعة المادة: التصوير بالرنين المغناطيسي  
المرحلة: الرابعة

**Title: MRI of the orbits and Sella turcica.** العنوان:

**Name of the instructor:** اسم المحاضر:

م. حيدر عبد القادر طاهر

lecturer. Haydar Abdul Kader Taher

**Target population:** الفئة المستهدفة:

طلبة المرحلة الرابعة في قسم تقنيات الاشعة

**Introduction:** المقدمة:

MRI technologist need to learn about orbits MRI for several reasons:

Performing specialized exams: Orbits MRI is a specialized imaging technique that focuses on the structures of the eye sockets and surrounding areas. MRI technologist need to learn the specific protocols and techniques for performing orbits MRI exams

Understanding anatomy and pathology: Orbits MRI can help visualize structures such as the eyeballs, optic nerves, and extraocular muscles. By learning about orbits MRI, technologist can better understand the anatomy and pathology of the eye and surrounding structures

Patient positioning and safety: Orbits MRI requires specific patient positioning to ensure optimal image quality and patient comfort. MRI technologist need to learn how to position patients for orbits MRI exams and ensure their safety during the procedure

Interpreting MRI results: MRI technologist need to be able to interpret orbits MRI results accurately and communicate these results effectively to physicians and other healthcare professionals. Understanding the specific features and findings of orbits MRI can help technologist in this process

Collaboration with radiologists and ophthalmologists: Orbits MRI is often performed in collaboration with radiologists and ophthalmologists to evaluate and diagnose various eye and orbital conditions. By understanding orbits MRI, technologist can effectively contribute to the multidisciplinary team and provide valuable insights during the imaging process

## **Scientific Content:**

### **Common indications**

- Proptosis
- Visual disturbance
- Evaluation of orbital or ocular mass lesions

### **Equipment**

- Small surface coil for globe and orbit
- Quadrature head coil or multi-coil array coil for orbital apex, chiasm and intracranial optic pathways
- Immobilization straps and foam pads
- Earplugs/headphones

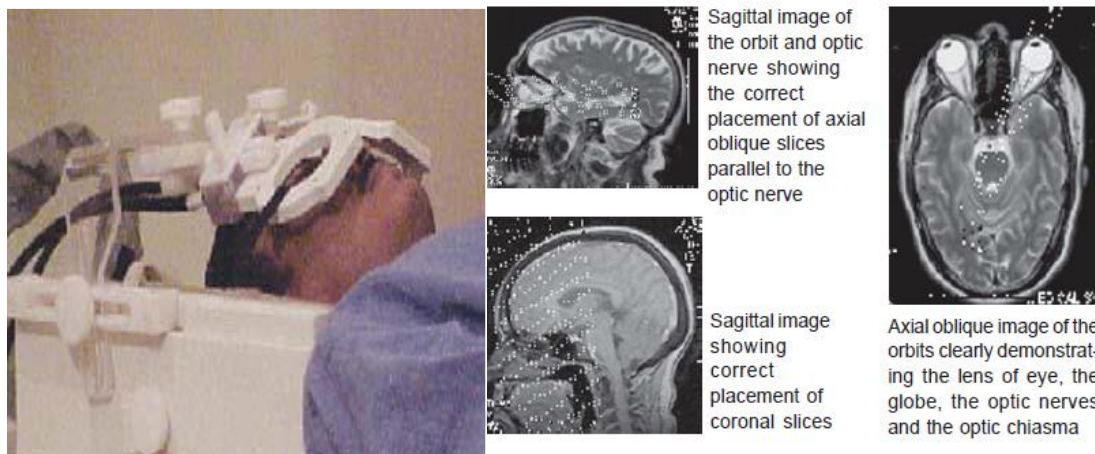
### **Patient positioning**

The patient lies supine on the examination couch. Both orbits are usually examined at the same time. If surface coils are used, these are placed over each orbit but

should not touch the patient. Special holders are often provided by the manufacturers to enable the coils to be placed anteriorly over the eyes. Ensure that the receiving side of the coils faces the orbits, that is, towards the table. The patient assumes a fixed gaze, straight ahead, with the eyes open. This enables the patient to focus and keeps the eyes still, thereby reducing motion artefact. Any eye make-up is removed prior to the examination as this causes image artefact and patient discomfort, especially if it contains metal.

The patient is positioned so that the longitudinal alignment light lies in the midline, and the horizontal alignment light passes through the orbits.

If surface coils are used, this corresponds to the center of the coils. Straps and foam pads are used for immobilization.



## Main sequences of orbit MRI sequences:

### 1-T1-Weighted Axial Imaging:

Parameters:

Slice thickness: 3-5 mm

Use: Provides detailed anatomical information of the orbital structures, including the eye, extraocular muscles, and optic nerves. Useful for detecting tumors, inflammation, and trauma.

## **2- T2-Weighted Axial Imaging:**

Parameters:

Slice thickness: 3-5 mm

Use: Highlights soft tissues and helps identify conditions such as edema, inflammation, and lesions in the orbital region.

## **3-T1-Weighted Post-Contrast Imaging:**

Parameters:

Slice thickness: 3-5 mm

Contrast agent: Gadolinium-based contrast agent

Use: Enhances visualization of lesions, vascular structures, and inflammatory changes in the orbits. Valuable for detecting and characterizing tumors and evaluating vascular abnormalities.

## **4-Fat-Suppressed Imaging:**

Parameters:

Slice thickness: 3-5 mm

Use: Differentiates between fat and non-fat components in the orbits, aiding in the assessment of lesions, especially when evaluating lesions like dermoid cysts or lipomas.

## **5-Diffusion-Weighted Imaging (DWI):**

Parameters:

Slice thickness: 3-5 mm

b-values: Typically, 0 and 1000 sec/mm<sup>2</sup>

Use: Assesses tissue cellularity and may help distinguish between different orbital lesions, including tumors and inflammatory conditions.

### **6-Dynamic Contrast-Enhanced Imaging:**

Parameters:

Slice thickness: 3-5 mm

Temporal resolution: 2-5 seconds

Contrast agent: Gadolinium-based contrast agent

Use: Evaluates perfusion and blood flow in the orbits, helping to differentiate between benign and malignant lesions and assessing vascular conditions.

### **7-Fat-Saturation Sequences:**

Parameters:

Utilizes fat saturation techniques

Use: Helps in evaluating fat-containing lesions within the orbits, such as lipomas, and provides better contrast between fat and non-fat tissues.

### **8-Orbital MRI Angiography (MRA):**

Parameters:

Utilizes time-of-flight or contrast-enhanced MRA techniques

Use: Visualizes the blood vessels within the orbits, assisting in the detection of vascular lesions, aneurysms, or other vascular abnormalities.

These MRI sequences and parameters are tailored for assessing the orbits and surrounding structures, helping diagnose a range of conditions, including tumors, inflammatory diseases, vascular abnormalities, and trauma. The choice of sequences may depend on the specific clinical indications and the suspected



pathology. Consultation with a radiologist or ophthalmologist is important for determining the appropriate orbit MRI protocol.

## References:

## المصادر:

Handbook of MRI Technique Catherine Senior 5<sup>TH</sup> EDITION 2022  
Step by step MRI Jagannmohan Reddy v parsed

Mriquestions.com

Essential of body MRI 2018

الجامعة التقنية الوسطى

كلية التقنيات الصحية والطبية/ بغداد

قسم: تقنيات الاشعة  
المادة: التصوير بالرنين المغناطيسي  
المرحلة: الرابعة

Title: MRI of the cervical spinal cord.

العنوان:

Name of the instructor:

اسم المحاضر:

م. حيدر عبد القادر طاهر

lecturer. Haydar Abdul Kader Taher

## Target population:

الفئة المستهدفة:

طلبة المرحلة الرابعة في قسم تقنيات الاشعة

## Introduction:

المقدمة:

learning about cervical spine MRI is essential for MRI technologist to perform MRI exams effectively, interpret MRI results accurately, ensure patient safety, understand anatomy and pathology, and collaborate with other healthcare professionals. MRI technologist can acquire this knowledge through specialized training programs, continuing education courses, and on-the-job experience.

## Scientific Content:

المحتوى العلمي:

### Common indications

- Cervical myelopathy
- Cervical radiculopathy
- Cervical cord compression or trauma
- Assessment of extent of spinal infection or tumour
- Diagnosis of Chiari malformation and cervical syrinx. (Total extent of syrinx must be determined. Whole spine imaging may be necessary.)
- MS plaques within the cord

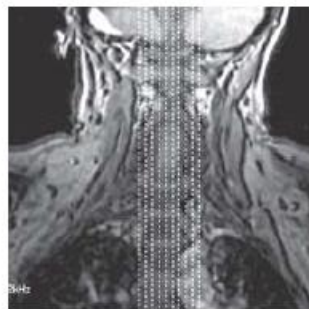
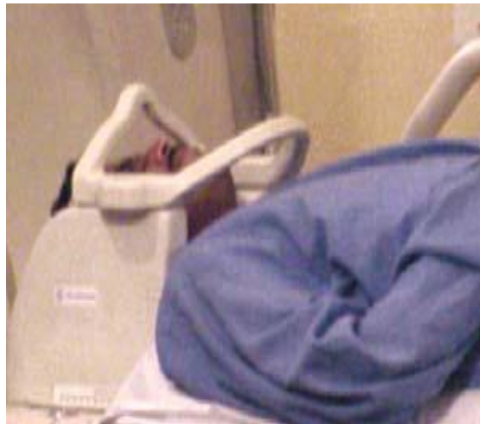### Equipment

- Posterior cervical neck coil/volume neck coil/multi-coil array spinal coil
- Immobilization pads and straps
- Pe gating leads if required
- Earplugs/headphones

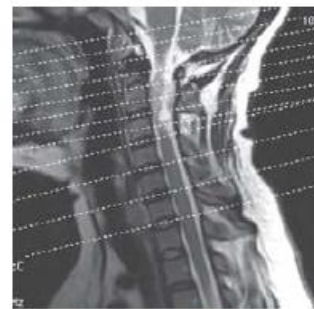
## **Patient positioning**

The patient lies supine on the examination couch with the neck coil placed under or around the cervical region. Coils are often moulded to fit the back of the head and neck so that the patient is automatically centred to the coil. If a flat coil is used, placing supporting pads under the shoulders flattens the curve of the cervical spine so that it is in closer proximity to the coil. The coil should extend from the base of the skull to the sternoclavicular joints in order to include the whole of the cervical spine.

The patient is positioned so that the longitudinal alignment light lies in the midline, and the horizontal alignment light passes through the level of the hyoid bone (this can usually be felt above the thyroid cartilage/Adam's apple). The patient's head is immobilized with foam pads and retention straps. Pe gating leads are attached if required.



Coronal localizer for sagittal slices



Sagittal C-spine showing axial-oblique slice positions parallel to each disc spaces

## **Main sequences of cervical spine MRI**

### **1-Sagittal T1-Weighted Imaging:**

Parameters:

Slice thickness: 3-5 mm

Use: Provides an anatomical overview of the cervical spine, including the vertebral bodies and intervertebral discs. Useful for assessing degenerative changes and spinal alignment.

## **2-Sagittal T2-Weighted Imaging:**

Parameters:

Slice thickness: 3-5 mm

Use: Highlights soft tissues, including the spinal cord and surrounding structures. Helps in identifying disc herniations, spinal stenosis, and ligamentous injuries.

## **2-Axial T1-Weighted Imaging:**

Parameters:

Slice thickness: 3-5 mm

Use: Provides detailed cross-sectional images of the cervical spine, useful for assessing the spinal cord and nerve roots.

---

## **3-Axial T2-Weighted Imaging:**

Parameters:

Slice thickness: 3-5 mm

Use: Visualizes the spinal cord and nerve roots in axial sections, aiding in the detection of pathology such as disc herniations and spinal cord compression.

## **3-Sagittal Short Tau Inversion Recovery (STIR) Imaging:**

Parameters:

Slice thickness: 3-5 mm

Use: Suppresses fat signal and enhances the visibility of edema and inflammatory changes, making it valuable for detecting bone marrow disorders and infection.

## **4-Diffusion-Weighted Imaging (DWI):**

Parameters:

Slice thickness: 3-5 mm

b-values: Typically 0 and 1000 sec/mm<sup>2</sup>

Use: Evaluates tissue diffusion characteristics, which can help in identifying acute conditions such as infections, abscesses, or acute ischemia.

### **5-Gradient Echo (GRE) Sequences:**

Parameters:

Slice thickness: 3-5 mm

Use: Sensitive to blood products and hemorrhage, making it useful for detecting vascular abnormalities or hemosiderin deposits.

### **6-3D T1-Weighted Imaging with Fat Saturation:**

Parameters:

High-resolution isotropic imaging

TR and TE similar to T1-weighted sequences

Use: Provides excellent anatomical detail and helps in evaluating vascular structures and postoperative changes in the cervical spine.

These MRI sequences are tailored to assess the cervical spine and surrounding structures, allowing for the diagnosis and evaluation of various conditions, including disc herniations, spinal cord compression, infections, trauma, and degenerative changes. The selection of sequences may vary based on clinical indications and the suspected pathology, and consultation with a radiologist or spine specialist is essential for determining the appropriate cervical spine MRI protocol

## References:

## المصادر:

Handbook of MRI Technique Catherine Senior 5<sup>TH</sup> EDITION 2022  
Step by step MRI Jagannmohan Reddy v parsed

Mriquestions.com

Essential of body MRI 2018

الجامعة التقنية الوسطى

كلية التقنيات الصحية والطبية/ بغداد

قسم: تقنيات الاشعة المادة: التصوير بالرنين المغناطيسي  
المرحلة: الرابعة

**Title:** MRI of the thoracic and lumbar spine. **العنوان:**

**Name of the instructor:** اسم المحاضر:

م. حيدر عبد القادر طاهر

lecturer. Haydar Abdul Kader Taher

**Target population:** الفئة المستهدفة:

طلبة المرحلة الرابعة في قسم تقنيات الاشعة

## Introduction:

## المقدمة:

Dorsal and lumbar spine MRI is an important imaging technique that MRI technologists need to learn about for several reasons:

- It is a common MRI procedure. Dorsal and lumbar spine MRIs are among the most common MRI procedures performed. This is because the lower back is a common site of pain and injury.
- It is a complex procedure. Dorsal and lumbar spine MRI can be a complex procedure, as it requires the patient to be positioned in a specific way and the MRI technician to be able to identify and image a variety of anatomical structures.
- It is important for diagnosing a variety of conditions. Dorsal and lumbar spine MRI can be used to diagnose a variety of conditions, including disc herniations, spinal stenosis, spinal cord injuries, and tumors.
- It is important for monitoring the course of treatment. Dorsal and lumbar spine MRI can be used to monitor the course of treatment for a variety of conditions, such as disc herniations and spinal stenosis.

## Scientific Content:

## المحتوى العلمي:

### Thoracic Spine

#### *Common indications*

- Thoracic disc disease
- Thoracic cord compression
- Visualization of a MS plaque in the thoracic cord
- Thoracic cord tumour
- To visualize the inferior extent of cervical syrinx

### ***Equipment***

- Posterior spinal coil/multi-coil array spinal coil
- Pe gating leads if required
- Earplugs/headphones

### ***Patient positioning***

The patient lies supine on the examination couch with the spinal coil extending from the top of the shoulders to the lower costal margin to ensure total coverage of the thoracic spine and conus. The patient is positioned so that the longitudinal alignment light lies in the midline, and the horizontal alignment light passes through the centre of the coil, which corresponds approximately to the level of the fourth thoracic vertebra. Pe gating leads are attached if required.

## **Lumbar spine**

### ***Common indications***

- Disc prolapse with cord or nerve root compression
- Spinal dysraphism (to assess cord termination, syrinx, diastematomyelia)
- Discitis
- Evaluation of the conus in patients with appropriate symptoms
- Failed back syndrome
- Arachnoiditis

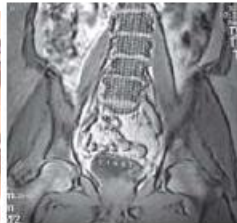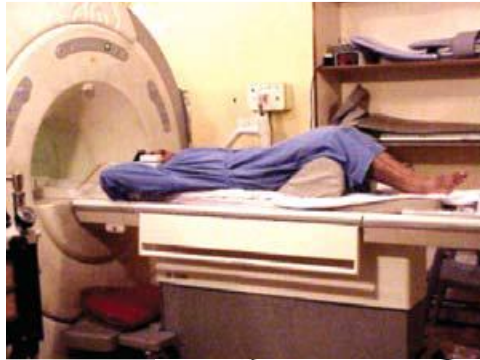### ***Equipment***

- Posterior spinal coil/multi-coil array spinal coil
- Foam pads to elevate the knees
- Earplugs/headphones

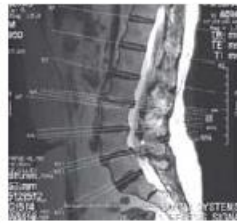### ***Patient positioning***

The patient lies supine on the examination couch with their knees elevated over a foam pad, for comfort and to flatten the lumbar curve so that the spine lies nearer to the coil. The coil should extend from the xiphisternum to the bottom of the sacrum for adequate coverage of the lumbar region. The patient is positioned so that the longitudinal alignment light lies in the midline, and the horizontal alignment light passes just below the lower costal margin, which corresponds to the third lumbar vertebra. Depending on the particular coil configuration, the patient may be placed either head first or feet first. If the patient is anxious or claustrophobic, when/if possible, the feet-first position may be better tolerated.

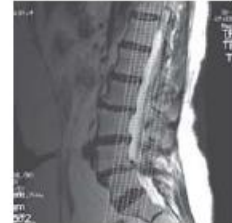



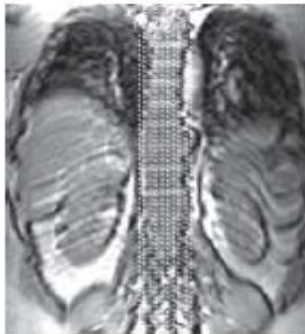Coronal localizer for sagittal slices



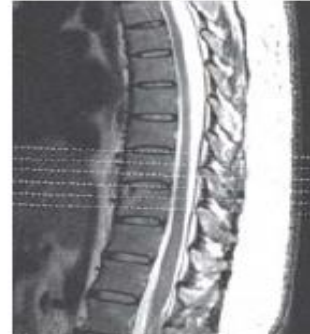Sagittal image of the lumbar spine showing axial oblique slice prescription



Sagittal localizer for coronal slices



Coronal localizer for sagittal slices



Sagittal image of the dorsal spine showing axial oblique slice positions parallel to each disk space

## Main MRI sequences of thoracic and lumbar spine:

### Thoracic Spine Sequences:

#### 1. Sagittal T1-Weighted Imaging:

- Parameters:
  - Slice thickness: 3-5 mm
- Use: Provides an anatomical overview of the thoracic spine, including vertebral bodies and intervertebral discs. Useful for assessing degenerative changes and spinal alignment.

## 2. **Sagittal T2-Weighted Imaging:**

- Parameters:
  - Slice thickness: 3-5 mm
- Use: Highlights soft tissues, spinal cord, and surrounding structures. Helps identify disc herniations, spinal stenosis, and ligamentous injuries.

## 3. **Axial T1-Weighted Imaging:**

- Parameters:
  - Slice thickness: 3-5 mm
- Use: Provides cross-sectional images of the thoracic spine, aiding in the assessment of the spinal cord and nerve roots.

## 4. **Axial T2-Weighted Imaging:**

- Parameters:
  - Slice thickness: 3-5 mm
- Use: Visualizes the spinal cord and nerve roots in axial sections, helping to detect pathology such as disc herniations and spinal cord compression.

## 5. **Sagittal Short Tau Inversion Recovery (STIR) Imaging:**

- Parameters:
  - Slice thickness: 3-5 mm
- Use: Suppresses fat signal and enhances the visibility of edema and inflammatory changes, useful for detecting bone marrow disorders and infection.

## Lumbar Spine Sequences:

### 1. Sagittal T1-Weighted Imaging:

- Parameters (similar to thoracic spine):
- Use: Provides an anatomical overview of the lumbar spine, including vertebral bodies and intervertebral discs. Useful for assessing degenerative changes and spinal alignment.

### 2. Sagittal T2-Weighted Imaging:

- Parameters (similar to thoracic spine):
- Use: Highlights soft tissues, spinal cord, and surrounding structures. Helps identify disc herniations, spinal stenosis, and ligamentous injuries.

### 3. Axial T1-Weighted Imaging:

- Parameters (similar to thoracic spine):
- Use: Provides cross-sectional images of the lumbar spine, aiding in the assessment of the spinal cord and nerve roots.
- 

### 4. Axial T2-Weighted Imaging:

- Parameters (similar to thoracic spine):
- Use: Visualizes the spinal cord and nerve roots in axial sections, helping to detect pathology such as disc herniations and spinal cord compression.

## 5. Sagittal Gradient Echo (GRE) Imaging:

- Parameters:
  - Slice thickness: 3-5 mm
- Use: Sensitive to blood products and hemorrhage, making it useful for detecting vascular abnormalities or hemosiderin deposits.

## 6. 3D T1-Weighted Imaging with Fat Saturation:

- Parameters:
  - High-resolution isotropic imaging
  - TR and TE similar to T1-weighted sequences
- Use: Provides excellent anatomical detail and helps in evaluating vascular structures and postoperative changes in the lumbar spine.

These MRI sequences are tailored to assess the thoracic and lumbar spine and surrounding structures, allowing for the diagnosis and evaluation of various conditions, including disc herniations, spinal stenosis, infections, tumors, and degenerative changes. The selection of sequences may vary based on clinical indications and the suspected pathology, and consultation with a radiologist or spine specialist is essential for determining the appropriate MRI protocol.

## References:

المصادر:

**Handbook of MRI Technique Catherine Senior 5<sup>TH</sup> EDITION 2022**  
**Step by step MRI Jagannohan Reddy v parsed**

**Mriquestions.com**

**Essential of body MRI 2018**

الجامعة التقنية الوسطى  
كلية التقنيات الصحية والطبية/ بغداد  
قسم: تقنيات الاشعة المادة: التصوير بالرنين المغناطيسي  
المرحلة: الرابعة

**Title: MRI of the neck.** العنوان:

**Name of the instructor:** اسم المحاضر:

م. حيدر عبد القادر طاهر

lecturer. Haydar Abdul Kader Taher

**Target population:** الفئة المستهدفة:

طلبة المرحلة الرابعة في قسم تقنيات الاشعة

**Introduction:** المقدمة:

MRI of the brachial plexus is a non-invasive imaging technique that uses a strong magnetic field and radio waves to produce detailed images of the nerves and other structures in the brachial plexus. The brachial plexus is a network of nerves that supplies the upper limbs with sensory and motor function

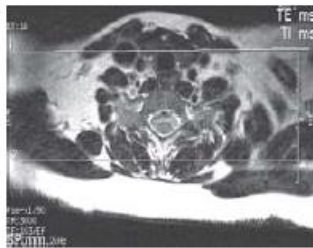
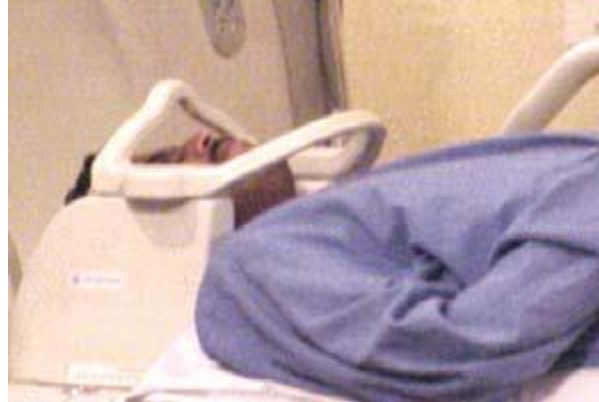**Scientific Content:** المحتوى العلمي:

#### Indication

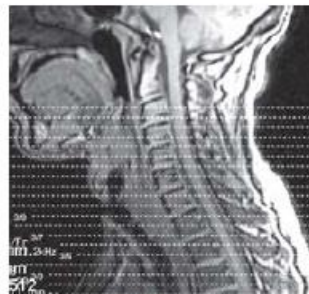
- Diagnosis and characterization of brachial plexus lesions, especially those secondary to carcinoma of the breast and the bronchus
- Thoracic outlet syndrome
- evaluation of the brachial plexus following trauma

### **Patient Position-CTL top**

- Place the coil on the magnet table and plug it in.
- Place patient supine, head first. Rest the head and neck in the coil.
- Position the superior end of the coil at the base of the skull. This position should include C1 on a sagittal image so that you can count vertebra for localization purpose.



Axial localizer for Brachial Plexus showing correct Placement of the first and last slices of the coronal series



Sagittal localizer for axial slices

### **Brachial Plexus Sequences:**

#### **1. Axial T1-Weighted Imaging:**

- **Parameters:**
  - **Slice thickness: 3-5 mm**
- **Use: Provides anatomical information of the brachial plexus and surrounding structures. Useful for detecting mass lesions and structural abnormalities.**

## **2. Axial T2-Weighted Imaging:**

- **Parameters:**
  - **Slice thickness: 3-5 mm**
- **Use: Highlights soft tissues within the brachial plexus, aiding in the identification of nerve compression, tumors, and inflammatory changes.**

## **3. Coronal STIR Imaging:**

- **Parameters:**
  - **Slice thickness: 3-5 mm**
- **Use: Provides multiplanar visualization of the brachial plexus and is particularly helpful for detecting inflammatory conditions, such as brachial plexitis.**

## **4. Diffusion-Weighted Imaging (DWI):**

- **Parameters:**
  - **Slice thickness: 3-5 mm**
  - **b-values: Typically 0 and 1000 sec/mm<sup>2</sup>**
- **Use: Assesses tissue diffusion characteristics, which can aid in identifying nerve abnormalities, injuries, or tumors within the brachial plexus.**

## **5. 3D Fat-Suppressed Imaging:**

- **Parameters:**
  - **High-resolution isotropic imaging**
  - **TR and TE similar to T1- or T2-weighted sequences**

- **Use:** Provides detailed anatomical images and helps in evaluating the entire course of the brachial plexus, especially in cases of traumatic injuries or suspected tumors.

These MRI sequences are tailored to assess the thoracic spine and brachial plexus, allowing for the diagnosis and evaluation of various conditions, including spinal cord compression, disc herniations, inflammatory disorders, nerve injuries, and tumors. The selection of sequences may vary based on clinical indications and the suspected pathology, and consultation with a radiologist or specialist is essential for determining the appropriate MRI protocol.

## **References:**

المصادر:

**Handbook of MRI Technique Catherine Senior 5<sup>TH</sup> EDITION 2022**  
**Step by step MRI Jaganmohan Reddy v parsed**

**Mriquestions.com**

**Essential of body MRI 2018**



الجامعة التقنية الوسطى  
كلية التقنيات الصحية والطبية/ بغداد  
قسم: تقنيات الاشعة المادة: التصوير بالرنين المغناطيسي  
المرحلة: الرابعة

**Title: MRI of the chest (lung + mediastinum).** العنوان:

**Name of the instructor:** اسم المحاضر:

م. حيدر عبد القادر طاهر

lecturer. Haydar Abdul Kader Taher

**Target population:** الفئة المستهدفة:

طلبة المرحلة الرابعة في قسم تقنيات الاشعة

**Introduction:** المقدمة:

MRI (Magnetic Resonance Imaging) of the chest, including the lungs and mediastinum, can be valuable in certain clinical scenarios, but it is less commonly used compared to other imaging modalities like CT (Computed Tomography) for this region. MRI is particularly useful when radiation

exposure needs to be minimized or when specific soft tissue characterization is required.

## Scientific Content: المحتوى العلمي:

### Common indications

- Mediastinal lymphadenopathy
- Central and superior sulcus bronchial tumours
- Distinction between neoplasm and consolidated lung
- Alternative to CT of the mediastinum and chest wall when the patient is hypersensitive to contrast medium
- Vascular evaluation of aortic dissection, pulmonary embolus, aortic aneurysm or vascular stenosis
- Lung perfusion studies
- Assessment of diaphragmatic motion
- Chest wall infections
- Pleural disease
- Rib lesions or metastases

### *Equipment*

- Body coil/volume torso multi-coil array
- RC bellows
- ECG or peripheral gating leads
- Earplugs/headphones

### *Patient positioning*

The patient lies supine on the examination couch with the RC bellows (if required) and ECG gating leads attached. Pads can be placed under the patient's knees (for comfort) and beside the patient's elbows (for optimal MR imaging). In some cases, if the patient is not comfortable supine and/or if the patient has trouble in confined spaces, prone positioning may be a suitable alternative.

The patient is positioned so that the longitudinal alignment light lies in the midline, and the horizontal alignment light passes through the level of the fourth thoracic vertebra, or the nipples. The patient can be placed feet first into the magnet if the ECG trace is unsatisfactory as this changes the patient's polarity relative to the main field (see *Gating and respiratory*

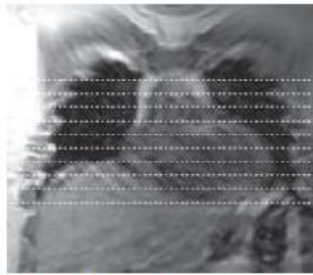
compensation techniques in Part 1).




Placement of the gating leads



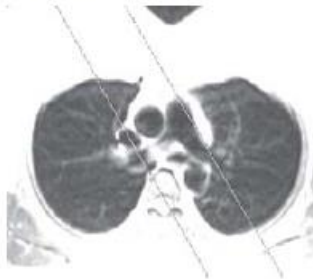Patient position: Torso array coil  
Place the patient supine, feet first on the table.



Coronal localizer for axial slices



Coronal localizer for sagittal slices



Axial image through the ascending and descending Aorta showing correct placement of the first and last oblique slices for examining the arch of aorta

## **Main MRI Sequences for Chest Imaging:**

### **1. T1-Weighted Imaging:**

- Parameters:
  - Slice thickness: 5-8 mm
- Use: Provides detailed anatomical information, including visualization of chest structures such as the heart, main vessels, and mediastinum.
- 

### **2. T2-Weighted Imaging:**

- Parameters:
  - Slice thickness: 5-8 mm
- Use: Highlights differences in tissue water content, making it useful for identifying areas of inflammation, edema, or abnormal tissue within the chest.

### **3. Fat Suppression Sequences:**

- Parameters:
  - Utilizes fat saturation techniques
- Use: Helps distinguish between fat-containing and non-fat tissues, aiding in the assessment of lesions and structures within the chest.

### **4. Diffusion-Weighted Imaging (DWI):**

- Parameters:
  - Slice thickness: 5-8 mm
  - b-values: Typically, 0 and 1000 sec/mm<sup>2</sup>
- Use: Measures the diffusion of water molecules in tissues and can be helpful in assessing tissue cellularity and identifying certain chest lesions.

## **5. Dynamic Contrast-Enhanced Imaging:**

- Parameters:
  - Slice thickness: 5-8 mm
  - Temporal resolution: 5-10 seconds
  - Contrast agent: Gadolinium-based contrast agent
- Use: Evaluates tissue perfusion and can help in characterizing lesions based on their vascularity, particularly useful for assessing vascular lesions and tumors.

## **6. Magnetic Resonance Angiography (MRA):**

- Parameters:
  - Slice thickness: 1-2 mm
- Use: Visualizes blood vessels within the chest, including the main arteries and veins, and can be used to detect vascular abnormalities.

## **References:**

**المصادر:**

**Handbook of MRI Technique Catherine Senior 5<sup>TH</sup> EDITION 2022**  
**Step by step MRI Jagannohan Reddy v parsed**

**Mriquestions.com**

**Essential of body MRI 2018**

الجامعة التقنية الوسطى

كلية التقنيات الصحية والطبية/ بغداد

قسم: تقنيات الاشعة  
المادة: التصوير بالرنين المغناطيسي  
المرحلة: الرابعة

**Title: MRI of the abdomen (renal + liver + spleen + bowel).**  
العنوان:

**Name of the instructor:** اسم المحاضر:

م. حيدر عبد القادر طاهر

lecturer. Haydar Abdul Kader Taher

**Target population:** الفئة المستهدفة:

طلبة المرحلة الرابعة في قسم تقنيات الاشعة

**Introduction:** المقدمة:

learning about abdomen MRI is essential for MRI technologist to perform MRI exams effectively, interpret MRI results accurately, ensure patient safety, understand anatomy and pathology, and collaborate with other healthcare professionals. MRI technologist can acquire this knowledge through specialized training programs, continuing education courses, and on-the-job experience.

## **Liver and biliary system**

### **Common indications**

- Focal lesions and staging of neoplasms
- Benign hepatic disease, especially haemangioma and focal nodular hyperplasia
- Haemochromatosis
- Gallbladder disease
- Biliary duct obstruction
- Evaluation of liver infiltrants such as iron or fat

### ***Equipment***

- Body coil/volume torso array or multi-coil
- RC bellows
- Earplugs/headphones
- Pe gating leads if required

### ***Patient positioning***

The patient lies supine on the examination couch with the RC bellows (if required) securely attached. The patient is positioned so that the longitudinal alignment light lies in the midline, and the horizontal alignment light passes through the level of the third lumbar vertebra, or the lower costal margin.

## **Kidneys and adrenal glands**

### ***Common indications***

- Adrenal masses and haemorrhage
- Renal masses and haemorrhage
- Renal cell carcinoma
- Renal transplant rejection
- Ureteric obstruction

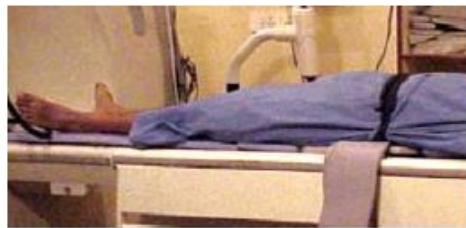### ***Equipment***

- Body coil/multi-phased array or multi-coil array

- RC bellows
- Earplugs/headphones

### ***Patient positioning***

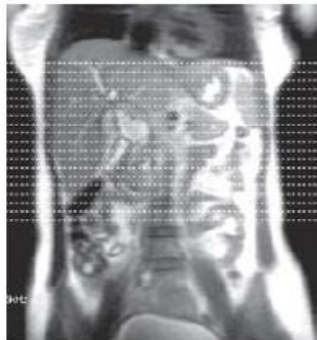The patient lies supine on the examination couch with the RC bellows securely attached (if required). The patient is positioned so that the longitudinal alignment light lies in the midline, and the horizontal alignment light passes through the level of the third lumbar vertebra, or the lower costal margin. The kidneys are generally located about four fingers inferior to the xiphoid.



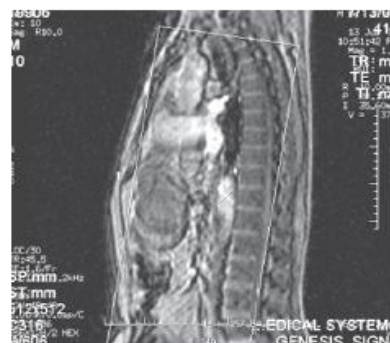Placement of the respiratory compensation (RC) bellows



Patient Position- Torso array coil



Coronal localizer for axial slices



Sagittal localizer to obtain coronal slices

### **Main Abdominal MRI Sequences:**

1. T1-Weighted Imaging:
  - Parameters:



- Slice thickness: 5-8 mm
- Use: Provides detailed anatomical information of abdominal structures, including the liver, spleen, kidneys, and blood vessels. T1-weighted images are helpful for detecting anatomy and lesions.

## 2. T2-Weighted Imaging:

- Parameters:
  - Slice thickness: 5-8 mm
- Use: Highlights differences in tissue water content, aiding in the identification of lesions, inflammation, and structural abnormalities within the abdomen.

## 3. Fat Suppression Sequences:

- Parameters:
  - Utilizes fat saturation techniques
- Use: Helps differentiate between fat-containing and non-fat tissues, which can be useful for characterizing lesions and assessing fatty infiltration of organs.

## 4. Diffusion-Weighted Imaging (DWI):

- Parameters:
  - Slice thickness: 5-8 mm
  - b-values: Typically 0 and 800-1000 sec/mm<sup>2</sup>
- Use: Measures the diffusion of water molecules in tissues and can assist in the evaluation of tissue cellularity and identifying certain abdominal lesions, including tumors.

## 5. Dynamic Contrast-Enhanced Imaging:

- Parameters:
  - Slice thickness: 5-8 mm
  - Contrast agent: Gadolinium-based contrast agent
- Use: Evaluates tissue perfusion and vascularity, aiding in the characterization of lesions, particularly for detecting and characterizing liver lesions.

## 6. Gradient Echo (GRE) Sequences:

- Parameters:
  - Slice thickness: 5-8 mm
- Use: Sensitive to blood products and hemorrhage, making it useful for detecting vascular abnormalities, such as hemangiomas or vascular malformations.

## **Main Renal MRI Sequences:**

### 1. **T1-Weighted Imaging:**

- Parameters:
  - Slice thickness: 3-5 mm
- Use: Provides detailed anatomical information of the kidneys and surrounding structures. T1-weighted images help detect renal anatomy and lesions.

### 2. **T2-Weighted Imaging:**

- Parameters:
  - Slice thickness: 3-5 mm

- Use: Highlights differences in tissue water content, aiding in the identification of renal lesions, inflammation, and structural abnormalities.

### 3. **Fat Suppression Sequences:**

- Parameters:
  - Utilizes fat saturation techniques
- Use: Helps differentiate between fat-containing and non-fat tissues in and around the kidneys, aiding in characterizing lesions and assessing fatty infiltration of renal structures.

### 4. **Diffusion-Weighted Imaging (DWI):**

- Parameters:
  - Slice thickness: 3-5 mm
  - b-values: Typically 0 and 800-1000 sec/mm<sup>2</sup>
- Use: Measures the diffusion of water molecules in renal tissues and can assist in the evaluation of tissue cellularity and identifying renal lesions, including tumors and abscesses.

### 5. **Dynamic Contrast-Enhanced Imaging:**

- Parameters:
  - Slice thickness: 3-5 mm
  - Contrast agent: Gadolinium-based contrast agent
- Use: Evaluates renal perfusion, vascularity, and enhancement patterns, which can be valuable for detecting and characterizing renal lesions, including renal cell carcinoma.

6. **Magnetic Resonance Angiography (MRA):**

- Parameters:
  - Slice thickness: 1-2 mm
- Use: Visualizes renal arteries and veins, making it useful for assessing renal vascular conditions, such as renal artery stenosis or aneurysms.

**References:**

المصادر:

**Handbook of MRI Technique Catherine Senior 5<sup>TH</sup> EDITION 2022**  
**Step by step MRI Jagannohan Reddy v parsed**

**Mriquestions.com**

**Essential of body MRI 2018**