

Classification system for completely edentulous patients

The American College of Prosthodontists (ACP) has developed a classification system for complete edentulism based on diagnostic findings. These guidelines may help practitioners determine appropriate treatments for their patients.

Four categories are defined, ranging from Class I to Class IV, with Class I representing an uncomplicated clinical situation and a Class IV patient representing the most complex and higher risk situation. Each class is differentiated by specific diagnostic criteria.

This system is designed for use by dental professionals who are involved in the diagnosis of patients requiring treatment for complete edentulism.

Potential benefits of the system include:

1. Better patient care.
2. Improved professional communication.
3. More appropriate insurance reimbursement.
4. A better screening tool to assist dental school admission clinics.
5. Standardized criteria for outcomes assessment.

Completely edentulous patients exhibit a broad range of physical variations and health concerns. Classifying all edentulous patients as a single diagnostic group is insensitive to the multiple levels of physical variation and the differing treatment procedures required restoring function and comfort.

A graduated classification of complete edentulism has been developed that describes varying levels of loss of denture supporting structures.

Complete edentulism defines as follows: the physical state of the jaw(s) following removal of all erupted teeth and the condition of the supporting structures available for reconstructive or replacement therapies.

Edentulism, is total tooth loss, is more prevalent among persons with less than a high school education, those without dental insurance, non-Hispanic blacks, and current everyday smokers.

Development of the classification system: A review of the prosthetic literature was used to identify the many variables associated with complete edentulism. These variables were differentiated into four subclasses:

1. Physical findings.
2. Prosthetic history.
3. Pharmaceutical history.
4. Systemic disease evaluation.

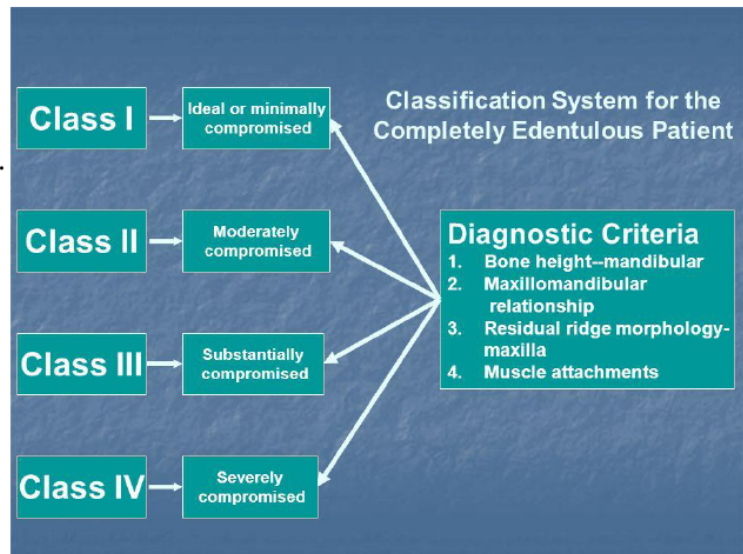
A classification system was developed based on the most objective variables. The classification system will be subject to monitoring and revision as new diagnostic and treatment information becomes available in the literature.

Diagnostic Criteria

The diagnostic criteria are organized by their objective nature and not in their rank of significance. Because of variations in adaptive responses, certain criteria are more significant than others. However, objective criteria will allow for the most accurate application of the classification system and measurement of its efficacy.

The diagnostic criteria used in the classification system are:

1. Bone height-mandible.
2. Maxillomandibular relationship.
3. Residual ridge morphology-maxilla.
4. Muscle attachments-mandible.

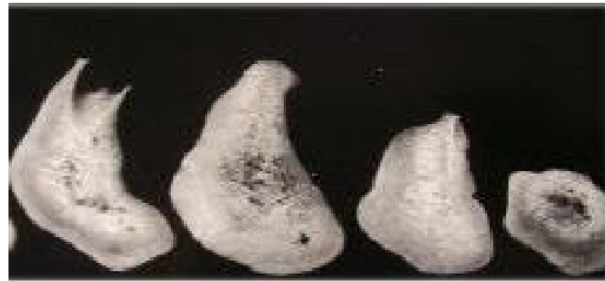

1. Bone height-mandible.

The identification and measurement of residual bone height is the most easily quantified objective criterion for the mandibular edentulous ridge. In addition, it represents a measurement of the chronic debilitation associated with complete edentulism in the mandible. Despite the lack of a known etiology, it has been established that the loss of denture supporting structures does occur. Atwood's description in 1971 of alveolar bone loss is still applicable today: "Chronic progressive, irreversible and disabling process probably of multifactorial origin. At the present time, the importance of various cofactors is unknown."

The continued decrease in bone volume affects:

1. Denture-bearing area.
2. Tissues remaining for reconstruction.
3. Facial muscle support/attachment.
4. Total facial height.
5. Ridge morphology.



The results of a radiographic survey of residual bone height measurement are affected by the variation in the radiographic techniques and magnification of panoramic machines of different manufacturers. To minimize variability in radiographic techniques, the measurement should be made on the radiograph at that portion of the mandible of the least vertical height. The values assigned to each of the four types listed below are averages that historically have been used in relation to preprosthetic surgical procedures.

A measurement is made and the patient is classified as follows:

Type I: (most favourable): residual bone height of 21mm or greater measured at the least vertical height of the mandible.

Type II: residual bone height of 16 to 20 mm measured at the least vertical height of the mandible.

Type III: residual alveolar bone height of 11 to 15mm measured at the least vertical height of the mandible.

Type IV: residual vertical bone height of 10 mm or less measured at the least vertical height of the mandible.

2. Residual ridge morphology-maxilla only:

Residual ridge morphology is the most objective criterion for the maxilla, because measurement of the maxillary residual bone height by radiography is not reliable." The classification system continues on a logical progression, describing the effects of residual ridge morphology and the influence of musculature on a maxillary denture.

Type A (most favorable):

1. Anterior labial and posterior buccal vestibular depth that resists vertical and horizontal movement of the denture base.
2. Palatal morphology resists vertical and horizontal movement of the denture base.
3. Sufficient tuberosity definition to resist vertical and horizontal movement of denture base.
4. Hamular notch is well defined to establish the posterior extension of the denture base.
5. Absence of tori or exostoses.

Type B: 1. Loss of posterior buccal vestibule.

2. Palatal vault morphology resists vertical and horizontal movement of the denture base.
3. Tuberosity and hamular notch are poorly defined, compromising delineation of the posterior extension of the denture base.
4. Maxillary palatal tori and/or lateral exostoses are rounded and do not affect the posterior extension of the denture base.

Type C: 1. Loss of anterior labial vestibule.

2. Palatal vault morphology offers minimal resistance to vertical and horizontal movement of the denture base.
3. Maxillary palatal tori and/or lateral exostoses with bony undercuts that do not affect the posterior extension of the denture base.
4. Hyperplastic, mobile anterior ridge offers minimum support and stability of denture base.
5. Reduction of the post malar space by the coronoid process during mandibular opening and/or excursive movements.

Type D:

1. Loss of anterior labial and posterior buccal vestibules.
2. Palatal vault morphology does not resist vertical or horizontal movement of the denture base.
3. Maxillary palatal tori and/or lateral exostoses"(rounded or undercut) that interfere with the posterior border of the denture.
4. Hyperplastic, redundant anterior ridge.
5. Prominent anterior nasal spine.

3. Muscle Attachments :(only mandible)

The effects of muscle attachment and location are most important to the function of a mandibular denture. These characteristics are difficult to quantify. The classification system follows a logical progression to describe the effects of muscular influence on a mandibular denture. The clinician examines the patient and selects the category that is most descriptive of the mandibular muscle attachments.

Type A (most favorable):

1. Attached mucosal base without undue muscular impingement during normal function in all regions.

Type B: 1. Attached mucosal base in all regions except labial from canine to canine.

2. Mentalis muscle attachment near crest of alveolar vestibule ridge.

Type C:

1. Attached mucosal base in all regions except anterior buccal and lingual vestibules-canine to canine.
2. Genioglossus and mentalis muscle attachments near crest of alveolar ridge.

Type D: 1. Attached mucosal base only in the posterior lingual region.

2. Mucosal base in all other regions is detached.

Type E: No attached mucosa in any region.

4. Maxillomandibular Relationship:

The classification of the maxillomandibular relationship characterizes the position of the artificial teeth in relation to the residual ridge and/or to opposing dentition. Examine the patient and assign a class as follows:

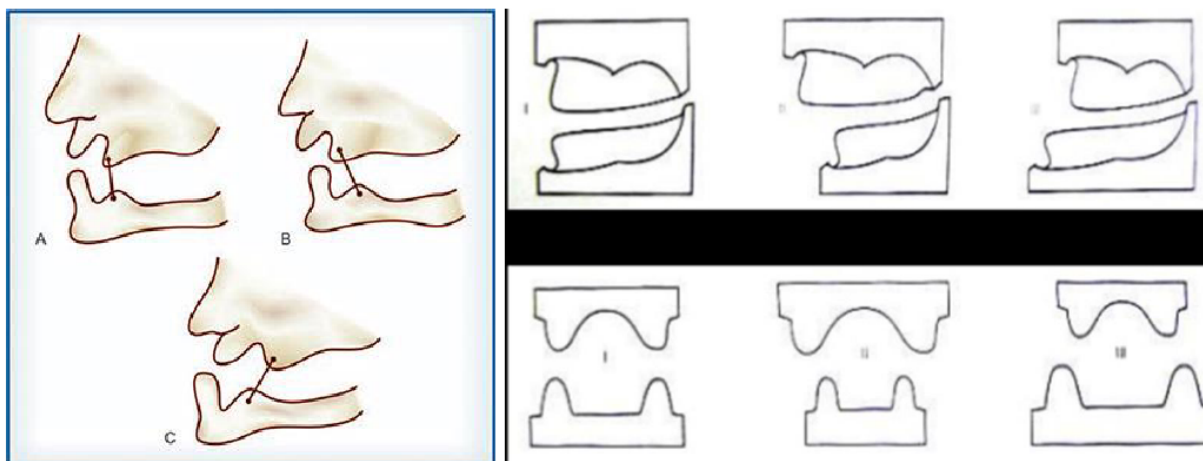
Class I (most favorable): Maxillomandibular relation allows tooth position that has normal articulation with the teeth supported by the residual ridge.

Class II: Maxillomandibular relation requires tooth position outside the normal ridge relation to attain esthetics, phonetics, and articulation (e.g., anterior or posterior tooth position is not supported by the residual ridge; anterior vertical and/or horizontal overlap exceeds the principles of fully balanced articulation).

Class III: Maxillomandibular relation requires tooth position outside the normal ridge relation to attain esthetics, phonetics, and articulation (i.e. cross bite-anterior or posterior tooth position is not supported by the residual ridge).

Integration of Diagnostic Findings:

The previous four sub classifications are important determinants in the overall diagnostic classification of complete edentulism. In addition, variables that can be expected to contribute to increased treatment difficulty are distributed across all classifications according to their significance.



Arrangement of artificial teeth in abnormal jaw relations:**Maxillary protrusion and wider upper arch (class II jaw relation).****a. Arrangement of anterior teeth in maxillary protrusion:**

As the upper arch in these situations is further forward in the anterior region, the first problem is that of an excessive amount of overjet which results in an abnormal upper and lower canine tooth relationship. No attempt should be made to reduce this horizontal overlap by moving the upper anterior teeth palatally or the lower anterior teeth labially.

Management: The management of such situation can be attempted in any of the following ways, depending upon the severity of the maxillary protrusion.

1. If the protrusion is not too extreme, the simplest way is to select the lower anterior teeth of a narrower mesiodistal width and try to achieve the normal canine relationship.
2. If esthetics permit, a little crowding of the lower anterior teeth by overlapping may solve the problem well.
3. Another solution which is effective at times is leave slight spaces between the upper anterior teeth to attain normal canine relations. However, such a procedure is esthetically limited.
4. In situations where the discrepancy is not too great, grinding of the distal surface of lower canine is sufficient to restore the normal canine relationship.
5. In situations where the discrepancy is excessive and cannot be managed by the manipulation and modification of the lower anterior teeth, the lower anterior teeth must be left as they are, and the lower first premolars must be eliminated from the dental arch.

b. Arrangement of posterior teeth when upper jaw is wider as in class II jaw relation:

In this situation, the lower crest of the ridge in the posterior region is lingual to the upper residual ridge. This relationship is not very common, but when present, it may give rise to considerable difficulty in the placement of upper and lower teeth in their correct occlusal relationship. In such instances, the upper arch is wider than the lower, and if the upper teeth are placed on the crest of the ridge, they will make inadequate occlusal contact with the correctly placed lower teeth. At the same time, if an attempt is made to occlude the lower teeth with the correctly placed upper teeth, the lower teeth will place too far buccally leading

to instability of the lower denture. This is much more detrimental as the lower denture-bearing area is already very small.

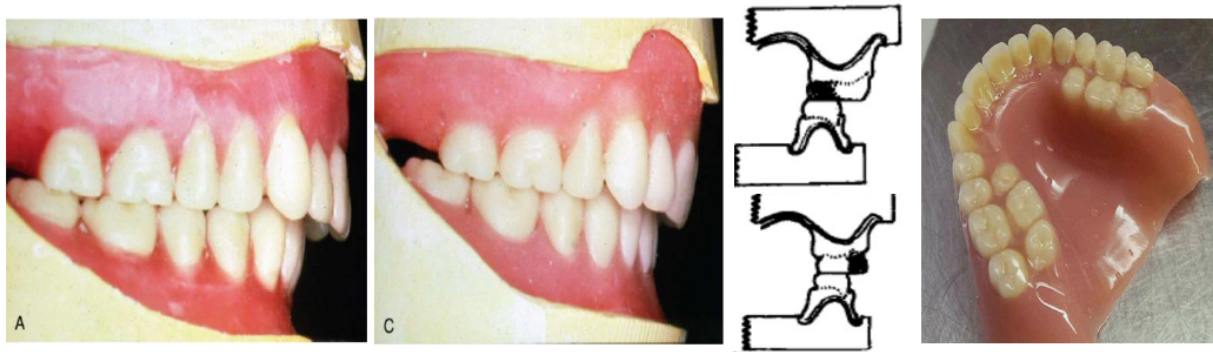
Management: The following methods of correction may be employed:

(1) If the discrepancy is very slight, the upper teeth are moved slightly in a palatal direction to provide a working occlusal contact with the lower teeth. However, such a procedure has a very limited application as the upper posterior teeth cannot be moved inside (palatally) to any great extent without affecting phonetics and cheek support.

(2) If the upper arch is much wider than the lower one, any of the following methods can be used successfully:

(a) The lower posterior teeth are correctly placed on the crest of the ridge. The upper teeth are then set so that they occlude well with the lower teeth. Then the buccal contours are built on the upper teeth in wax which is later replaced by tooth-colored acrylic resin to fulfill esthetic requirements and to provide support for the cheek.

(b) Another method can be used alternatively for the same problem. The upper posterior teeth are arranged first to meet the requirements of esthetics. The lower teeth are kept on the crest of the ridge. This will result in an unfavorable occlusal relationship of the upper and lower posterior teeth. In order to establish a functional occlusal contact between the upper and lower posterior teeth, wax is added on the palatal aspect of the upper posterior teeth. This wax is later replaced by tooth colored acrylic resin. This gives a functionally effective occlusal contact as well as an esthetically acceptable buccal surface contour of the upper posterior teeth. Nonanatomical posterior teeth are best for these procedures as they allow more freedom in their buccolingual placement.



Mandibular protrusion and wider lower arch (class III jaw relation):**a. Arrangement of anterior teeth in mandibular protrusion:**

This condition is characterized by the lower anterior ridge being forward in relation to the maxillary ridge. This may vary from edge-to-edge relation (where both upper and lower ridges are at the same level) to a marked prognathism (lower ridge is forward to the upper).

Management: These situations can be managed by any of the following methods, depending upon the severity of the mandibular protrusion.

(1) If the ridges are in an edge-to-edge relation, the incisal edges of the upper and lower incisors and cuspids will also meet in edge-to-edge relationship. The upper and lower teeth are placed as near as possible to the labial plates of bone in their respective ridges. No attempt should be made to introduce normal horizontal overlap if ridge relation does not permit it.

(2) With an extreme protrusion of the mandible, a negative or reverse horizontal labial overlap must be used. The lower anterior teeth are placed labial to the upper anterior teeth. The magnitude of the reverse horizontal overlap depends upon the amount of protrusion of the lower residual ridge.

(3) If the difference in ridge size is too great, one of the following methods may be used to solve the problem.

(a) Use a slightly larger lower-tooth mold than that suggested for normal use with the upper teeth. This will compensate for the greater lower-arch width. This is the simplest method.

(b) Use a slight overlapping in the upper anterior teeth, if esthetically acceptable. This will automatically narrow the lower-arch space and may eliminate spacing.

(c) Use an extra lower incisor to avoid the spaces. However, this is hardly an acceptable measure. It is better, esthetically, to leave some spaces between the lower anterior teeth than for the dentures to appear to have too many teeth. The relationship of the upper and lower canines in this situation does not present much of a problem. The lower anterior teeth are set in a forward relation to the upper anterior teeth. The distal surface of the lower canine coincides with the tip of the upper canine. If it finishes mesial to the canine tip, the discrepancy can be rectified by using small spaces between the lower anterior teeth so that the canine teeth will have their normal relationship.

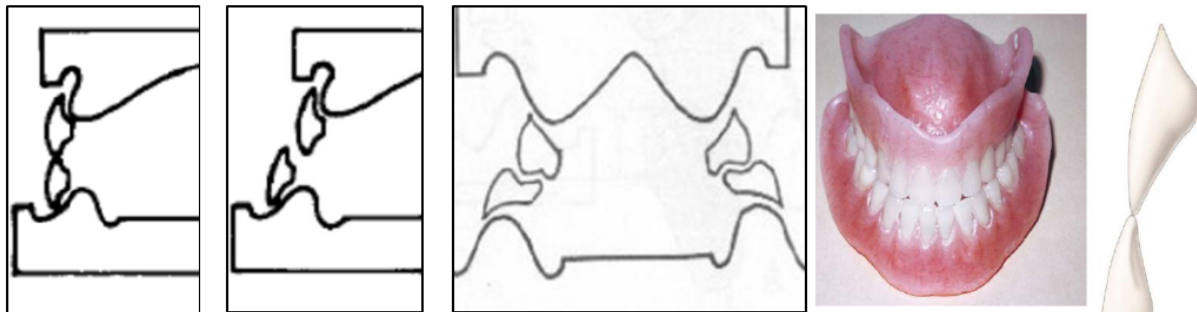
b. Arrangement of posterior teeth when the lower arch is wider:

Management: An arrangement for the posterior cross-bite relationship will depend on the severity of its deviation from normal. One of three procedures may be used.

(1) If the difference in size is slight and the upper ridge is well formed, the upper posterior teeth can be set slightly buccal to the crest of the upper ridge in such a position that correctly placed lower posterior teeth can make effective occlusal contacts with their antagonists. This should not be done to an extent that it introduces potential midline fracture in upper denture.

(2) Nonanatomical teeth may be used. These teeth allow more freedom in their buccolingual placement and still provide an adequate occlusal contact between the upper and lower teeth. The teeth kept on the crests of the respective ridges without losing desired occlusal contacts.

(3) If the lower arch is too wide and cannot be managed otherwise, an interchange can be accomplished by using upper teeth on the lower denture and lower teeth on the upper denture. The interchange is made across the arch as well. The right upper teeth are placed on the left lower ridge, and left lower teeth are placed on the right upper ridge. Similarly, the left upper posterior teeth are set on the right lower ridge, and right lower posterior teeth are placed on the left upper ridge. Start by placing the lower teeth on the upper ridge. As the upper arch is already smaller in these patients, it is imperative that the first premolar tooth be eliminated from the arch to develop correct intercuspals relationships. The second premolar, first molar, and second molar (lower teeth) are set on the upper ridge. The buccal cusps of these teeth correspond to the guideline of the lower occlusal rim. Sometimes a cross-bite setting (i.e., a reverse horizontal buccal overlap) is suggested without interchanging the teeth between the two arches. The success of such an arrangement of teeth is doubtful, as anatomically they are not meant to intercuspate with each other in this relationship. However, it might be attempted if nonanatomical posterior teeth are used.



Classification System for Complete Edentulism:**Integration of Diagnostic Findings**

The previous four sub classifications are important determinants in the overall diagnostic classification of complete edentulism. In addition, variables that can be expected to contribute to increased treatment difficulty are distributed across all classifications according to their significance.

Diagnostic Classification of Complete Edentulism

Class I: This classification level characterizes the stage of edentulism that is most appear to be successfully treated with complete dentures using conventional prosthodontics techniques. All four of the diagnostic criteria are favorable.

- Residual bone height of 21 mm or greater measured at the least vertical height of the mandible on a panoramic radiograph.
- Residual ridge morphology resists horizontal and vertical movement of the denture base; Type A maxilla.
- Location of muscle attachments that are conducive to denture base stability and retention; Type A or B mandible.
- Class I maxillomandibular relationship

Class II: This classification level distinguishes itself by the continued physical degradation of the denture supporting anatomy, and, in addition, is characterized by the early onset of systemic disease interactions, patient management, and/or lifestyle considerations.

- Residual bone height of 16 to 20 mm measured at the least vertical height of the mandible on a panoramic radiograph.
- Residual ridge morphology that resists horizontal and vertical movement of the denture base; Type A or B maxilla.
- Location of muscle attachments with limited influence on denture base stability and retention; Type A or B mandible.
- Class I maxillomandibular relationship.

→ Minor modifiers, psychosocial considerations, mild systemic disease with oral manifestation.

Class III: This classification level is characterized by the need for surgical revision of supporting structures to allow for adequate prosthodontic function. Additional factors now play a significant role in treatment outcomes.

→ Residual alveolar bone height of 11 to 15 mm measured at the least vertical height of the mandible on a panoramic radiograph.

→ Residual ridge morphology has minimum influence to resist horizontal or vertical movement of the denture base; Type C maxilla.

→ Location of muscle attachments with moderate influence on denture base stability and retention; Type C mandible.

→ Class I, II, or III maxillomandibular relationship.

→ Conditions requiring preprosthetic surgery:

1) minor soft tissue procedures;

2) minor hard tissue procedures including alveolotomy.

3) simple implant placement, no augmentation

4) multiple extractions leading to complete edentulism for immediate denture placement.

→ Limited interarch space.

→ Moderate psychosocial consideration and or moderate oral manifestations of systemic diseases or conditions such as xerostomia

→ TMD symptoms present.

→ Large tongue (occludes interdental space) without hyperactivity.

→ Hyperactive gag reflex.

Class IV: This classification level depicts the most debilitated edentulous condition. Surgical reconstruction is almost always indicated but cannot always be accomplished because of the patient's health, preferences, dental history, and financial considerations. When surgical

revision is not an option, prosthodontics techniques of a specialized nature must be used to achieve an adequate treatment outcome.

- Residual vertical bone height of 10 mm or less measured at the least vertical height of the mandible on a panoramic radiograph.
- Residual ridge offers no resistance to horizontal or vertical movement; Type D maxilla.
- Muscle attachment location that can be expected to have significant influence on denture base stability and retention; Type D or E mandible.
- Class I, II, or III maxillomandibular relationships.
- Major conditions requiring preprosthetic surgery:
 - 1) complex implant placement, augmentation
 - 2) surgical correction of dentofacial deformities;
 - 3) hard tissue augmentation required;
 - 4) major soft tissue revision required, ie, vestibular extensions with or without soft tissue grafting.
- History of paresthesia or dysesthesia.
- Insufficient interarch space with surgical correction required.
- Acquired or congenital maxillofacial defects.
- Severe oral manifestation of systemic disease or conditions such as sequelae from oncological treatment.
- Maxillo-mandibular ataxia (incoordination).
- Hyperactivity of tongue that can be associated with a retracted tongue position and/or its associated morphology.
- Hyperactive gag reflex managed with medication.

- Refractory patient (a patient who presents with chronic complaints following appropriate therapy). These patients may continue to have difficulty achieving their treatment expectations despite the thoroughness or frequency of the treatments provided.
- Psychosocial conditions warranting professional intervention

Reasons for a Classification System

Classifying edentulous patients according to present criteria can be an aid in numerous aspects of treatment:

- establishing a basis for diagnostic and treatment procedures
- justifying treatment procedures and fees to patients
- screening patients treated in dental faculties for assignment to undergraduate or graduate students
- providing data for review of treatment outcome
- simplifying communication in discussions of treatment with patients and colleagues.

The classes are differentiated from each other according to the following features:

- The skill level required treating that class of patient: Does the patient require novice or expert treatment?
- The necessity for modification of basic clinical or laboratory procedures: Will more complicated procedures or more time be required for treatment?
- Overall management and complexity of treatment: Will expert intervention and referral be required?

Guidelines for Use of the Complete Edentulism Classification System

In those instances when a patient's diagnostic criteria are mixed between two or more classes, any single criterion of a more complex class places the patient into the more complex class. The analysis of diagnostic factors is facilitated with the use of a worksheet.

Use of this system is indicated for pre-treatment evaluation and classification of patients. Re-evaluation of classification status should be considered following preprosthetic surgery. Retrospective analysis on a post treatment basis may alter a patient's classification.

The classification system for complete edentulism is based on the most objective criteria available to facilitate uniform utilization of the system. With such standardization, communication will be improved among dental professionals.

This classification system will help to identify those patients most likely to require treatment by a specialist or by a practitioner with additional training and experience in advanced techniques. This system should also be valuable to research protocols a different treatment procedures are evaluated.

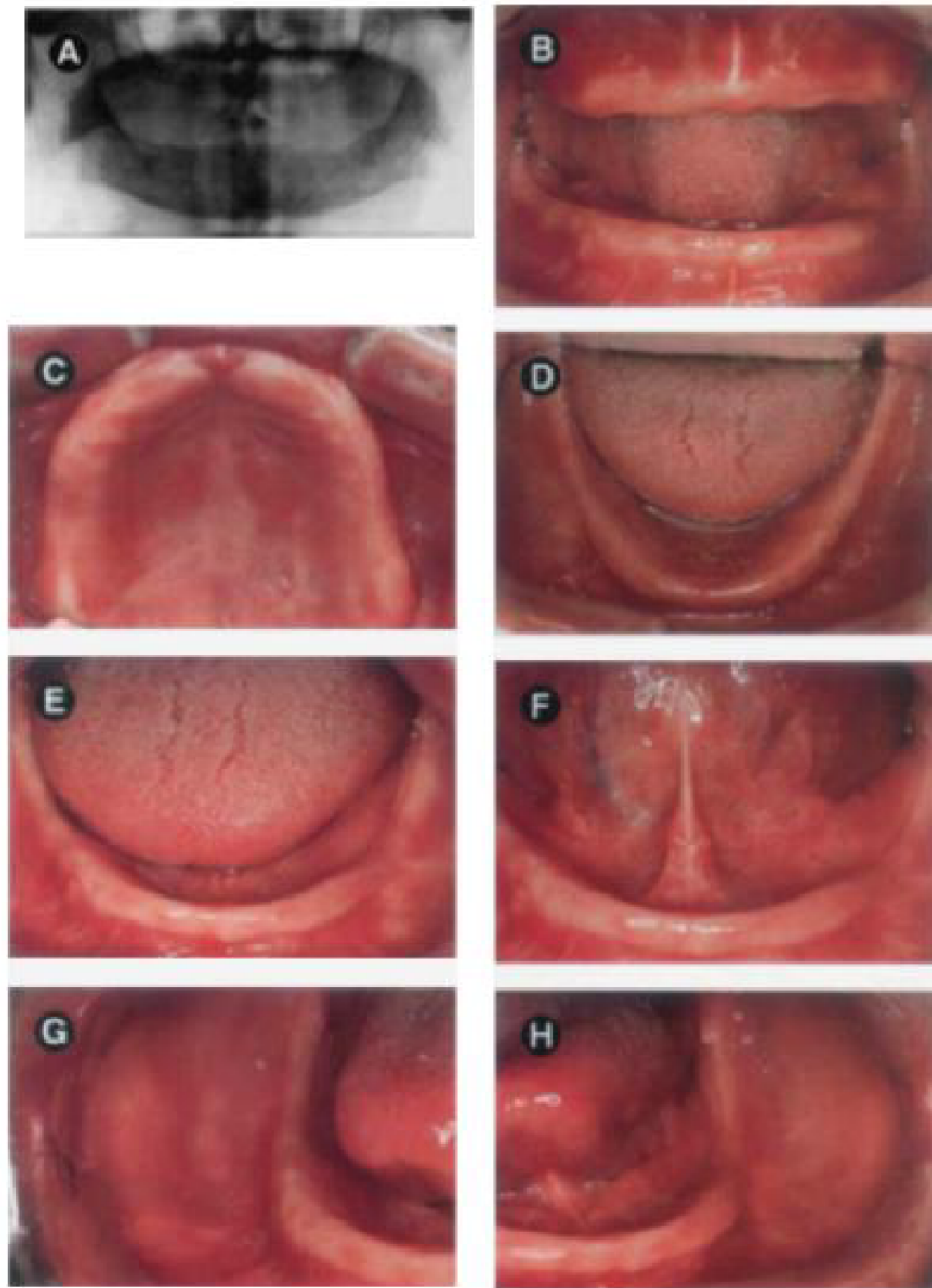


Figure 14. Class I patient. (A) Panoramic radiograph. (B) Facial view at the approximate occlusal vertical dimension. (C) Occlusal view: maxillary arch. (D) Occlusal view: mandibular arch. (E) Facial view: tongue in resting position. (F) Facial view: tongue elevated. (G) Lateral view of mandible: patient right. (H) Lateral view of mandible: patient left.

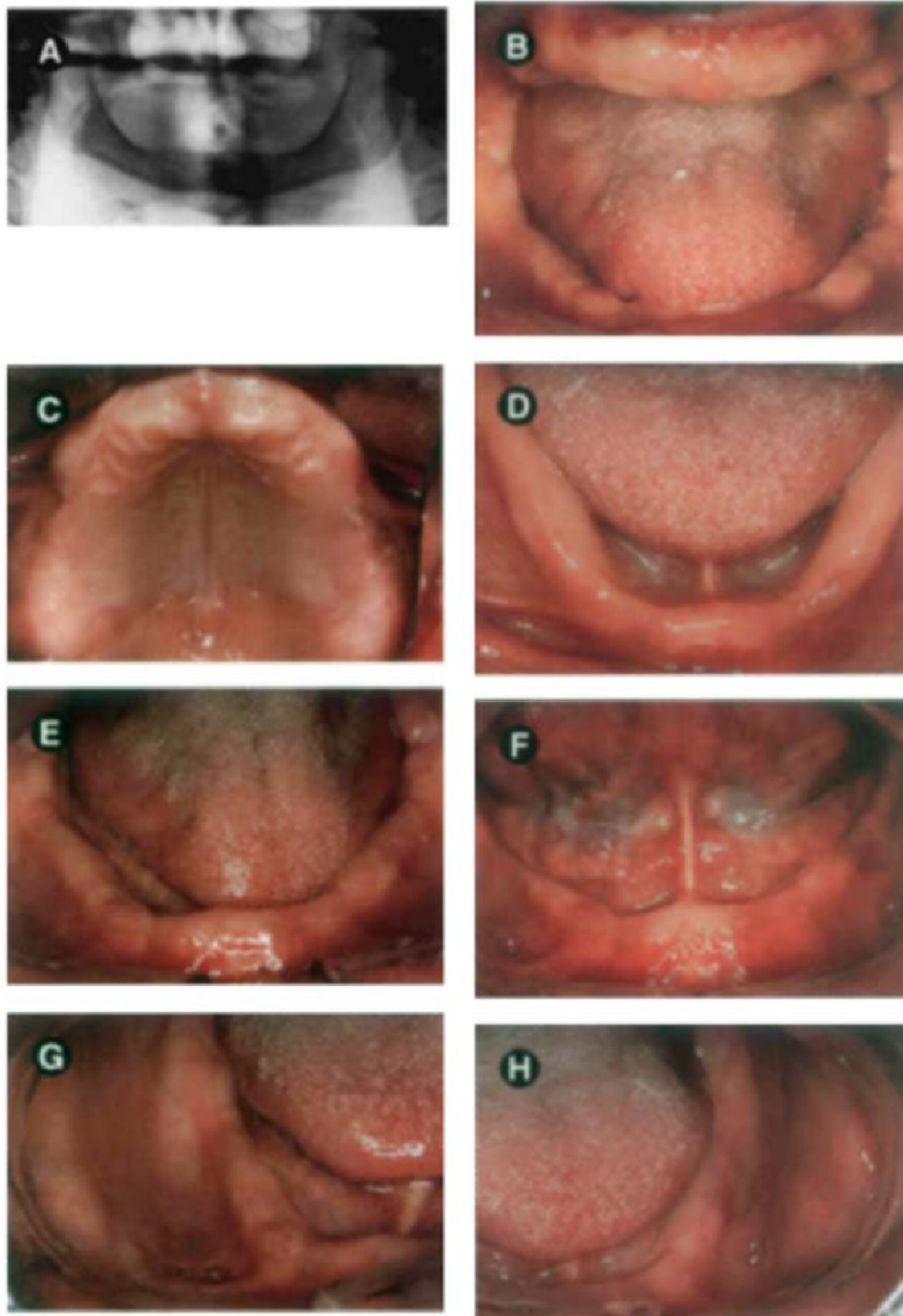


Figure 15. Class II patient. (A) Panoramic radiograph. (B) Facial view at the approximate occlusal vertical dimension. (C) Occlusal view; maxillary arch. (D) Occlusal view; mandibular arch. (E) Facial view; tongue in resting position. (F) Facial view; tongue elevated. (G) Lateral view of mandible; patient right. (H) Lateral view of mandible; patient left.

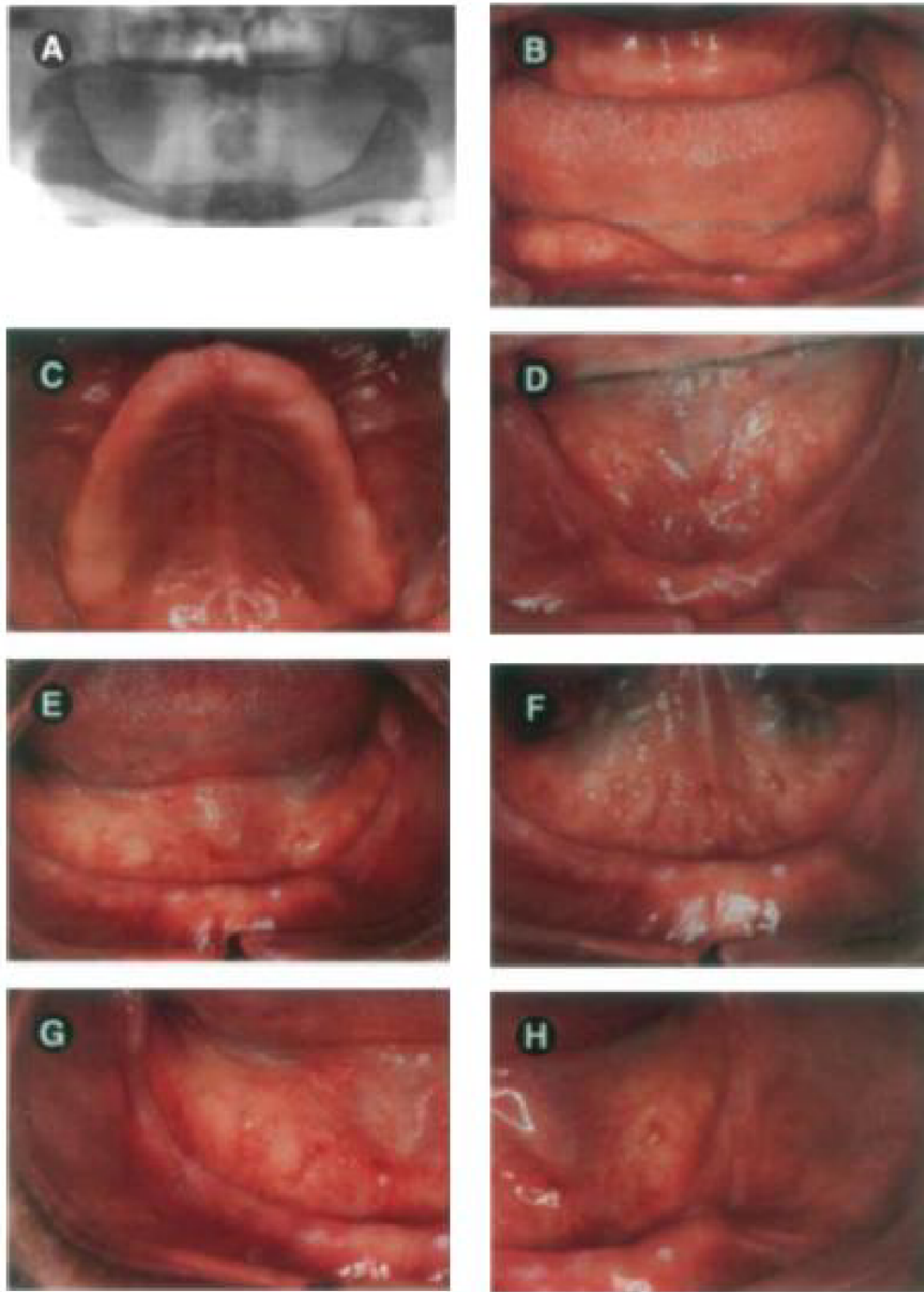


Figure 16. Class III patient. (A) Panoramic radiograph. (B) Facial view at the approximate occlusal vertical dimension. (C) Occlusal view: maxillary arch. (D) Occlusal view: mandibular arch. (E) Facial view: tongue in resting position. (F) Facial view: tongue elevated. (G) Lateral view of mandible: patient right. (H) Lateral view of mandible: patient left.

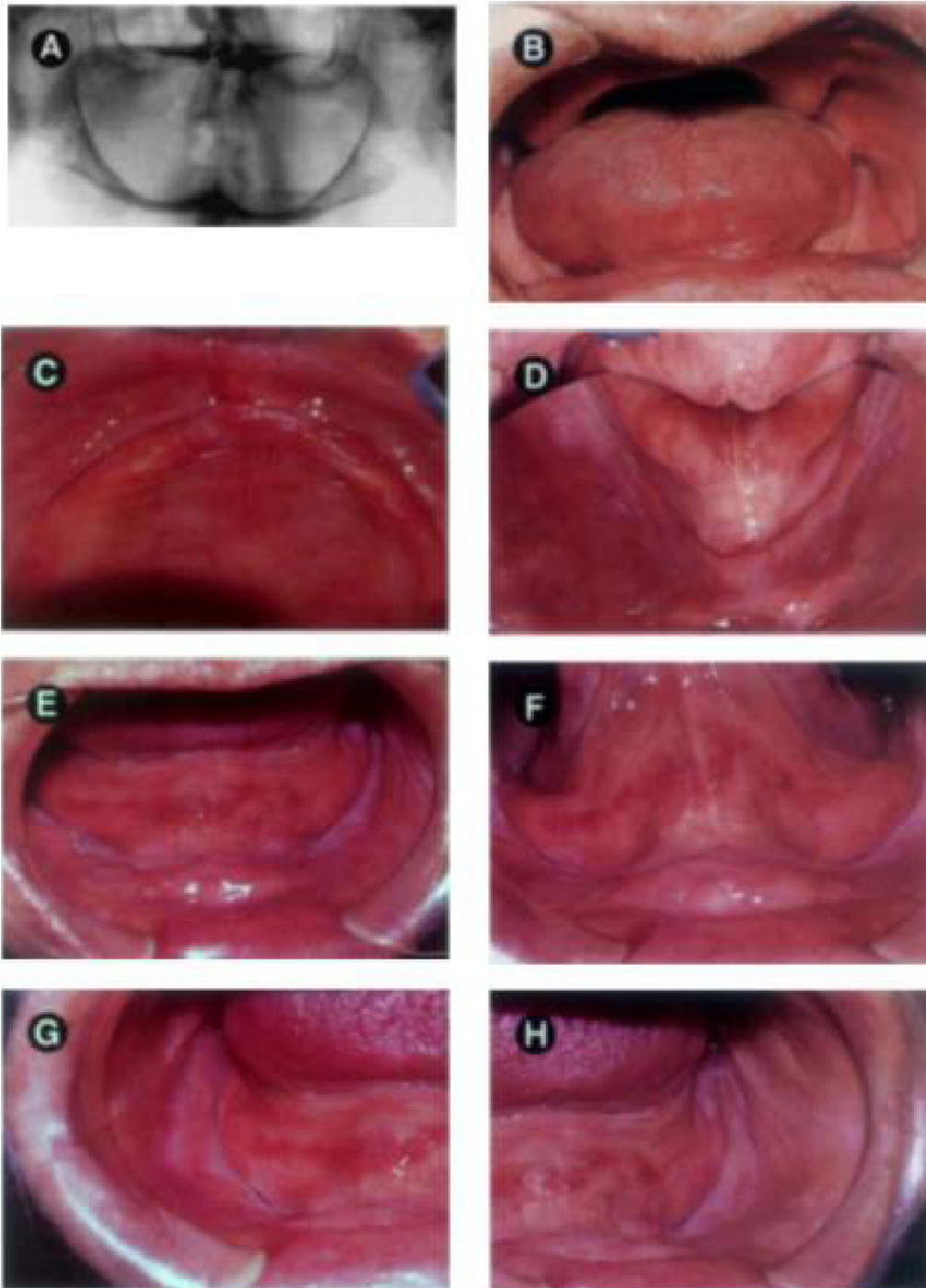


Figure 17. Class IV patient. (A) Panoramic radiograph. (B) Facial view at the approximate occlusal vertical dimension. (C) Occlusal view: maxillary arch. (D) Occlusal view: mandibular arch. (E) Facial view; tongue in resting position. (F) Facial view; tongue elevated. (G) Lateral view of mandible; patient right. (H) Lateral view of mandible; patient left.

Prosthodontic Diagnostic Index(PDI) Classification System						
Prosthodontic Diagnostic Index Complete Edentulism Checklist		Class I	Class II	Class III	Class IV	
Bone Height-Mandibular						
	21 mm or greater					
	16-20 mm					
	11-15 mm					
	10 mm or less					
Ridge Morphology-Maxilla						
	Type A-resists vertical & horizontal, hamular notch, no tori					
	Type B-no buc vest, poor hamular notch no tori					
	Type C-no ant vest, min support, mobile ant ridge					
	Type D-no ant/post vest, tori, redundant tissue					
Muscle Attachments-Mandibular						
	Type A-adequate attached mucosa					
	Type B-no b attach mucosa (22-27), +mentalis m					
	Type C-no ant b&l vest (22-27), +genio & mentalis m					
	Type D-att mucosa in post only					
	Type E-no att mucosa, cheek/lip moves tongue					
Maxillomandibular Relationships						
	Class I					
	Class II					
	Class III					
Conditions Requiring Preprosthetic Surgery						
	Minor soft tissue procedures					
	Minor hard tissue procedures					
	Implants - simple					
	Implants with bone graft - complex					
	Correction of dentofacial deformities					
	Hard tissue augmentation					
	Major soft tissue revisions					
Limited Interarch Space						
	18-20 mm					
	Surgical correction needed					
Tongue Anatomy						
	Large (occludes interdental space)					
	Hyperactive- with retracted position					
Modifiers						
	Oral manifestation of systemic disease					
	Mild					
	Moderate					
	Severe					
	Psychosocial					
	Moderate					
	Severe					
	TMD Symptoms					
	Hx of paresthesia or dysesthesia					
	Maxillofacial defects					
	Ataxia					
	Refractory Patient					
ICD-9-CM Diagnostic Codes		525.41	525.42	525.43	525.44	
Guidelines for use of the worksheet						
	1. Any single criterion of a more complex class places the patient into the more complex class.					
	2. Initial preprosthetic treatment and/or adjunctive therapy can change the initial classification level.					
	3. In the situation where the patient presents with an edentulous maxilla opposing a partially edentulous mandible, each arch is diagnosed with the appropriate classification system.					