

Posterior Palatal Seal

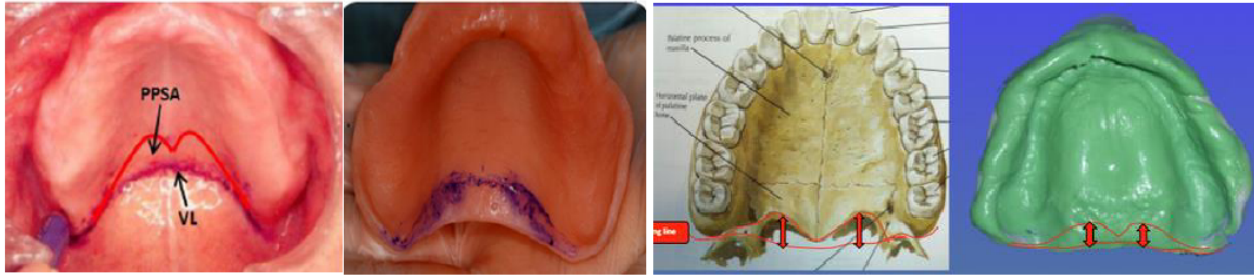
Complete dentures may suffer from a lack of proper border extension, but most important of all is the posterior palatal extension on maxillary complete dentures. The posterior border terminates on a surface that is movable in varying degrees and not at a turn of tissue as are the other denture borders. Locating and designing of posterior palatal seal after thorough understanding of the anatomic and physiological boundaries of this dynamic region greatly enhances border seal and increases maxillary complete denture retention. Hundreds of dentures have failed due to the improper establishment of the distal limit and to an improper posterior palatal seal. Its location and preparation on the master cast are often done by the dentist or dental technician without reference to anatomical landmarks of the mouth. Various methods of achieving posterior palatal seal and reproducing it in the maxillary denture have been described in the literature.

Posterior palatal seal area: The soft tissue area limited posteriorly by the distal demarcation of the movable and no movable tissues of the soft palate and anteriorly by the junction of the hard and soft palates on which pressure, within physiologic limits, can be placed; this seal can be applied by a removable complete denture to aid in its retention.

Functions of the Posterior Palatal Seal

The primary function is that of completing the peripheral seal and enhancing the retention of complete denture. The other purposes served by the PPS are as follows:

1. Maintains contact of denture with soft tissue during functional movements of stomatognathic system, by which decreases gag reflex.
2. Decreases food accumulation with adequate tissue compressibility.
3. Decrease patient discomfort of tongue with posterior part of denture.
4. Compensation of volumetric shrinkage that occurs during the polymerization of PMMA
5. Increases retention and stability by creating partial vacuum.
6. Increased strength of maxillary denture base.
7. Adds confidence and comfort to the patient by enhancing retention.



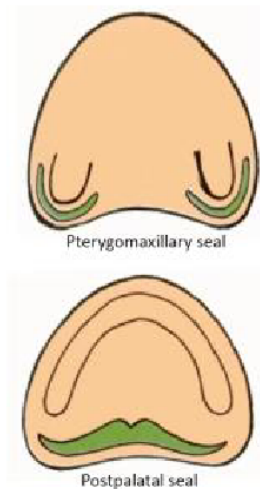
The peripheral seal of maxillary denture is an area of contact between the mucosa and peripheral polished surface of the denture base; the seal prevent passage of air between denture and tissue. Retention of a denture is achieved from adhesion, cohesion & interfacial surface tension that resist the dislodging forces that act perpendicular to the denture base. The posterior palatal seal is placed in the maxillary complete denture because the acrylic will distort slightly and pull away from the posterior palatal area of the maxillary cast. The acrylic will shrink toward the areas of greatest bulk, which are the areas over the ridge where the teeth are placed. The posterior palatal seal provides a vacuum seal between the denture and the soft palate that holds the maxillary complete denture securely in place. The adequate PPS resist the horizontal and lateral forces acting on maxillary denture base as the denture border terminate on soft resilient tissue and there by maintain a proper denture seal. A well-fitting and retentive complete denture requires a well-fitting tissue surface, a peripheral border compatible with the muscles and tissues which make up the mucobuccal and mucolabial spaces so that a peripheral seal is created by the soft tissue draping over them. It is usually obtained by labial and buccal seal. In the posterior region, it is mainly by the posterior palatal seal. At the posterior extension of the maxillary denture, where the tissues are less compliant, special attention is required to make the seal effective.

Anatomical Considerations for Posterior Palatal Seal

The PPS is divided in two anatomic separate boundaries

1. Post palatal seal: is extend from one tuberosity to the other.
2. Pterygomaxillary seal: extend through pterygo maxillary notch continuing for 3-4 mm anterolaterally approximation the mucogingival junction.

It also occupies the entire width of pterygomaxillary notch.



The notch is covered by pterygomaxillary fold (extend from of tuberosity to retromolar pad). This fold influences posterior border seal if mouth is wide open during final impression.

Fovea palatina are two glandular opening within the tissue posterior of hard palate lying on the either side of midline.

- Fovea palatina should be used only as a guideline for the placement of posterior palatal seal. **Medial palatal raphe** which overlies medial palatal suture contain little or no submucosa and will tolerate little or no compression. The seal area narrows down in the midpalatine area due to the scarcity of connective tissue and the prominence of posterior nasal spine. Frequently formed at the junction of the aponeurosis and the posterior nasal spine is a narrow bundle similar to a ligament. The posterior palatal seal is not placed over this narrow area. If the *tours palatine* extend to the bony limit of the palate leaving little or no room to place the PPS then its removable is indicated.

Physiological consideration:

Saliva: Presence of thick ropy saliva can create hydrostatic pressure in the area anterior to the posterior palatal seal, resulting in a downward dislodging force.

Vibrating line: An imaginary line across the posterior part of the soft palate marking the division between the movable and immovable tissues; this line can be identified when the movable tissues are functioning. 1. Anterior vibrating line. 2. Posterior vibrating line.

Anterior vibrating line:

It is an imaginary line lying at the junction between the immovable tissues over the hard palate and the slightly movable tissue of the soft palate.

Methods of location of anterior vibrating line (AVL): Instructing the patient to say “AH” with short vigorous bursts due to projection of the posterior nasal spine. The anterior vibrating line is not a straight line between both hamular processes. The AVL is cupid's bow shaped. Record by ask patient to blow air gently through nose with nostrils closed with fingers.

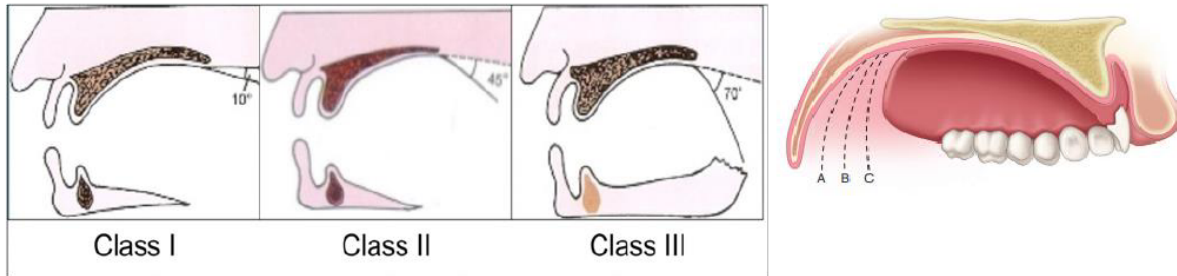
Posterior vibrating line (PVL): It is an imaginary line at the junction of the aponeurosis of the tensor veli palatine muscle and the muscular portion of the soft palate visualized, while the patient is instructed to say ‘ah’ in short bursts in a normal unexaggerated fashion. It represent demarcation between the part of soft palate that has limited or shallow movement during function and the remainder of the soft palate that is markedly displaced during functional movement. The posterior vibrating line marks the most distal extension of the denture base.

Classification of soft palate: According to House classification:

Class I: It indicates soft palate that is rather horizontal as it extends posteriorly with minimum muscular activity. There is considerable separation between anterior and posterior vibrating line, does having wide PPS area yielding more retentive denture base.

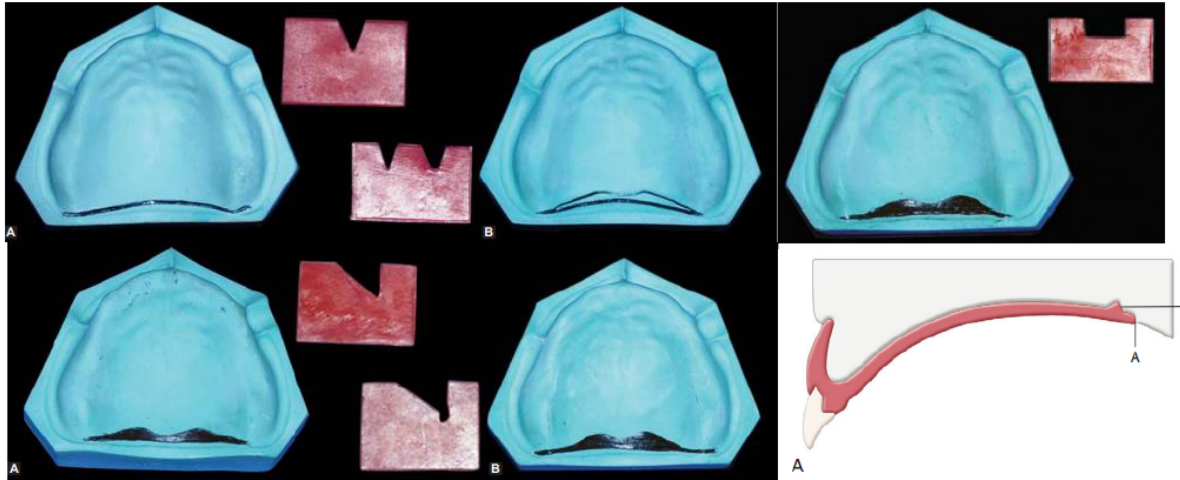
Class II: The soft palate gradually slopes from the hard palate. Overextension of the posterior limit of denture can be tolerated to some extent. Palatal contour lies between class I and III.

Class III: It is seen in conjunction with high V shape palatal vault. There is few mm separation of anterior and posterior vibrating line thus there is small PPS area and less retention. The soft palate abruptly slopes from the hard palate. Hence, the posterior limit of maxillary denture remains very critical.



Designs of the posterior palatal seal: Winland and Young surveyed the commonly employed posterior palatal seal designs and summarized them as follows:

1. A bead posterior palatal seal
2. A double bead posterior palatal seal
3. A butterfly posterior palatal seal
4. A butterfly posterior palatal seal with a bead on the posterior limit
5. A butterfly posterior palatal seal with the hamular notch area cut to half the depth of a no. 9 bur.
6. A posterior palatal seal constructed in reference to House's classification of palatal forms:
 - Class I: A butterfly shaped posterior palatal seal with 3-4 mm wide.
 - Class II: Posterior palatal seal is narrow with 2-3 mm of width.
 - Class III: A single beading made on the posterior vibrating line.



Methods or techniques of recording posterior palatal Seal area:

1. Conventional approach. 2. Fluid wax technique. 3. Arbitrary scraping of master cast.

1. Conventional approach: After the record base is fabricated there are certain instructions given to the patients:-

1. To rinse with astringent mouth wash that is to remove the stringy saliva that might prevent clear transfer marking.

2. Location of pterygo-maxillary notch is done by moving the T burnisher along the posterior angle of the maxillary tuberosity until it drops into the pterygo- maxillary notch. This is necessary as there are times when small depression in the residual ridge may resemble pterygo- maxillary notch.

3. Identification of posterior vibrating line, the patient asked to say “AH” in a normal unexaggerated fashion.

4. Identification of the anterior vibration line. This is done by asking the patient to say “AH” with short vigorous bursts. Procedure:

- A line is placed with an indelible pencil through the pterygo maxillary notch and extended 3-4 mm antero-laterally to the tuberosity area approximating the mucogingival junction, the same is done on the opposite side. This complete the out lining of pterygo maxillary seal.
- The posterior vibrating line is marked with an indelible pencil by connection the line through the pterygomaxillary seal with line just drawn demarcation the post palatal seal.

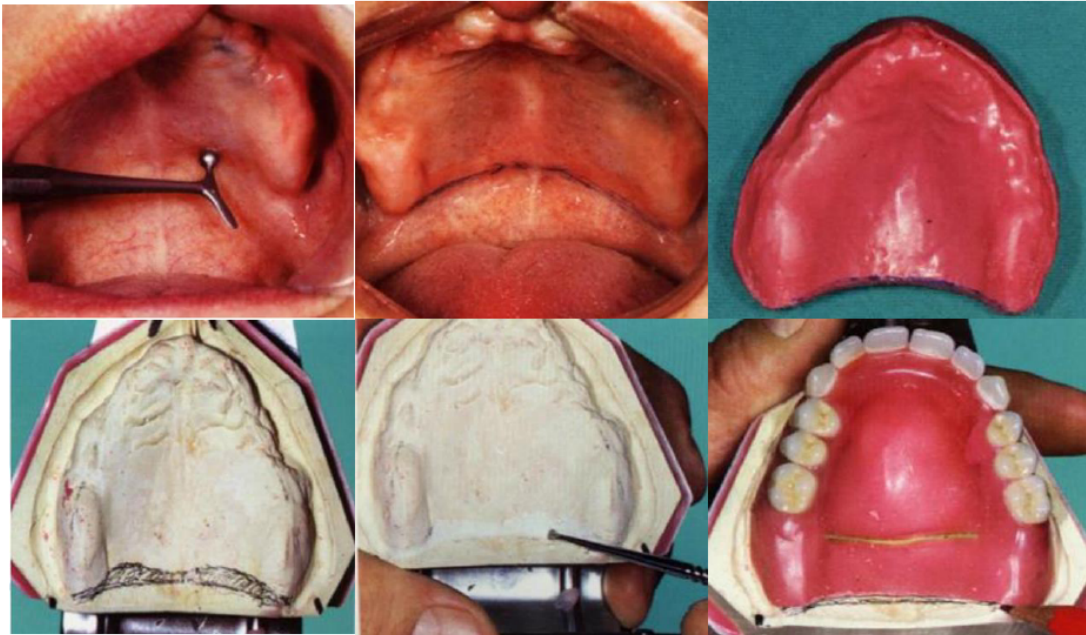
- The resin or shellac record base inserted into the mouth and seated firmly to place, so that upon removal from the mouth the indelible lines will be transferred to the record base.
- Sometimes it is necessary to redefine transfer marking. The record base is return to master cast to complete the transfer of the complete posterior border. The tray is trimmed until the posterior vibration line so that it decides the posterior extent of denture border.
- Returning to the mouth the palatal fissure are palpated with the 'T' burnisher or mouth mirror to determine their compressibility in width and depth.
- The termination of glandular tissue usually coincides with the anterior vibrating line.
- The anterior vibrating line now marked and transferred to master cast. This will complete the transferring of the outline of posterior palatal seal area.
- The visual outline is in the shape of cupid bow, the area between the anterior-posterior vibrating lines is usually narrowest in the mid palatal region because of the projection of the posterior nasal spine.
- Carving of the master cast is done using a Kingsley scraper. Deepest areas are located on either sides of the midline, one-third the distance anteriorly from the PVL, depth of 1-1.5 mm is carved. The tissues covering the Mid-palatal raphe are scored to a depth of 0.5-1 mm because it contain little sub mucosa and cannot withstand same compressive force as the tissue lateral to it. As the seal approaches the anterior vibrating line there is just a slight scraping of the cast. Just posterior to the deepest portion of the seal, it is tapered again towards the PVL. Failure to taper the seal posteriorly led to tissue irritation.

Advantages of this technique:

1. The trail base will be more retentive.
2. This can produce more accurate maxilla-mandibular records.
3. Patient will be able to experience the retentive qualities of the trail base, giving them the psychologic security of knowing that retention will not be a problem in completed prosthesis.
4. The practioner will be able to determine the retentive qualities of the finished denture.
5. The new denture wearer will be able to realize the posterior extent of the denture which may ease the adjustment periods.

Disadvantages:

1. It is not a physiologic technique and therefore depends upon accurate transfer of the vibrating lines and careful scraping of the cast.
2. The potential for over compression of the tissue is great.



2. Fluid wax technique (functional technique or physiological technique): All of the procedure remain the same as conventional technique that is transfer location and transfer marking of the anterior and posterior vibrating line. The marking are recorded in final impression. ZOE/impression plaster (not with elastomeric impression material as they are resilient, non-adherent to wax, and distort wax when reseated into oral cavity).

One of the four types of wax can be used for this technique:-

1. Iowa wax white
- 2- Adaptol green wax.
3. Korecta wax no. 4 (orange).
4. K.L physiologic paste (yellow-white).

These waxes are designed to flow at mouth temperature. The melted wax is painted into the impression surface and in the outline at seal area, usually the wax is applied in slightly excess of the estimated depth and allowed to cool to below mouth temperature to increase its consistency and make it more resistant to flow. The impression is carried to the mouth and held in place under gentle pressure for 4-6 min and allow time for the material to flow.

Patient position during impression making of palatal seal area:

An impression should be made when the patient is seated in upright position with head flexed 30 degree forward, below *FH* (*Frankfort*) plane to allow the soft palate to reach its functionally depressed position.

The patients tongue should be placed under tension against either the handle of the impression tray or the dentist's finger which is held in the region of upper maxillary incisors.

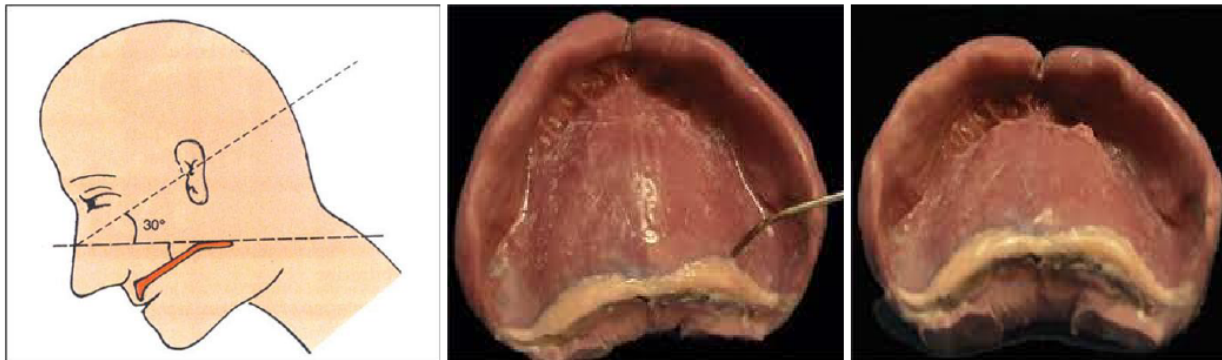
After 4 min remove impression tray, if the tissue contact has been established it will appear glossy. Trim excess (or) if no tissue contact is established then add and redo the procedure. A Secondary impression is reinserted and held for 3-5 minutes under gentle pressure followed by 2-3 minutes of firm pressure applied to mid palatal area of the impression tray, upon removal of tray from the mouth it is carefully examined to see wax terminate in feathered edge near the anterior vibrating line.

Advantages:

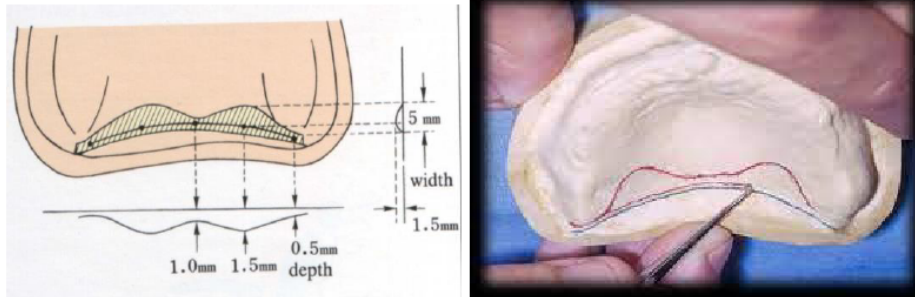
- It is physiologic technique displacing tissues within their physiologically acceptable limits.
- Over compression of tissue is avoided.
- Posterior palatal seal is incorporated into the trail denture base for added retention.
- Mechanical scrapping of the cast is avoided.

Disadvantages:

- More time is necessary during the impression appointment.
- Difficulty in handling the materials and added care during the boxing procedure.



3. Arbitrary scraping of master cast: According to Winkler, arbitrarily mark the anterior and posterior vibrating line and scrape about 1-1.5 mm. It is the least accurate methods used to mark the posterior palatal seal. Its high potential for over post damming is due to its nature of not physiologic technique of recording.



Error in recording of PPS:

1. Under extension: This is the most common cause for poor posterior palatal seal. It may be produced due to one of the following reason:-

1. The denture does not cover the fovea palatina, the tissue coverage is reduced and the posterior border of the denture is not in contact with the soft resilient tissue which will move along with the denture border during functional movements.
2. The dentist leaves the posterior border under extended to reduce the patient anxiety to gagging.
3. Improper delineation of the anterior and posterior vibrating line.
4. Excessive trimming of the posterior border of the cast by the technician.

2. Over extension: Over extension of the denture can lead to:

1. Ulceration of the soft palate and painful deglutition.
2. The most frequent complaint from the patient will be that swallowing is painful and difficult.
3. The hamuli are covered by the denture base, the patient will experience sharp pain, especially during function.

(Prevention): These region are trimmed with a bur and carefully polished.

3. Under postdamming:

1. This can occur due to improper head positioning and mouth positioning. E.g. the mouth is wide open while recording the posterior palatal seal, the mucosa over the hamular notch becomes stretched. This will produce a space between the denture base and tissue.
2. Inserting a wet denture into a patient's mouth and inspecting the posterior border with the help of mouth mirror. If air bubbles are seen to escape under the posterior border it indicates under damming.
3. *Prevention:* The master cast can be scraped in the posterior palatal area or the fluid wax impression can be repeated with proper patient position.

4. Over postdamming:

1. This commonly occur due to excess scraping of the master cast. It occur more commonly in the hamular notch region.
2. Pterygo maxillary seal area, then upon insertion of the denture the posterior border will be displaced inferiorly.
3. *Prevention:* Reduction of the denture border with a carbide bur, followed by lightly pumicing the area while maintaining its convexity.

Addition of posterior palatal seal to existing denture:-

Existing denture may have poor length and depth of PPS. Properly examine existing dentures. If there are other problems in the dentures (vertical dimension, centric, esthetics etc.) then new dentures are to be made. If only PPS is short then correction should be undertaken. Different authors using different materials have advised various techniques.

Moghadam and Scandrett advised the use of fluid wax technique for recording posterior palatal seal and addition of posterior palatal seal with auto polymerizing acrylic resin.

A similar technique using softened greenstick modeling compound has been suggested by Carrol and Shaffer.

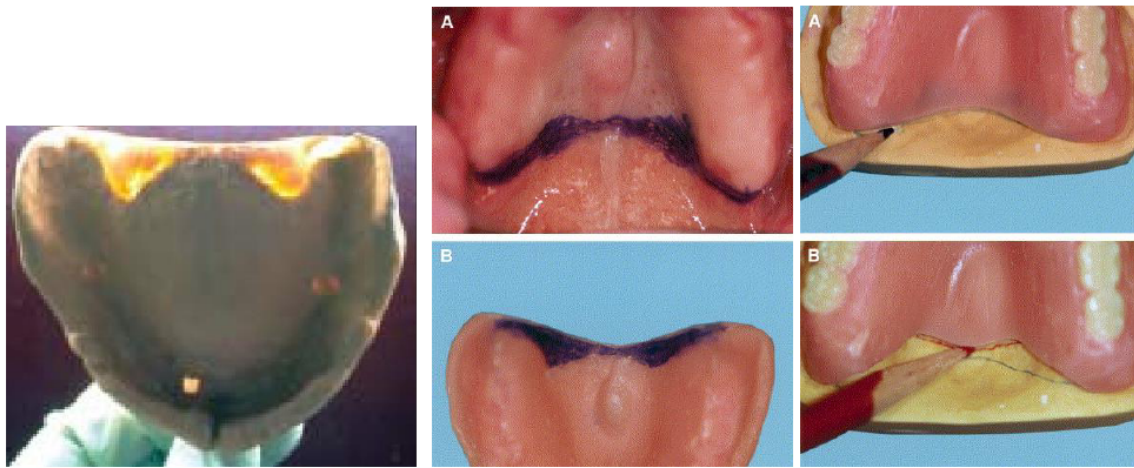
Other suggested materials for correction of PPS include:

1. Heat cured acrylic resin material.
2. Self-cured acrylic resin.
3. Light cured resin.

When to record PPS: There are two schools of thought as to when to record PPS.

- Before try in - provide the patient with psychological confidence.
- After try in to prevent possible mechanical displacement of the trail base by the tissues, which result in an inferior placement of the posterior segment of the denture base leading to occlusal error in 2nd molar region due to improper seating of bases during jaw relation.

Orally, the area of the vibrating line is recorded by making marks with an indelible transfer stick in the fovea palatina area and the hamular notch areas on both sides of the palate and then connecting them with a solid line.



- ✓ It is checked by firmly seating the denture in the mouth and trying to displace it with force at right angle to its occlusal surface, if the denture resist displacement it is said that it has retention.

