

# Space --- maintainers

# PEDIATRIC DENTISTRY

## SPACE MAINTAINER

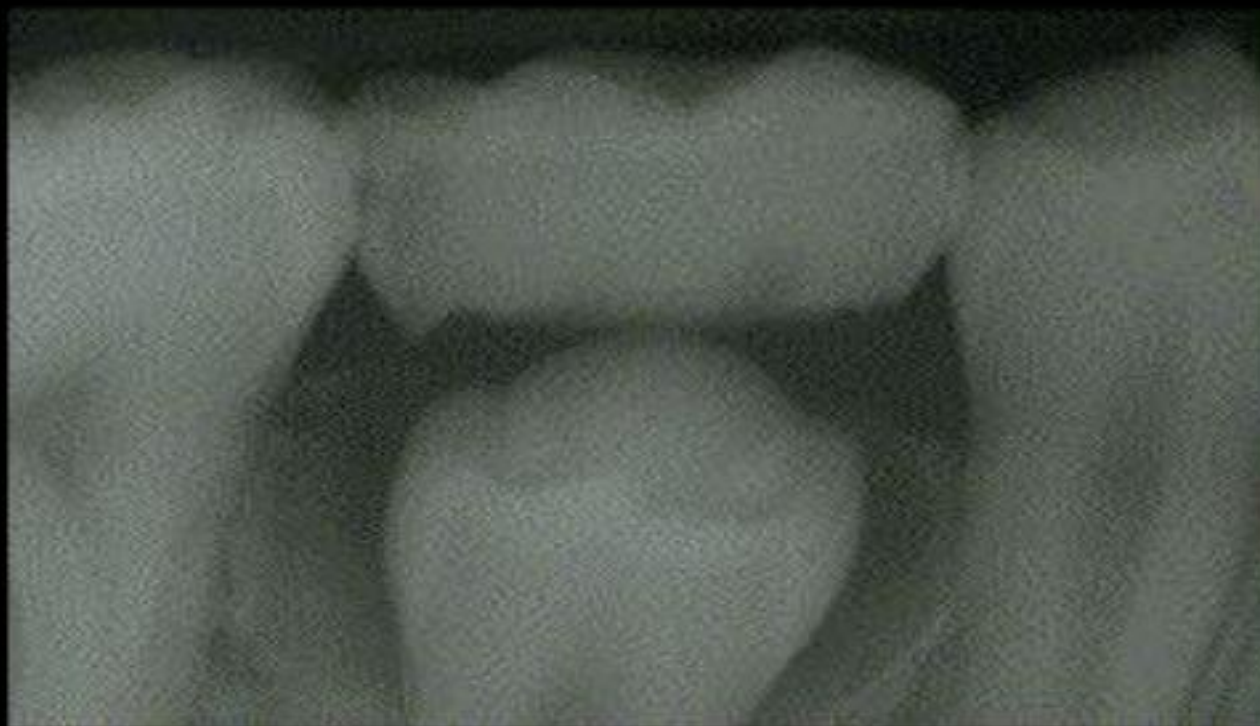---

Lec 11

Dr. Mukhaled Louay Al. Falluji

P.D.S. M.Sc.

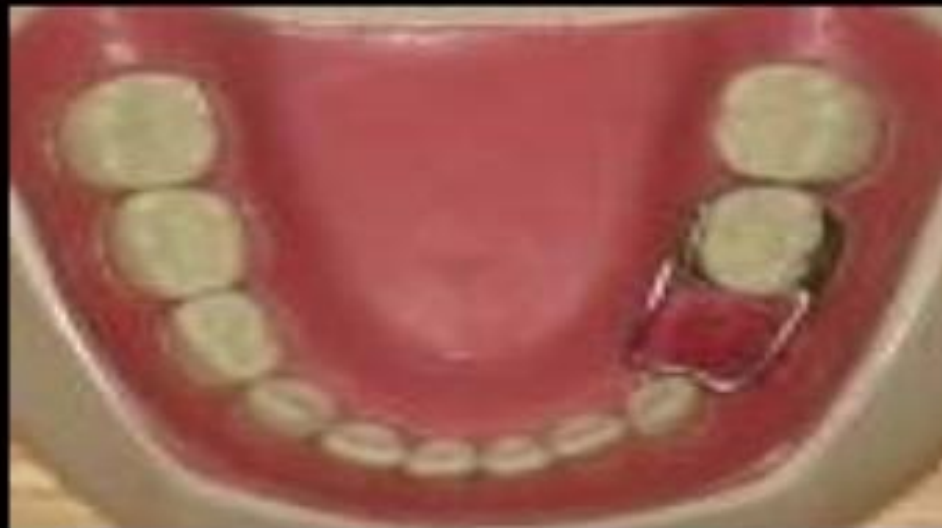- The best space maintainer is a primary tooth
- 



## Definition:

---

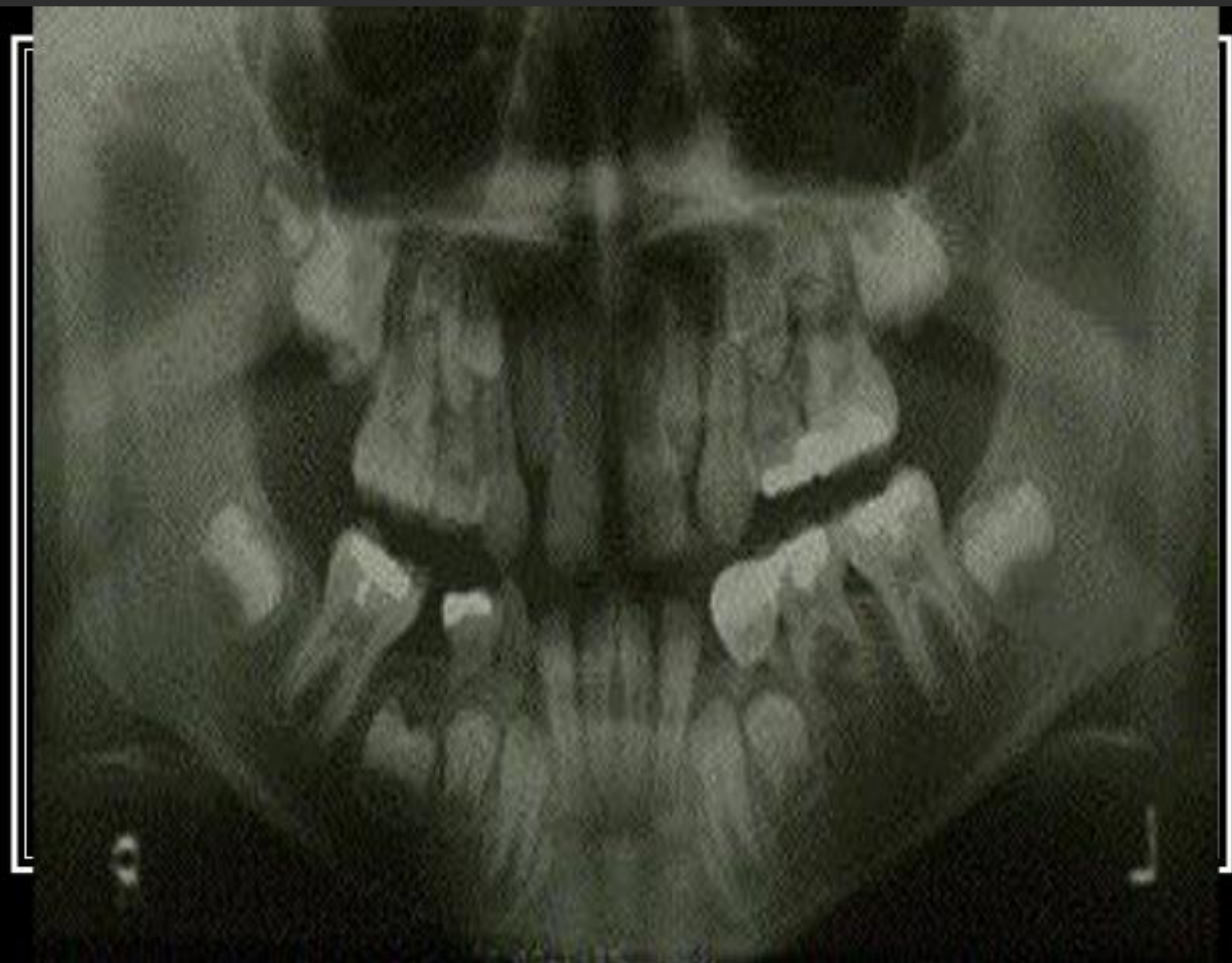A fixed or removable appliance placed to maintain space created by the premature loss of a tooth or teeth.



## why we do space maintainer?

---

- The space of prematurely lost teeth usually change in the following 6 months period, sometimes a decrease in space may occur within days or weeks which may cause loss of arch length, resulting in **crowding** of the permanent dentition, **impaction** of permanent teeth, **esthetic** difficulties, **malocclusion**, and other problems



## Indications of space maintainer:

1. If the space shows signs of closing.
2. If the use of space maintainer will make the future orthodontic less complicated.
3. If the need for treatment of malocclusion at a later date is not indicated.

4. When the space should be maintained for two year or more.
5. To avoid supra eruption of opposing tooth.
6. To improve the masticatory system and restore dental health.



## **contraindications of space maintainer:**

1. if the radiograph shows that the ~~succedaneum~~ tooth will erupt soon.
2. If the radiograph shows one third of the root of is already calcified.
3. When the space left is greater than the needed for the permanent as indicated from radiographically.
4. If the space shows no signs of closing.
5. When the succedaneous tooth is absent.

## FACTORS INFLUENCE PLANNING FOR SPACE MAINTAINER

---

- Time lapse since lost
- Dental age of patient
- Amount of bone covering the unerupted tooth
- Sequence of eruption of teeth
- Delayed eruption of permanent teeth

- Congenital absence of permanent teeth
- Presence of oral habits

# CLASSIFICATION OF SPACE MAINTAINER

---

The classification of the space maintainers can be summarized in the following

According to function:

- Functional
- Non-functional

According to activity:

- Active
  - Passive
- 

According to retention:

- Fixed
- Semi fixed
- Removable

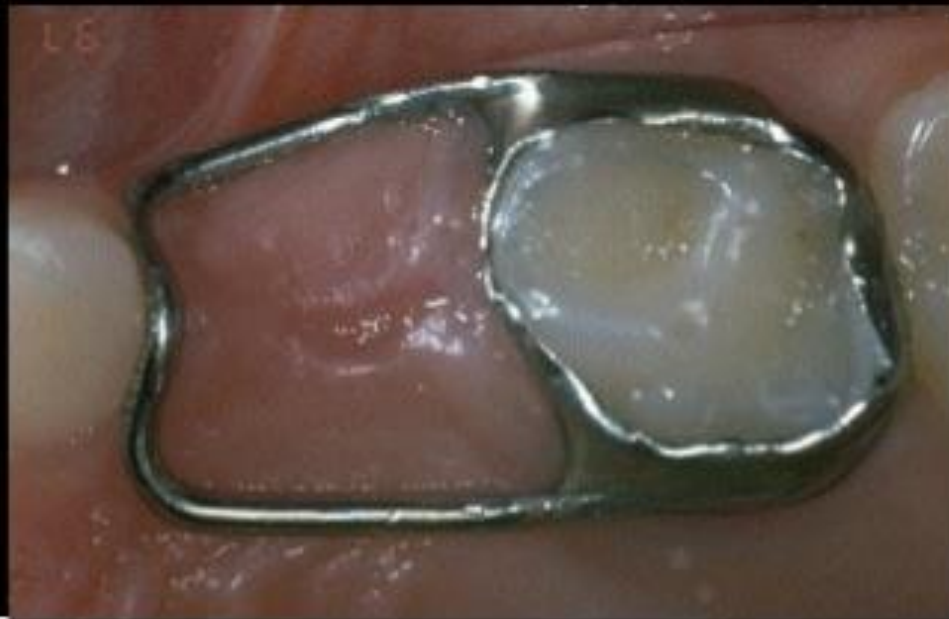## COMMONLY USED SPACE MAINTAINERS

---

- BAND & LOOP
- CROWN & LOOP
- LINGUAL ARCH HOLDING DEVICE
- NANCE'S PALATAL HOLDING DEVICE
- TRANS PALATAL
- DISTAL SHOE
- REMOVABLE SPACE MAINTAINER

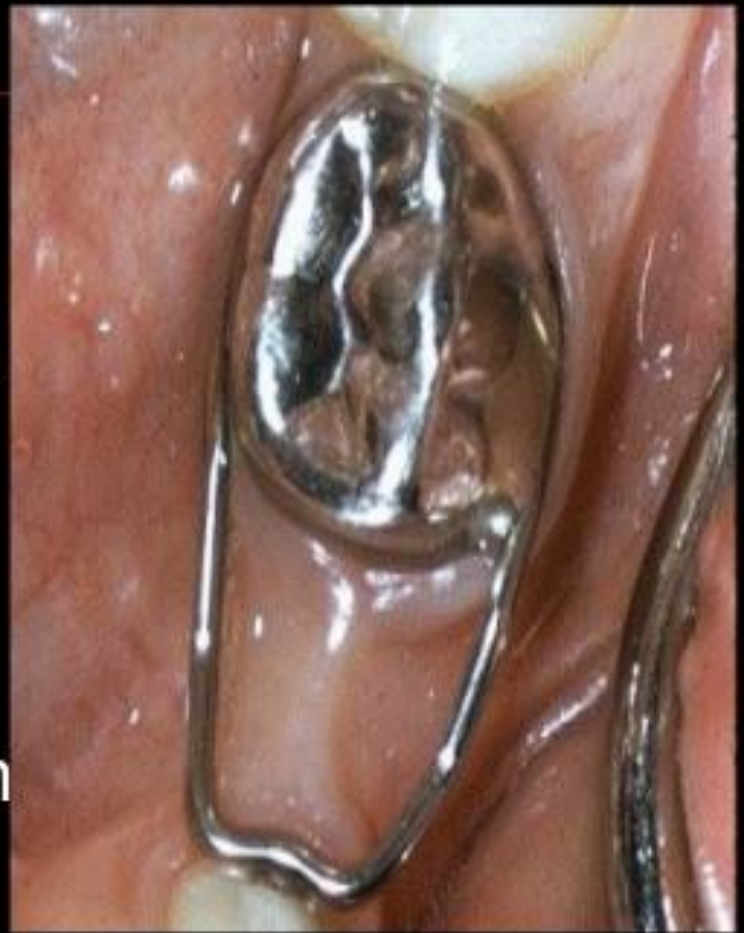## BAND & LOOP SPACE MAINTAINER

- Most commonly used
- Unilateral fixed appliance
- Used in posterior segments



## CROWN & LOOP SPACE MAINTAINER

- Stainless steel crown is used as an abutment
- Stronger than band and loop
- Cementation failure or loss are less likely
- Excellent choice if tooth needs a restoration

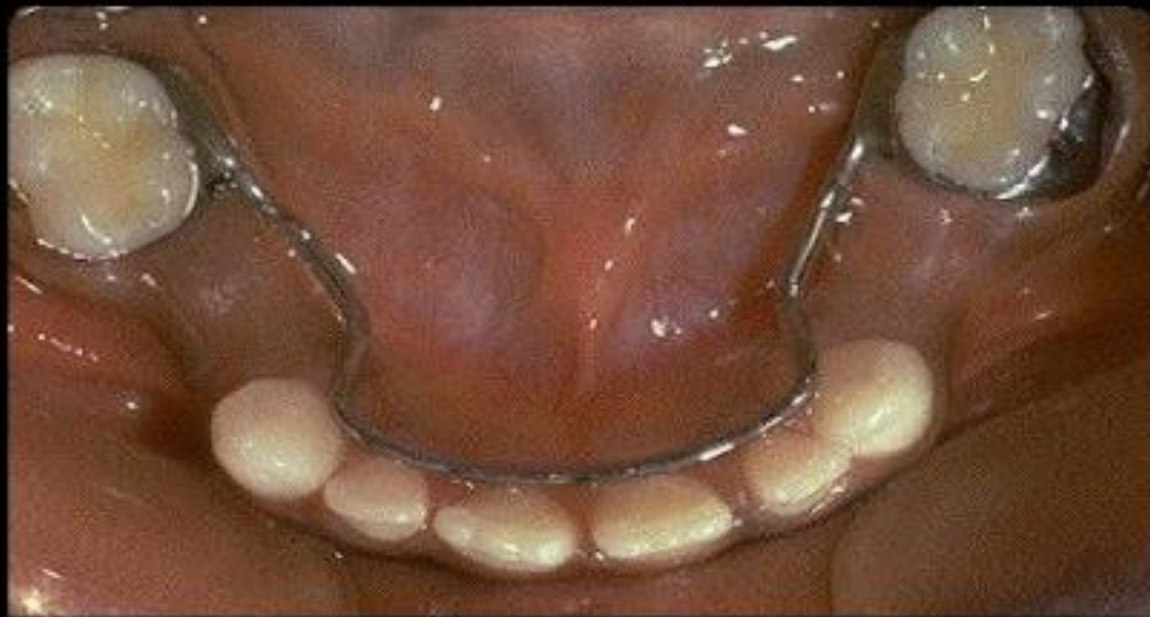



## LINGUAL ARCH SPACE MAINTAINERS

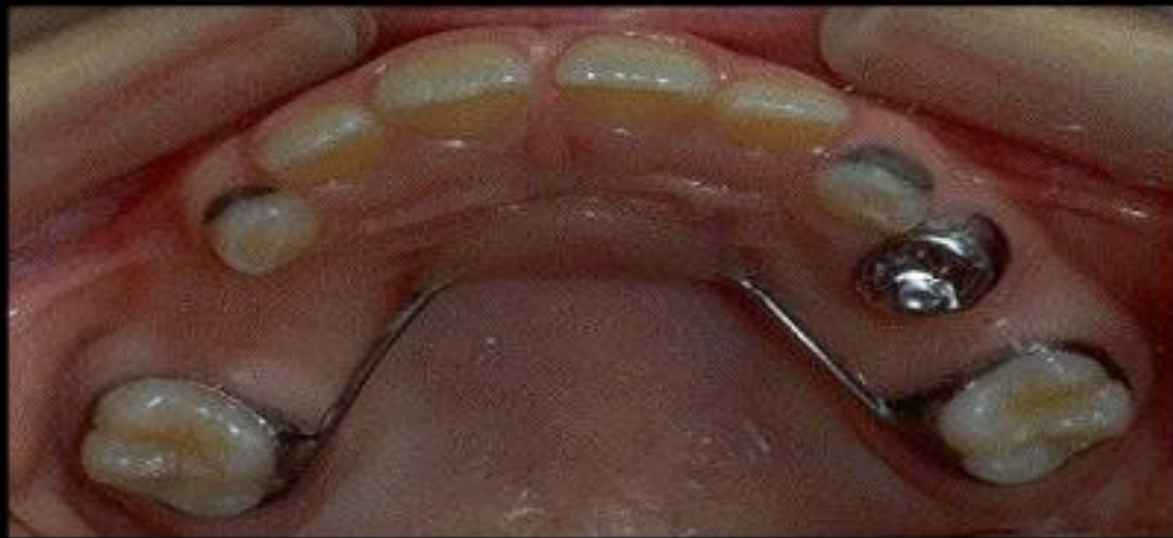---

- Bands on first permanent molars
- should not be placed with primary incisors



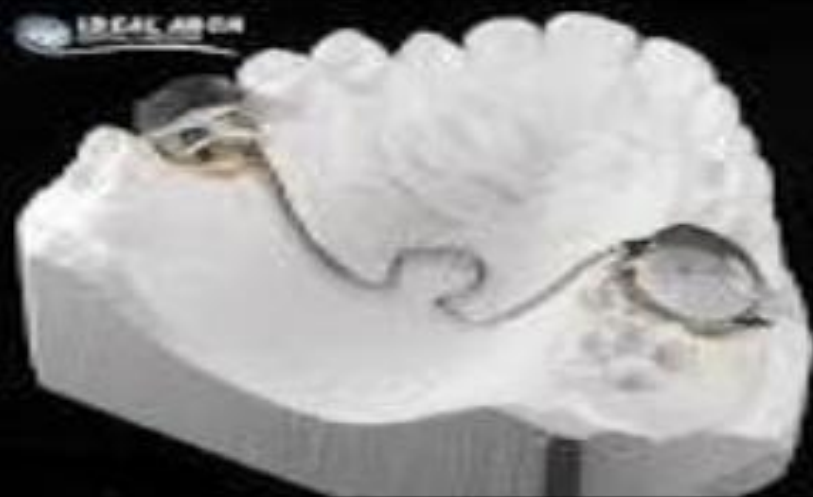
## NANCE PALATAL ARCH

- Bands on first permanent molars
- It's a simple maxillary lingual arch but does not contact anterior teeth
- It has an acrylic button in the mid palate



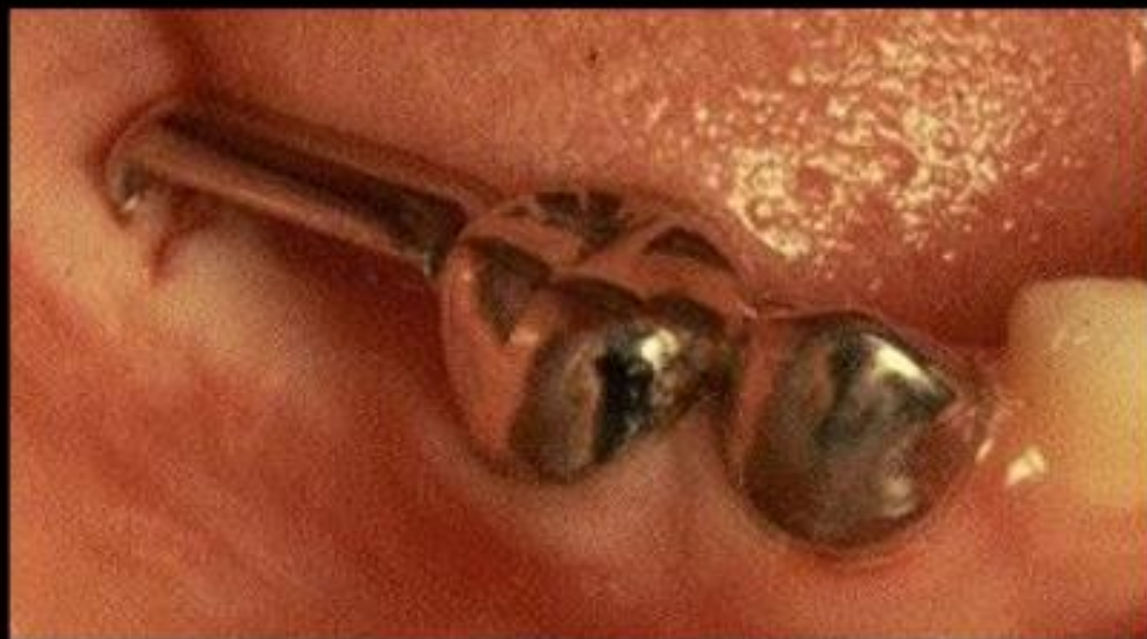## TRANS PALATAL ARCH APPLIANCE

- Can be used like a Nance.
- Advantage Lack of acrylic button so less tissue irritation and more cleansable
- Disadvantage Lack of anterior stop = possible tooth shift



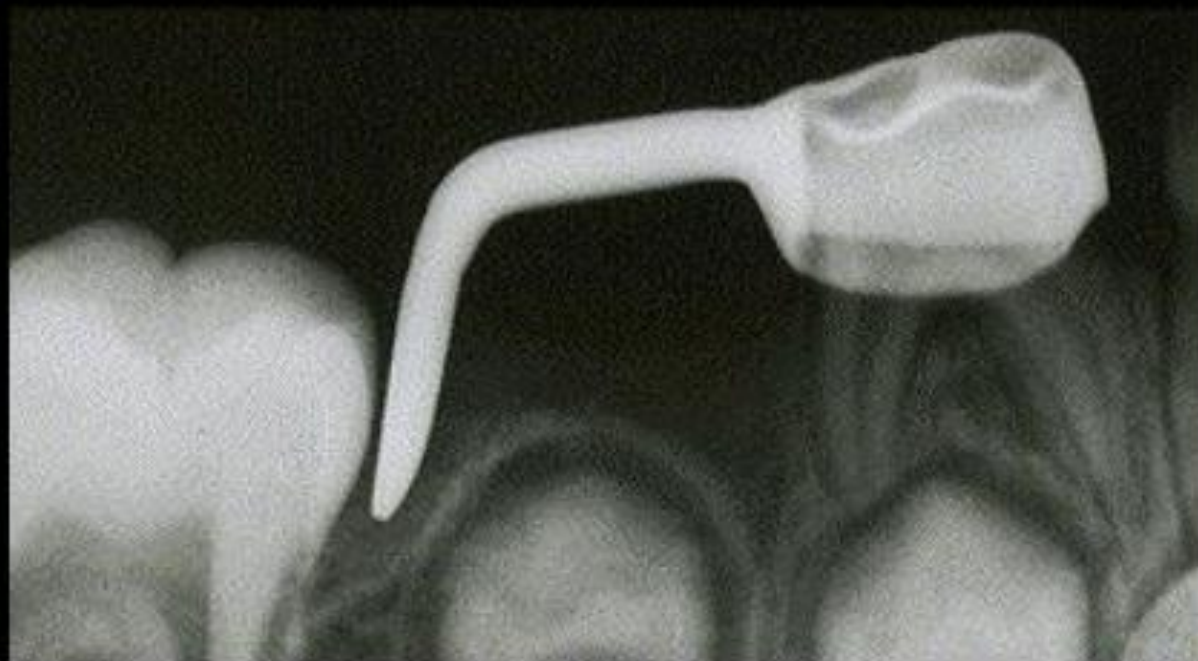## DISTAL SHOE APPLIANCE

Used when second primary molar requires extraction and first permanent molar has not erupted



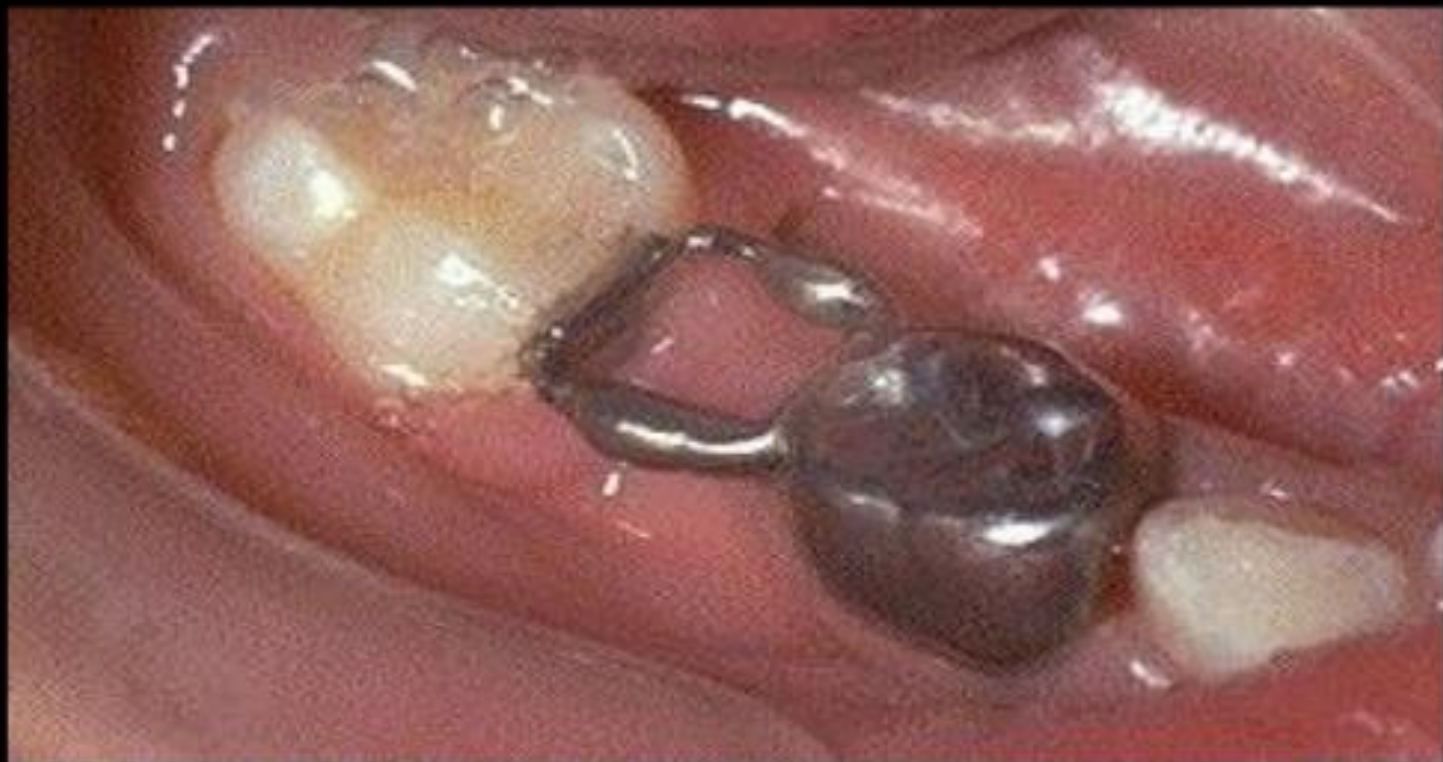Should be evaluated with radiograph prior to cementation

- Length
- Position



Will be replaced with another space maintainer when permanent teeth erupt.

---

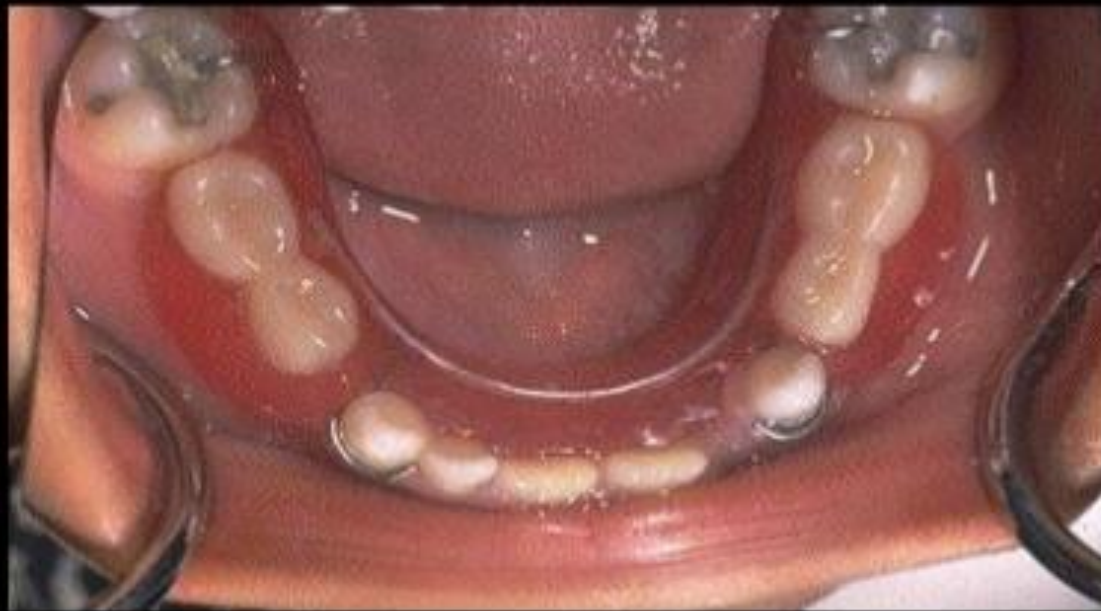

# REMOVABLE SPACE MAINTAINERS

---

a. Non-functional types

b. Functional types

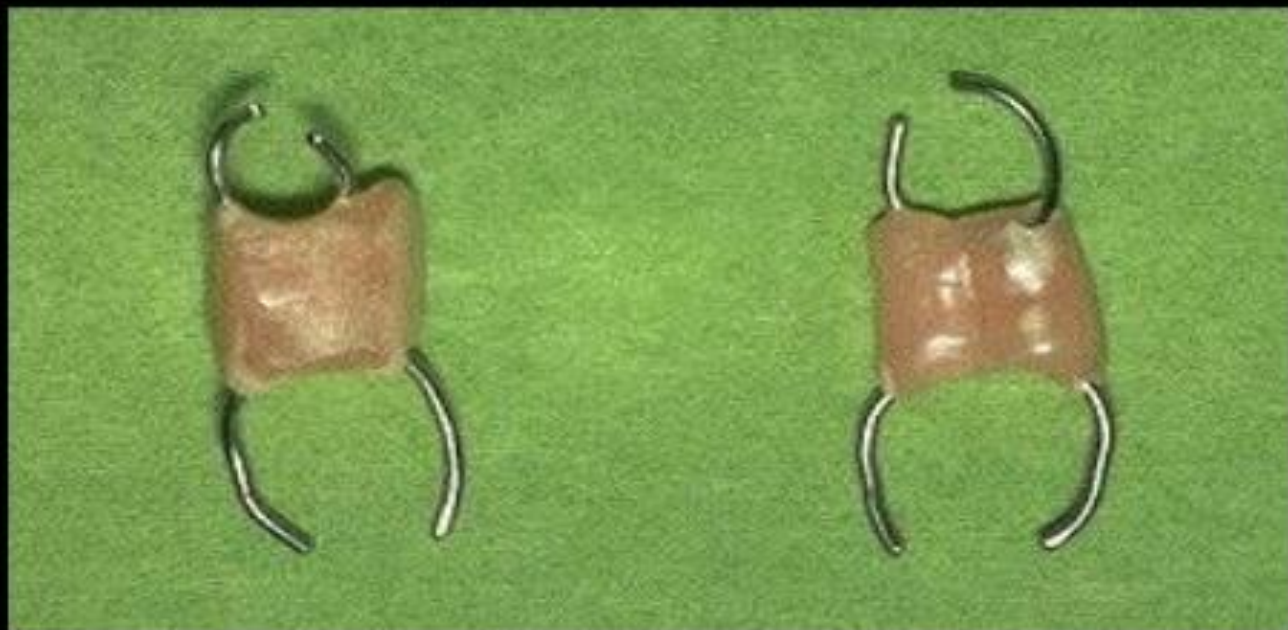

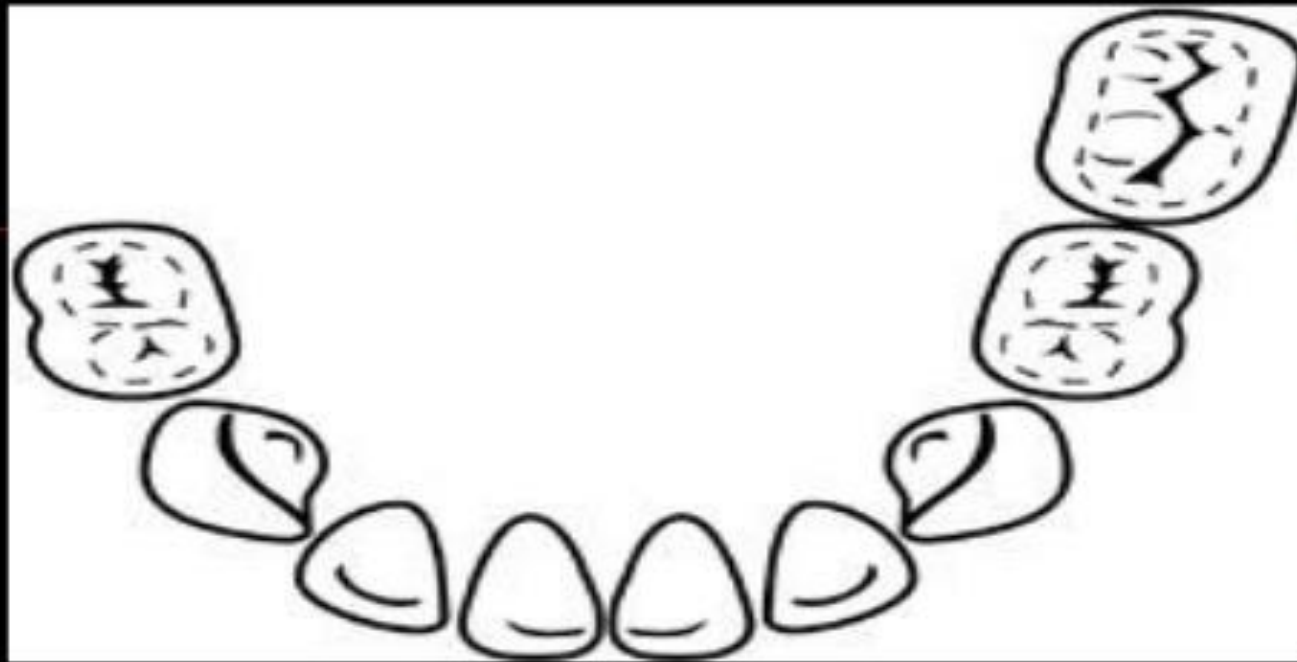


It is like a removable partial denture Not only Mesiodistal space but also the vertical space is maintained. masticatory Function is restored in functional type Esthetics & speech improvement is seen

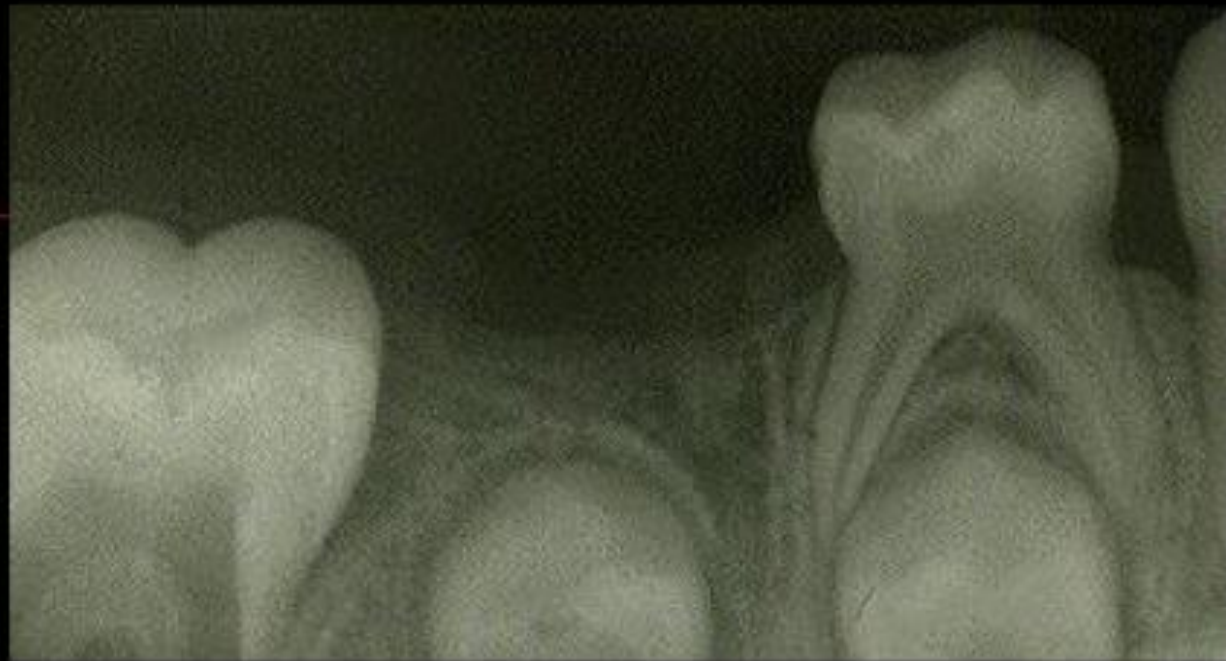

- removable unilateral space maintainers
- They are too small and present swallowing and choking dangers for children.

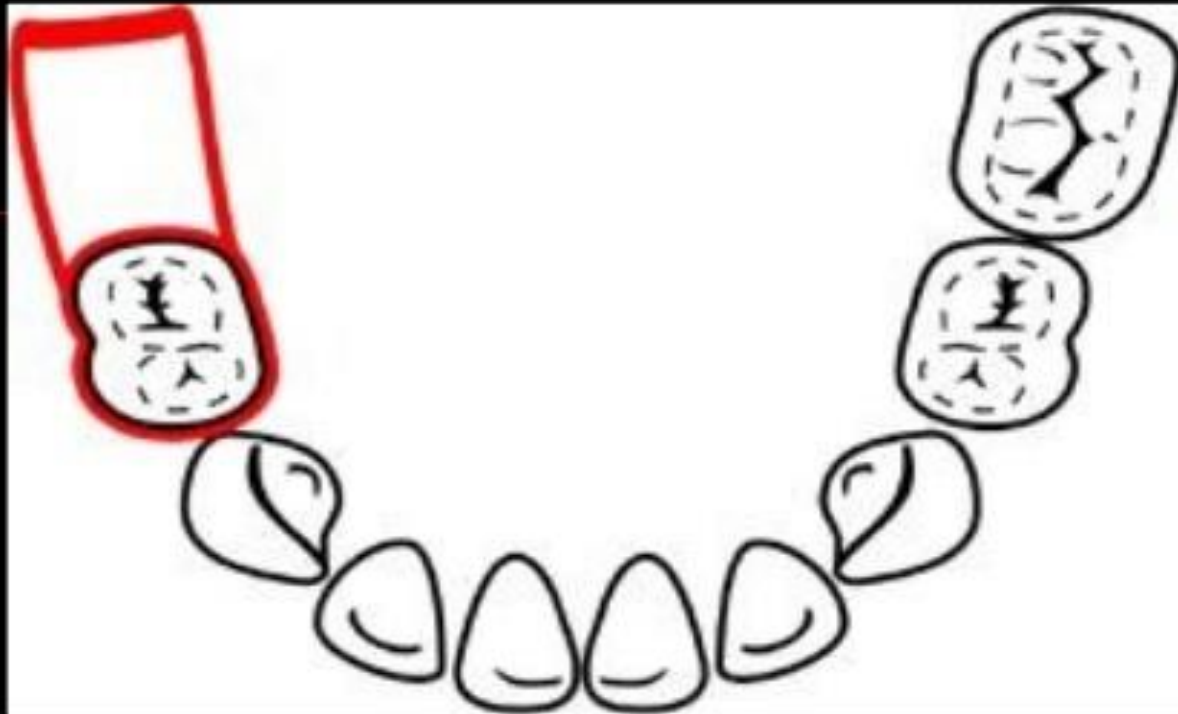




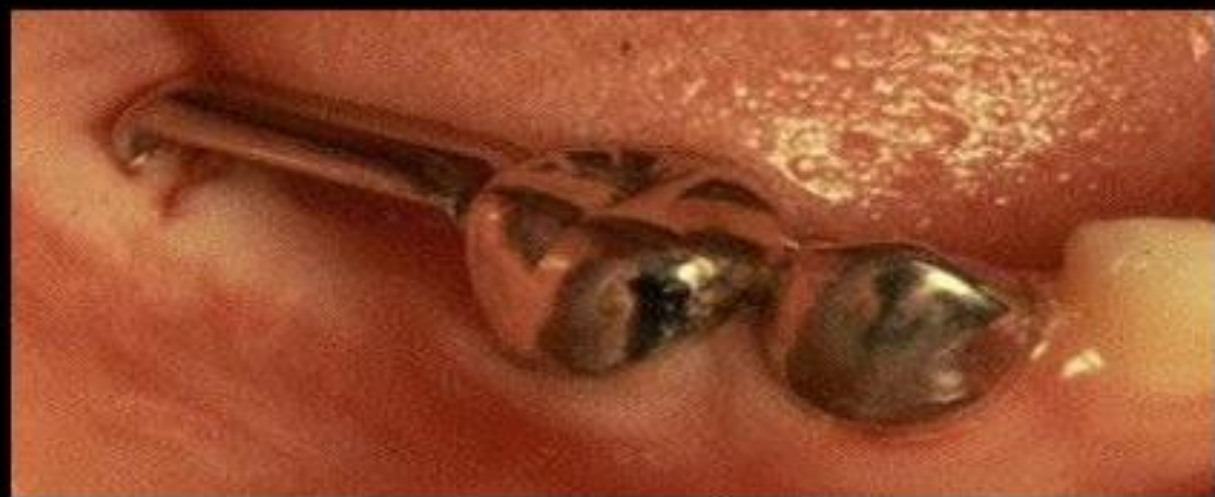
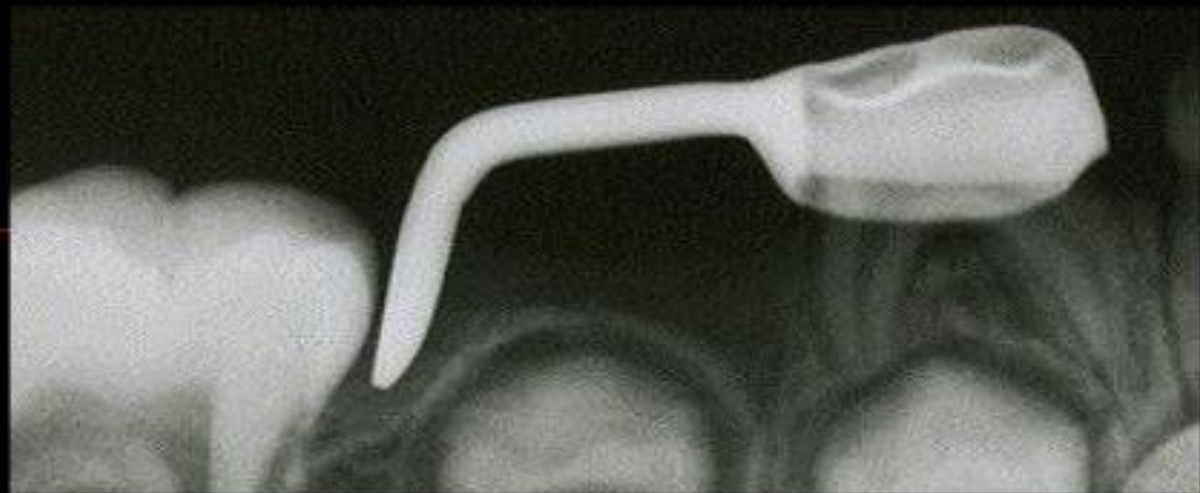
In this drawing, the mandibular right second primary molar is missing on a four year-old child. In your judgment, **is this child in need of a space maintainer?**

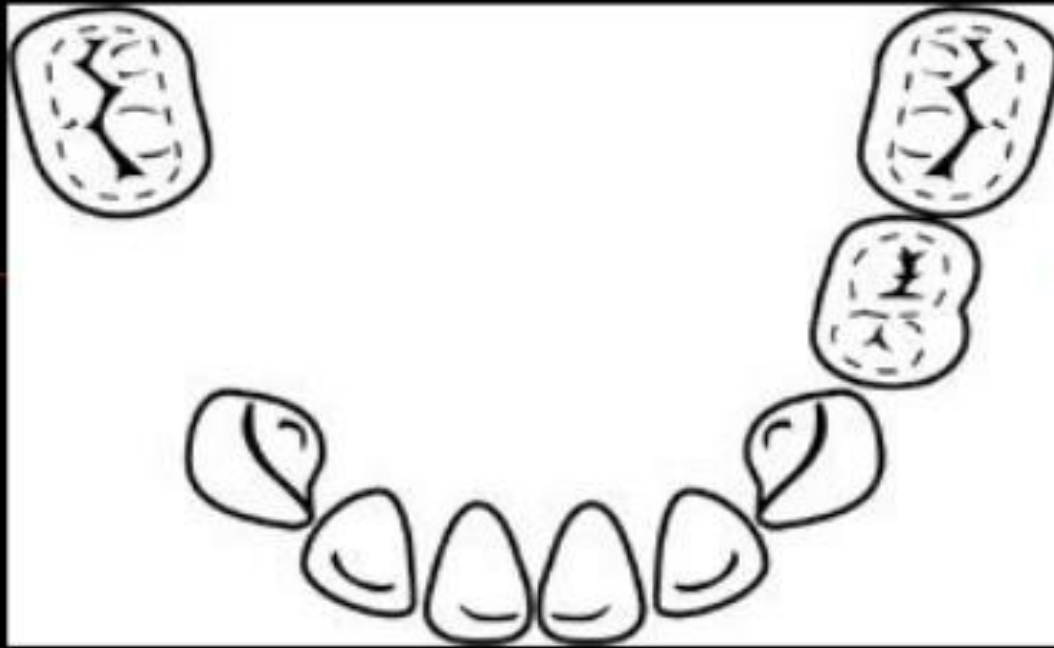


- This is a radiograph of a similar situation showing the missing mandibular right second primary molar

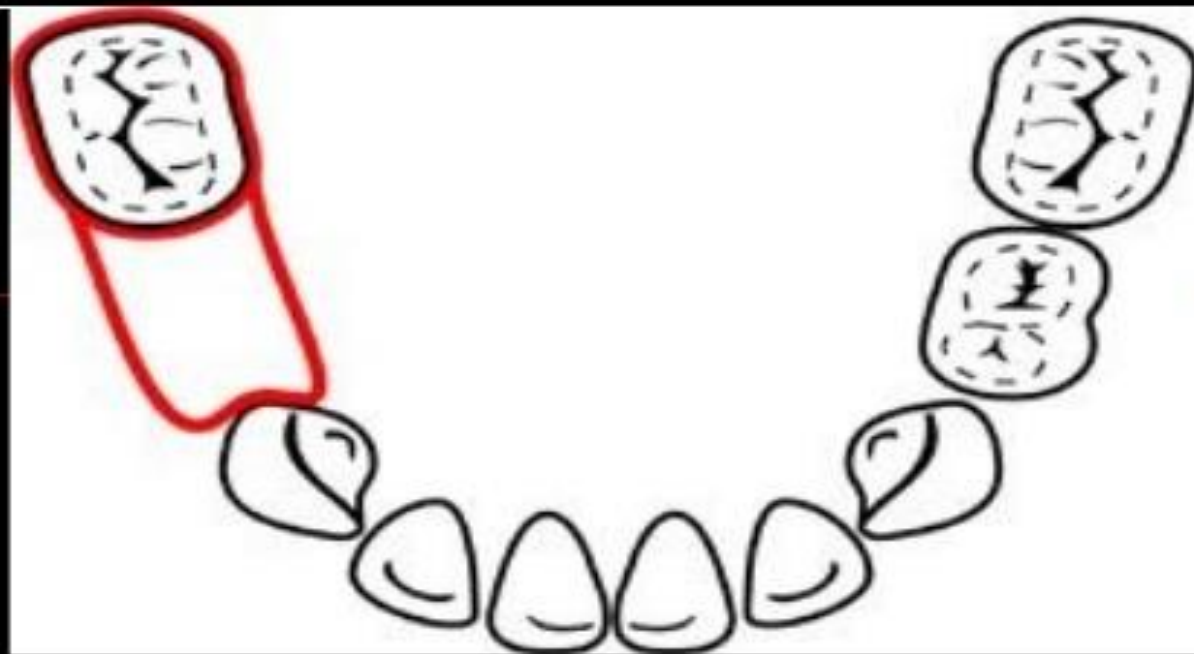


- Yes; a space maintainer is indicated





In this drawing, the mandibular right first primary molar is missing on a six year-old child. In your judgment, is the child in need of a space maintainer? If so, would you use a removable or a fixed space maintainer?



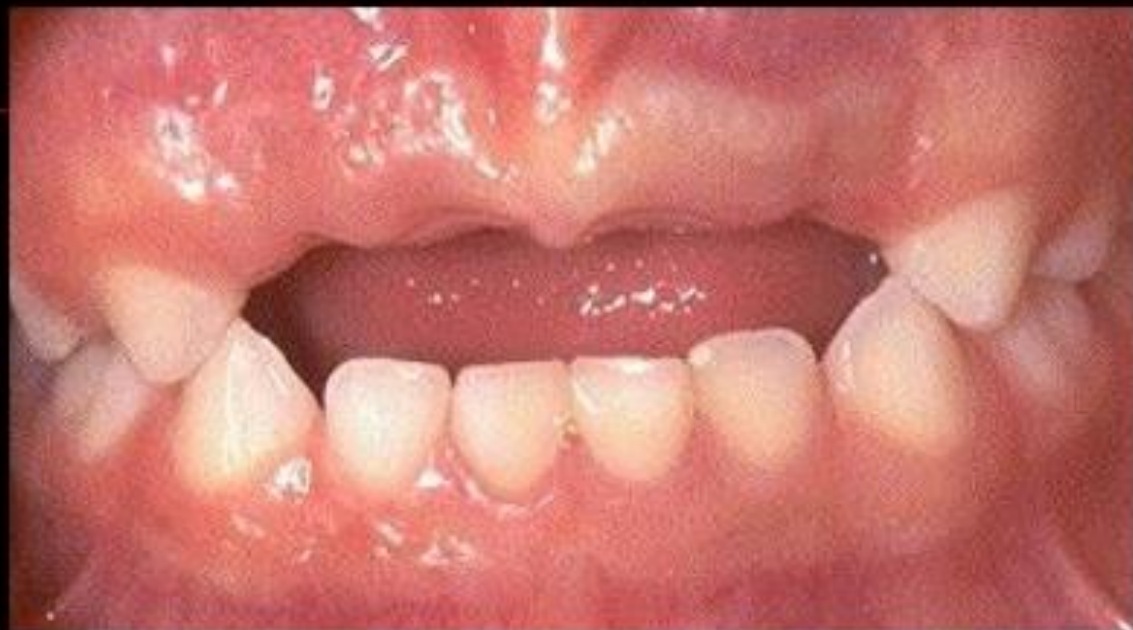space maintainer is indicated to prevent **mesial** movement of the second primary molar

A band and loop space maintainer is the best choice

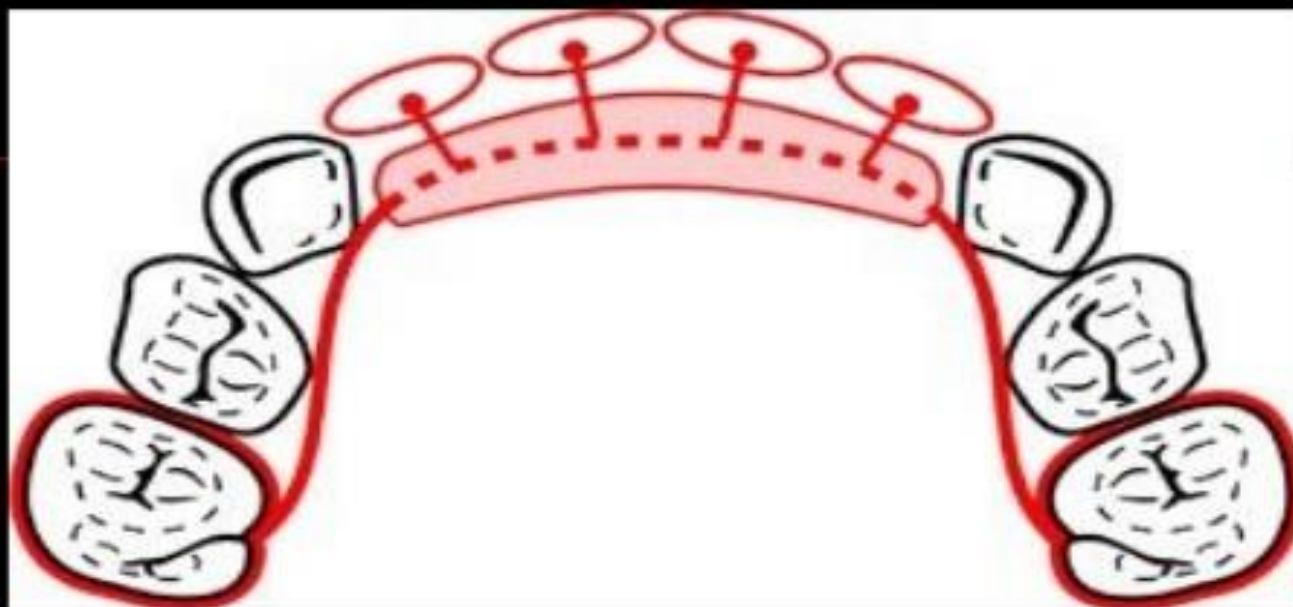


In this drawing, the maxillary primary central and lateral incisors are missing in this **four year-old child**. In your judgment, is the child in need of a space maintainer? If so, would you use a removable or a fixed space maintainer?

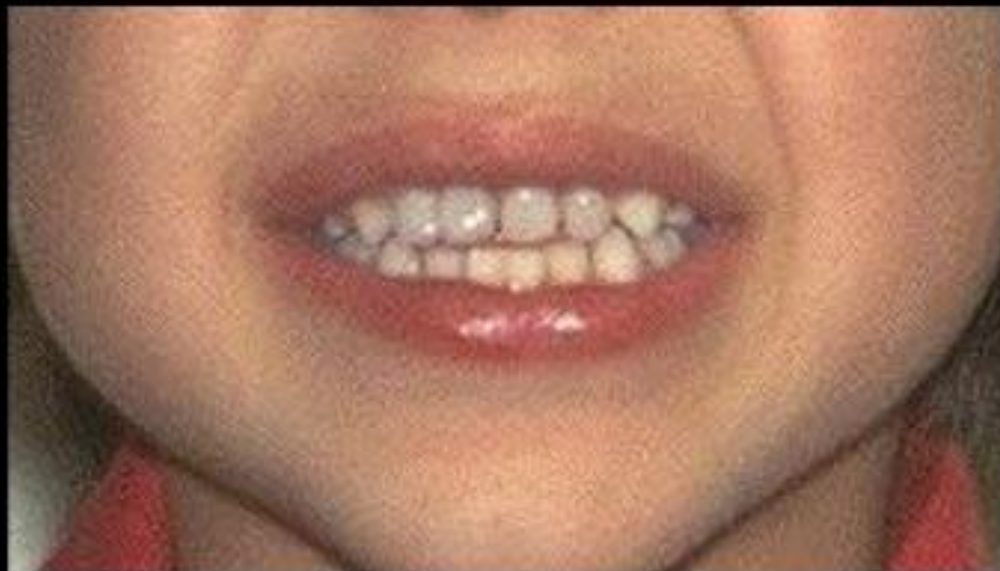
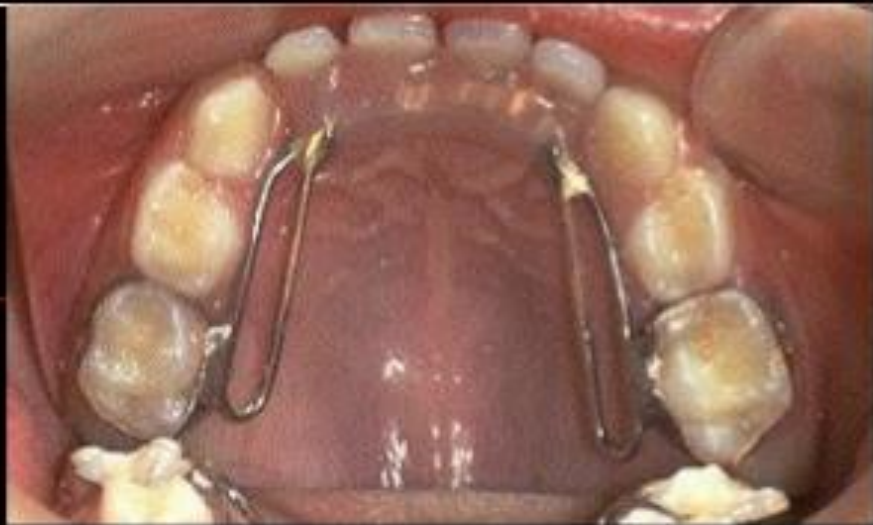


What is your recommendation for a case like this? The patient is age three and has multiple missing maxillary teeth.



As you can see demonstrated in red, a prosthetic appliance could be placed in this situation.



## SPACE MAINTENANCE IN MAXILLARY PRIMARY DENTITION

MISSING TOOTH	SUGGESTED TREATMENT	REASON
Incisor	No space maintenance required	No consequence. Exception if incisors are lost prior to primary canine eruption

<b>canine</b>	<b>Band &amp; loop space maintainer</b>	<b>Decrease possibility of midline shift</b>
I molar	Band /crown & loop space maintainer	Prevents loss of arch dimension
II molar	Distal shoe space maintainer	Guides I premolar into proper position Prevents loss in arch dimension

## SPACE MAINTENANCE IN MANDIBULAR PRIMARY DENTITION

MISSING PRIMARY TOOTH	SUGGESTED TREATMENT	REASON
canine	Band & loop space maintainer	Decreases possibility of midline shift
I molar	Band/crown loop space maintainer	Prevents loss of arch dimension

**II molar**

**Distal shoe  
space  
maintainer**

**Guides I  
permanent  
molar into  
position  
Prevents loss  
in arch  
dimension**



**THANK  
YOU!**