



Complete denture

Anatomical landmarks of the mandibular arch

M.Sc Sadiq Almayali

Lec. 3



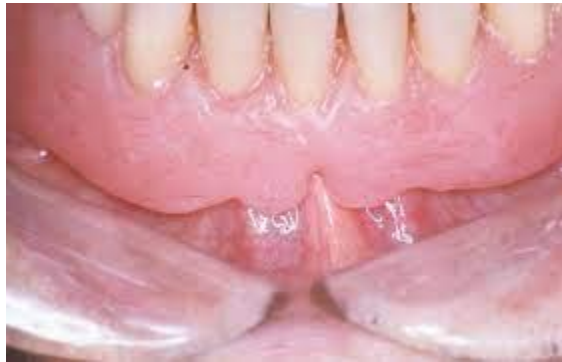Anatomical landmark of mandibular arch

Border Limiting Structures

They determine the border of the denture.

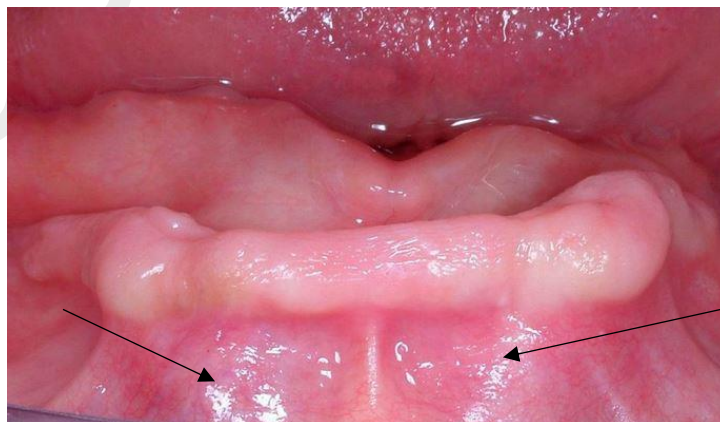
1. Labial Frenum

The mandibular labial frenum contains a band of fibrous connective tissue that helps in attachment of orbicularis oris muscle. It is sensitive and active during function of muscle therefore sufficient room must be achieved to avoid soreness. The labial frenum produces labial notch in the mandibular denture.



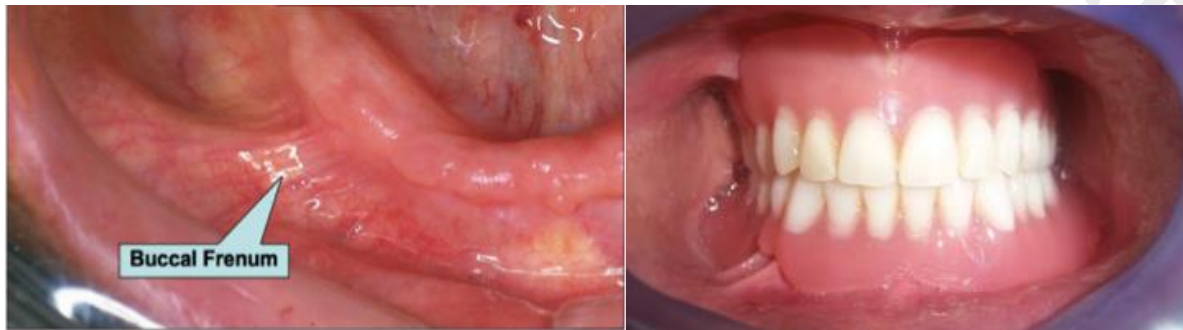2. Labial Vestibule

It extends from the labial frenum to buccal frenum. it is limited internally by the residual ridge and labially by the lip and inferiorly by the mucosa membrane reflection. In the denture, the area that fills the space called labial flange.



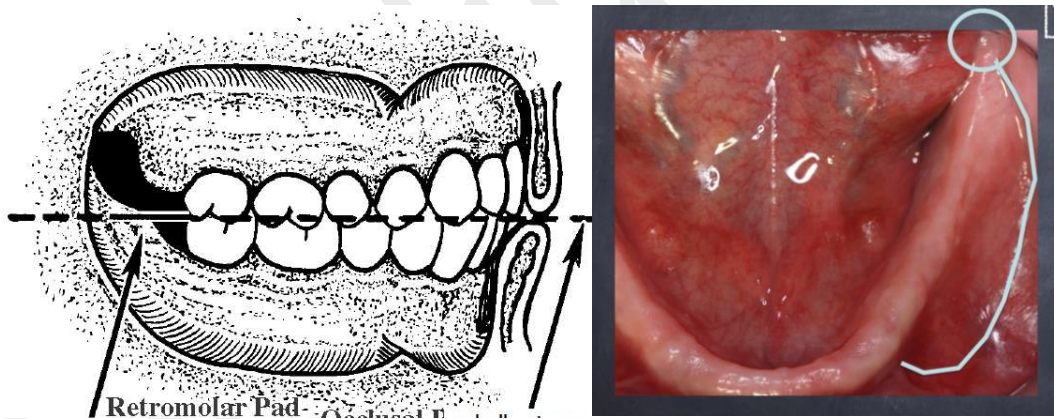
3. Buccal frenum

It is a single or multiple folds of mucous membrane extending from the buccal mucous membrane to the crest of the residual alveolar ridge. It is active during function of muscle therefore sufficient room must be achieved to avoid displacement of denture. it produces buccal notch in the mandibular denture.



4. Buccal vestibule

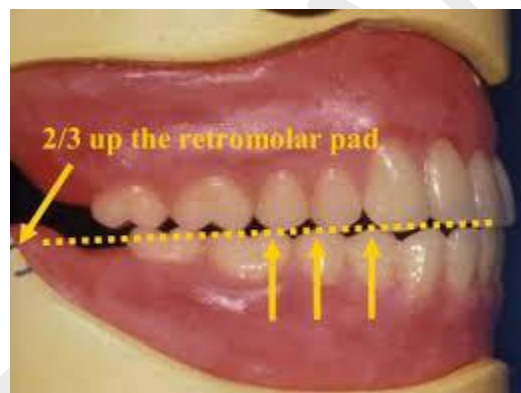
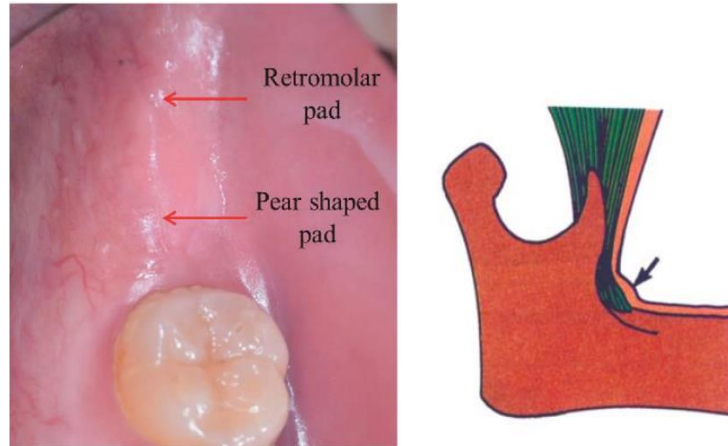
Extends from the buccal frenum to the retromolar pad area. It is bounded laterally by cheeks and medially by the residual alveolar ridge. it is occupied by the buccal flange of the denture.



5. Retromolar pad

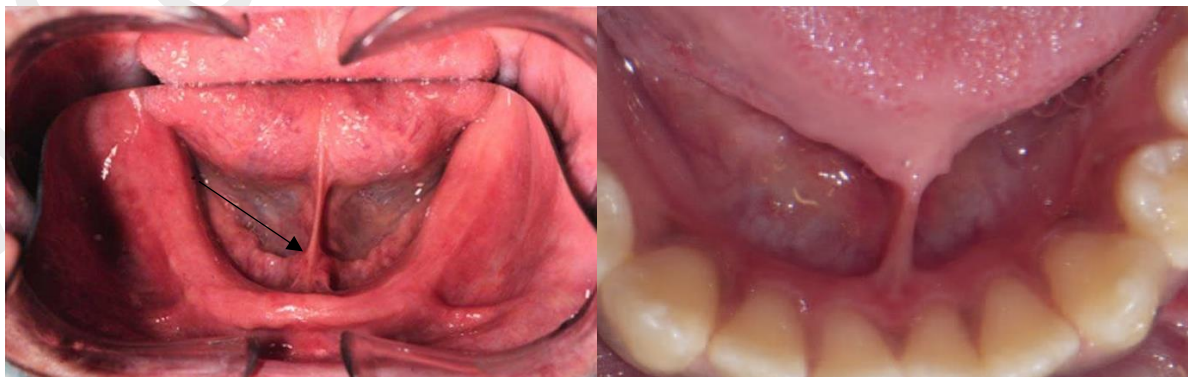
It is a triangular pear-shaped pad of tissue at the distal end of the ridge. It forms the posterior seal of the mandibular denture and helps in maintaining the occlusal plane. the denture base should extend two third over the retromolar pad area. It produces retromolar fossae in the denture.

- ✚ **Note:** Teeth should not be placed on the retromolar pad because the soft tissue and curvature of the mandible may lead to instability of the denture during function.



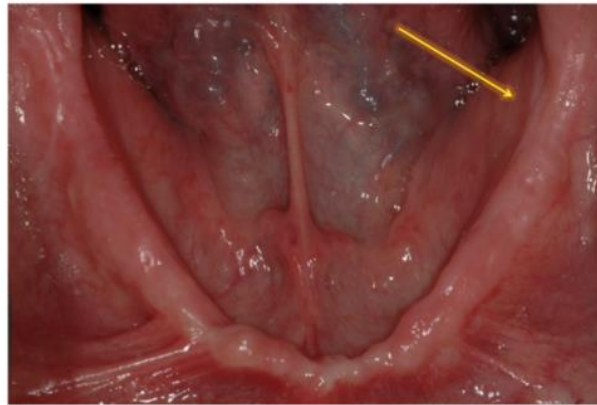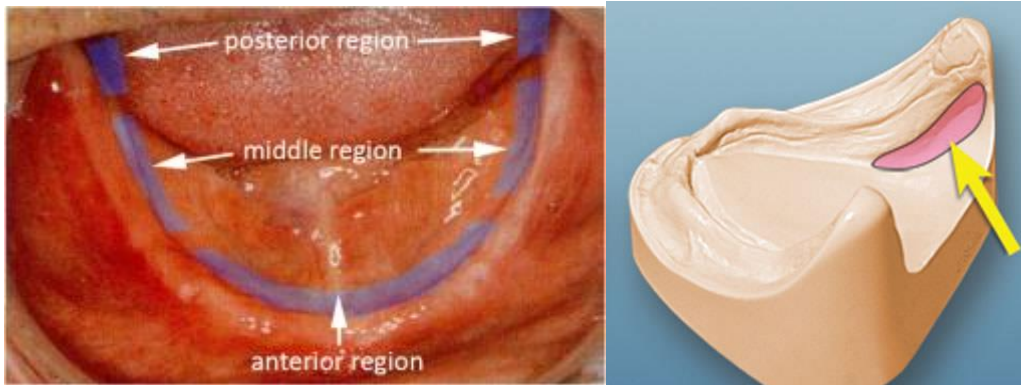
6. Lingual Frenum

It is a fold of mucous membrane joins the alveolar mucosa to the tongue. It overlies the genioglossus muscle. It produces notch in the mandibular denture.



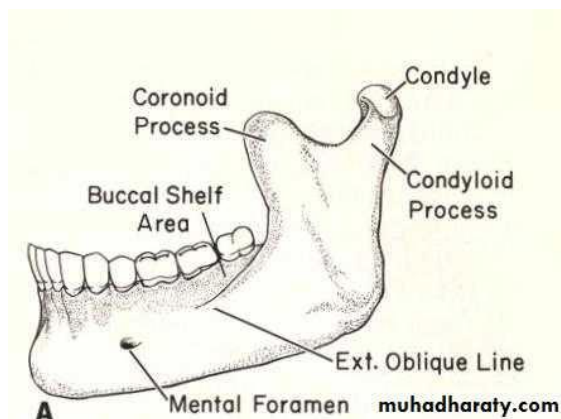
7. Alveololingual sulcus

It is the space between the tongue and the residual ridge and extends from the lingual frenum to the retromylohyoid curtain. It produces lingual flange in the denture. It is divided into three regions: anterior, middle and posterior.



8. External oblique ridge

It is a ridge of bone outside the buccal shelf. It determines the extension of mandibular buccal flange and produces the external oblique groove in the denture.



Supporting Structures

The support for a mandibular denture comes from the body of the mandible. The available denture-bearing area for an edentulous mandible is 14 cm² but for maxilla it is 24 cm². Therefore, the mandible is less capable of resisting occlusal forces.

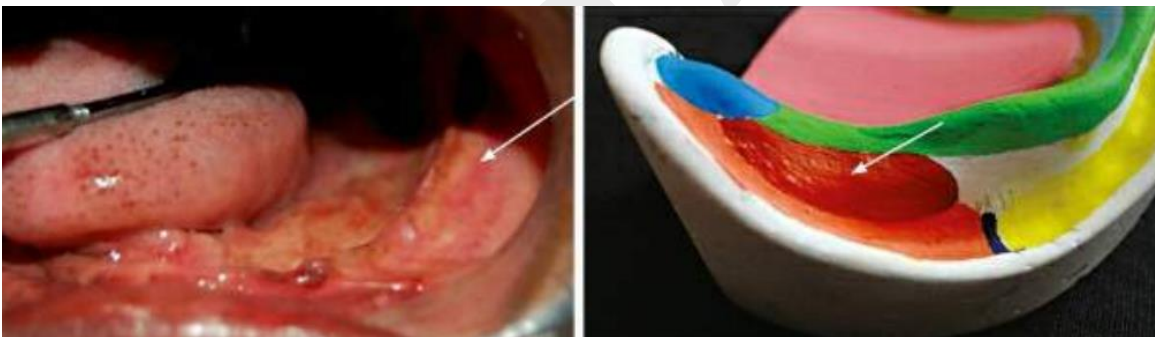
1. Buccal shelf

It is the area between the buccal frenum and anterior border of the masseter muscle.

Its boundaries are:

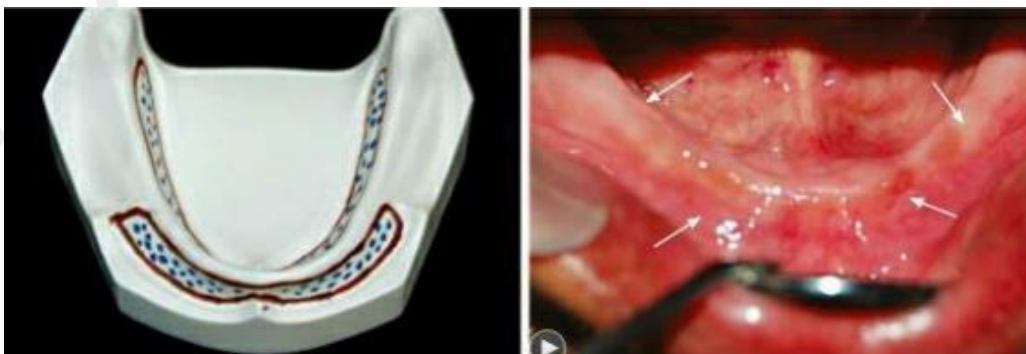- Medially - crest of the ridge
- Laterally - external oblique ridge
- Anteriorly - buccal frenum
- Distally - retromolar pad area

The buccal shelf lies at right angles to the vertical occlusal forces and is covered with good smooth cortical bone. therefore, it is the **primary stress-bearing area of the mandible**



2. Residual alveolar ridge

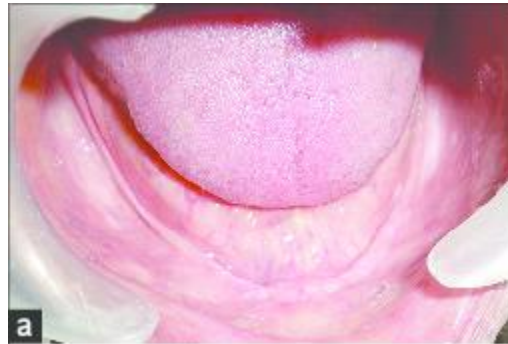The buccal and lingual slopes of the residual alveolar ridge considered as a **secondary stress-bearing area of the mandible**



Relief Areas

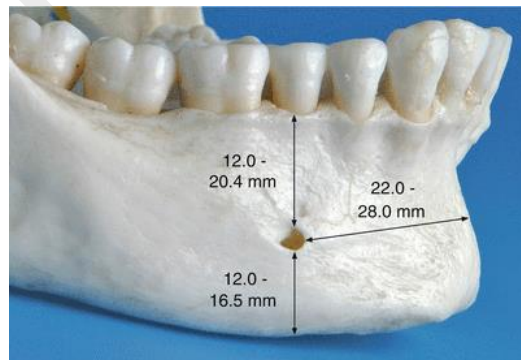
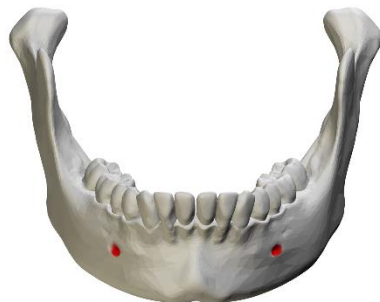1. Crest of residual alveolar ridge

This area can sometimes be present as sharp or knife-edged. Then it needs to be relieved.



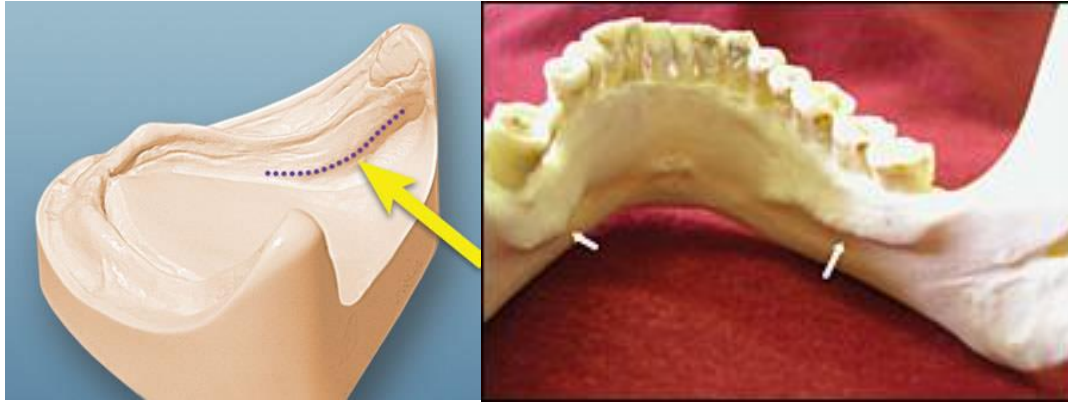
2. Mental foramen

It is bilateral openings through which the mental nerve exits the mandible, it lies between the first and second premolar region. Due to ridge resorption, it may lie close to the crest of the ridge, therefore, it should be relieved to prevent numbness of lower lip.



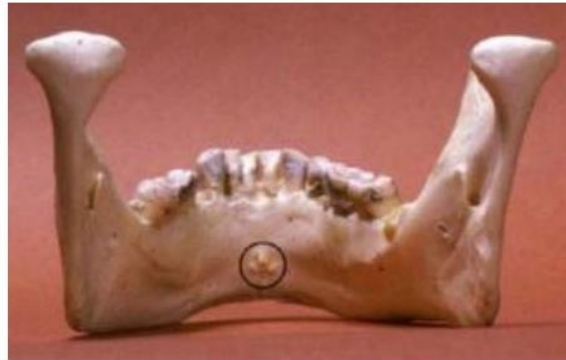3. Mylohyoid Ridge (internal oblique ridge)

It runs along the lingual surface of the mandible. The thin mucosa over the mylohyoid ridge may get traumatized and should be relieved.



4. Genial tubercles

These are a pair of bony elevations found anteriorly on the lingual side of the mandible. It can be prominent with severe resorption and may need relief.



5. Torus Mandibularis (mandibular tori)

It is bony prominence found bilaterally on the lingual side, near the premolar region. It is covered by a thin mucosa. It has to be relieved or surgically removed.



