

Physics of Medical Devices

Fourth, fifth lecture

The ECG wave form

Dr. Nasma Adnan

Fourth Stage

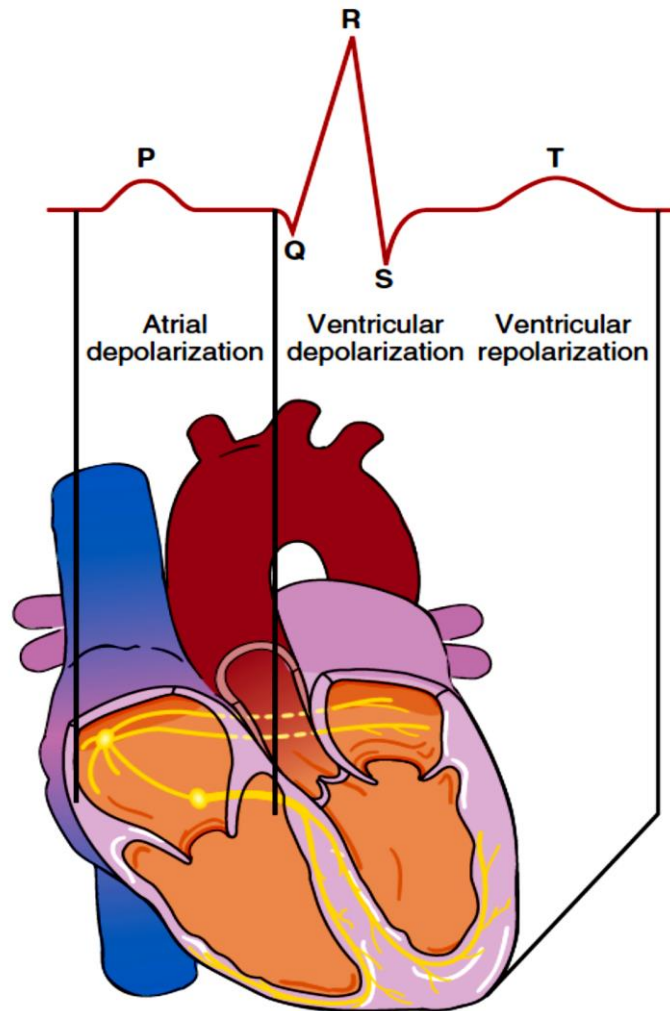
Department of medical physics

Al-Mustaqbal University-College

2021- 2022

The ECG wave form

Correlation of Depolarization and Repolarization with the ECG



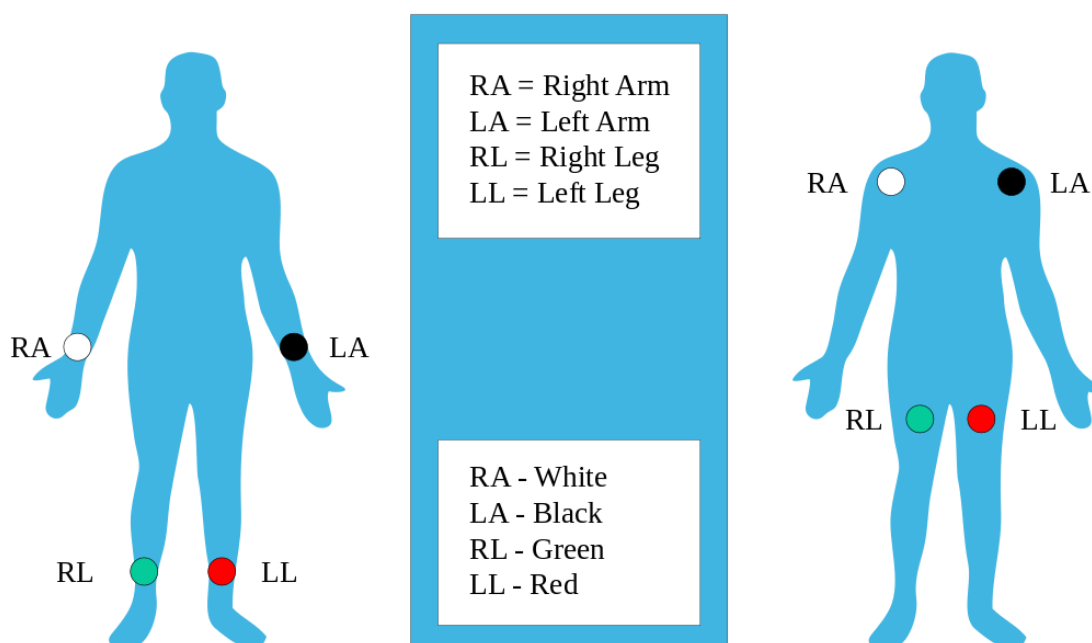
- ❖ Mechanical and electrical functions of the heart are influenced by proper electrolyte balance. Important components of this balance are sodium, calcium, potassium, and magnesium.
- ❖ The body acts as a giant conductor of electrical current. Electrical activity that originates in the heart can be detected on the body's surface through an electrocardiogram (ECG).

- ❖ Electrodes are applied to the skin to measure voltage changes in the cells between the electrodes. These voltage changes are amplified and visually displayed on an oscilloscope and graph paper.
- An ECG is a series of waves and deflections recording the heart's electrical activity from a certain "view."
- Many views, each called a lead, monitor voltage changes between electrodes placed in different positions on the body.
- Leads I, II, and III are bipolar leads and consist of two electrodes of opposite polarity (positive and negative). The third (ground) electrode minimizes electrical activity from other sources.
- Leads aVR, aVL, and aVF are unipolar leads and consist of a single positive electrode and a reference point (with zero electrical potential) that lies in the center of the heart's electrical field.
- Leads V1–V6 are unipolar leads and consist of a single positive electrode with a negative reference point found at the electrical center of the heart.
- An ECG tracing looks different in each lead because the recorded angle of electrical activity changes with each lead. Different angles allow a more accurate perspective than a single one would.
- The ECG machine can be adjusted to make any skin electrode positive or negative. The polarity depends on which lead the machine is recording.
- A cable attached to the patient is divided into several different-colored wires: three, four, or five for monitoring purposes, or ten for a 12-lead ECG.
- incorrect placement of electrodes may turn a normal ECG tracing into an abnormal one.

The standard lead system

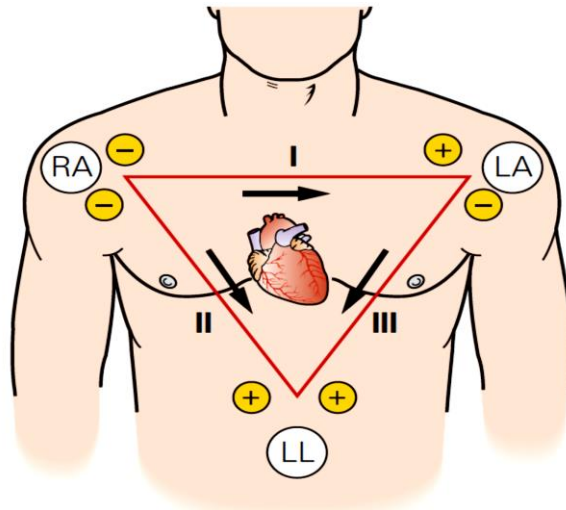
Electrodes are placed on the right arm (RA), left arm (LA), right leg (RL) and left leg (LL). With only four electrodes, six leads are viewed. These leads include the standard leads (I, II, and III) and the augmented leads (aVR, aVL, and aVF).

Standard Limb Lead Electrode Placement



Standard Limb Leads

Leads I, II, and III make up the standard leads. If electrodes are placed on the right arm, left arm, and left leg, three leads are formed. If an imaginary line is drawn between each of these electrodes, an axis is formed between each pair of leads. The axes of these three leads form an equilateral triangle with the heart in the center (Einthoven's triangle).

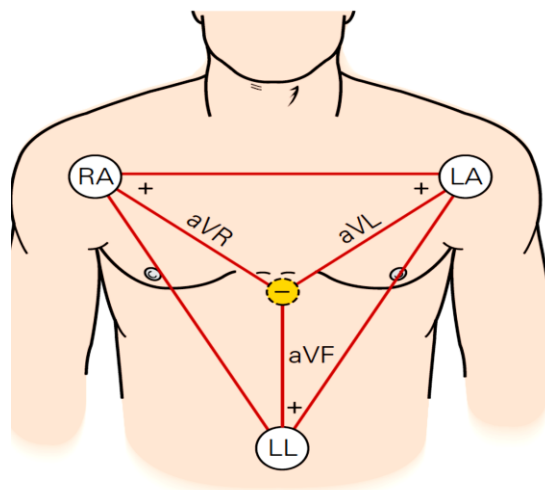


Elements of Standard Limb Leads			
Lead	Positive Electrode	Negative Electrode	View of Heart
I	LA	RA	Lateral
II	LL	RA	Inferior
III	LL	LA	Inferior

- ✓ Lead II is commonly called a **monitoring lead**. It provides information on heart rate, regularity, conduction time, and ectopic beats.

Augmented Limb Leads

Leads aVR, aVL, and aVF make up the augmented leads. Each letter of an augmented lead refers to a specific term: a = augmented; V = voltage; R = right arm; L = left arm; F = foot (the left foot).



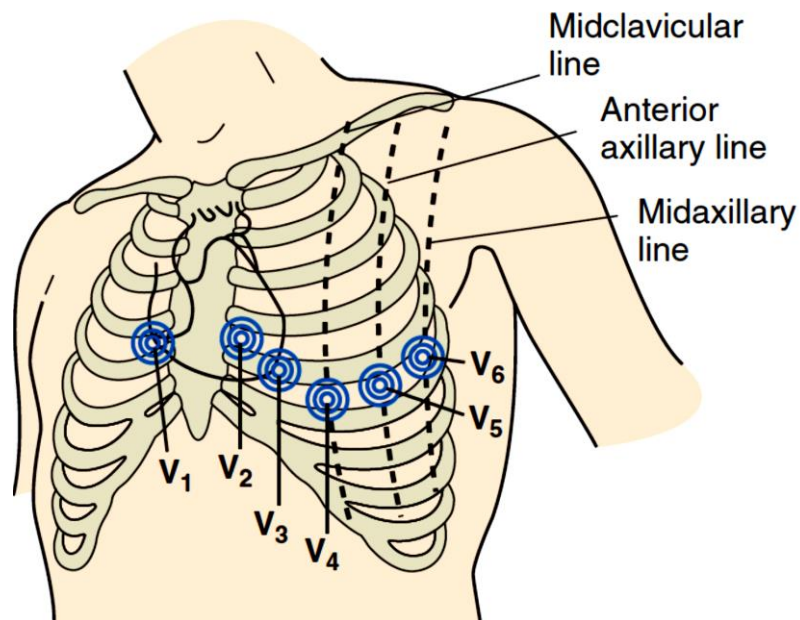
Elements of Augmented Limb Leads

Lead	Positive Electrode	View of Heart
aVR	RA	None
aVL	LA	Lateral
aVF	LL	Inferior

Chest Leads

Standard Chest Lead Electrode Placement

The chest leads are identified as V₁, V₂, V₃, V₄, V₅, and V₆. Each electrode placed in a "V" position is positive.

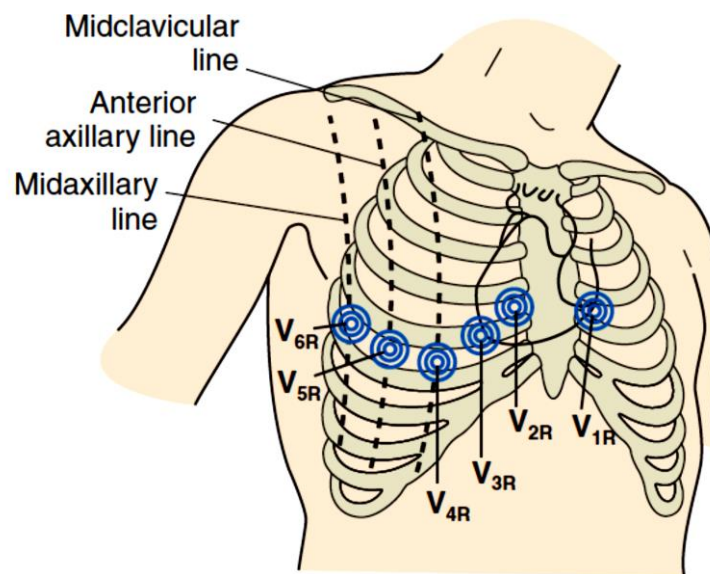


Elements of Chest Leads

Lead	Positive Electrode Placement	View of Heart
V ₁	4th Intercostal space to right of sternum	Septum
V ₂	4th Intercostal space to left of sternum	Septum
V ₃	Directly between V ₂ and V ₄	Anterior
V ₄	5th Intercostal space at left midclavicular line	Anterior
V ₅	Level with V ₄ at left anterior axillary line	Lateral
V ₆	Level with V ₅ at left midaxillary line	Lateral

The Right-sided 12-Lead ECG

- The limb leads are placed as usual but the chest leads are a mirror image of the standard 12-lead chest placement.
- The ECG machine cannot recognize that the leads have been reversed. It will still print "V₁–V₆" next to the tracing. Be sure to cross this out and write the new lead positions on the ECG paper.

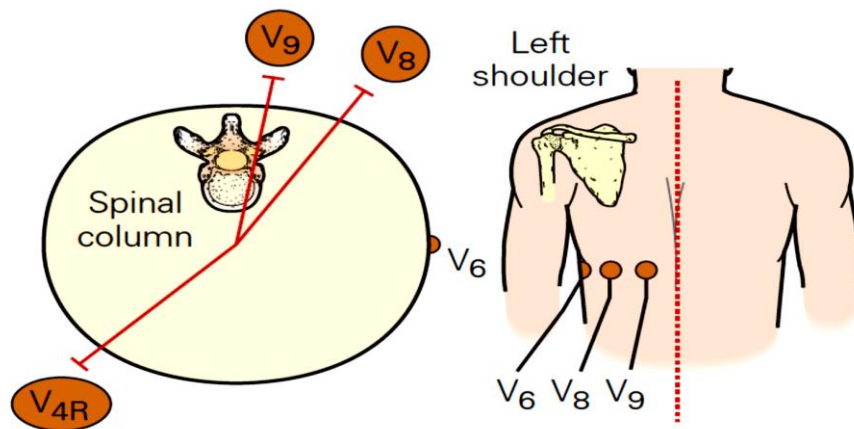


The Right-sided 12-Lead ECG	
Chest Leads	Position
V _{1R}	4th Intercostal space to left of sternum
V _{2R}	4th Intercostal space to right of sternum
V _{3R}	Directly between V _{2R} and V _{4R}
V _{4R}	5th Intercostal space at right midclavicular line
V _{5R}	Level with V _{4R} at right anterior axillary line
V _{6R}	Level with V _{5R} at right midaxillary line

The 15-Lead ECG

Areas of the heart that are not well visualized by the six chest leads include the wall of the right ventricle and the posterior wall of the left

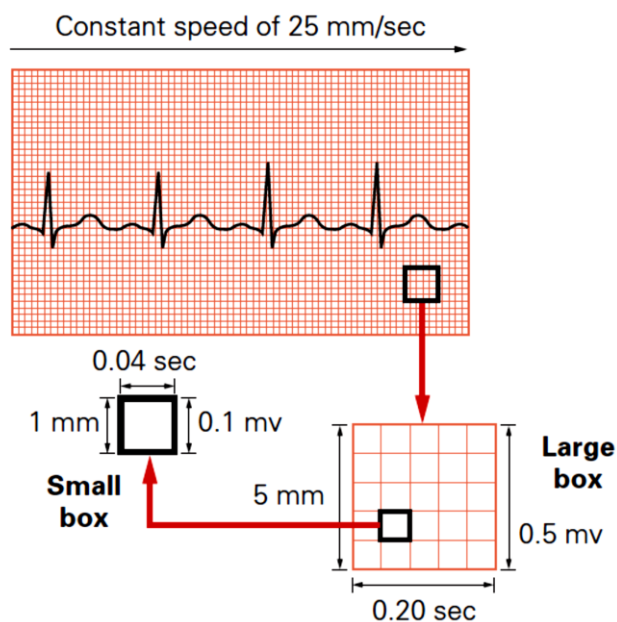
ventricle. A 15-lead ECG, which includes the standard 12 leads plus leads V_{4R}, V₈, and V₉, increases the chance of detecting an MI in these areas.



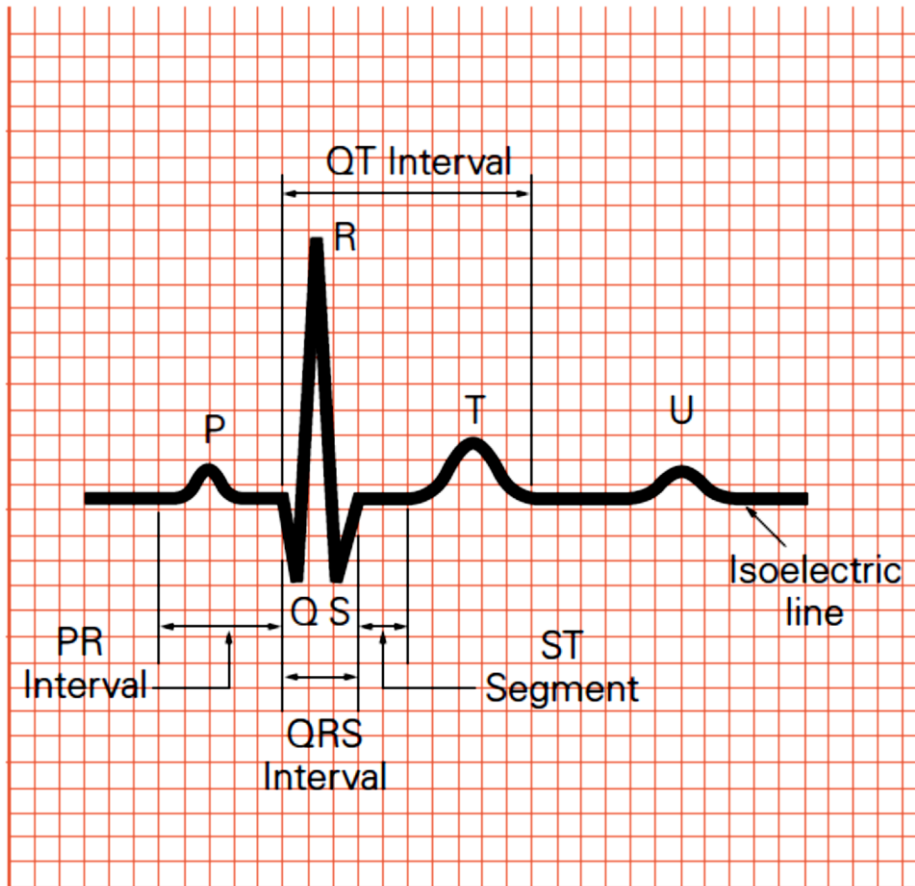
The 15-Lead ECG		
Chest Leads	Electrode Placement	View of Heart
V _{4R}	5th Intercostal space in right anterior midclavicular line	Right ventricle
V ₈	Posterior 5th intercostal space in left midscapular line	Posterior wall of left ventricle
V ₉	Directly between V ₈ and spinal column at posterior 5th intercostal space	Posterior wall of left ventricle

ECG readout

Recording of the ECG



Components of an ECG Tracing



Electrical Activity	
Term	Definition
Wave	A deflection, either positive or negative, away from the baseline (isoelectric line) of the ECG tracing
Complex	Several waves
Segment	A straight line between waves or complexes
Interval	A segment and a wave

Electrical Components	
Deflection	Description
P Wave	First wave seen Small rounded, upright (positive) wave indicating atrial depolarization (and contraction)
PR Interval	Distance between beginning of P wave and beginning of QRS complex Measures time during which a depolarization wave travels from the atria to the ventricles
QRS Complex	Three deflections following P wave Indicates ventricular depolarization (and contraction) Q Wave: First negative deflection R Wave: First positive deflection S Wave: First negative deflection after R wave
ST Segment	Distance between S wave and beginning of T wave Measures time between ventricular depolarization and beginning of repolarization
T Wave	Rounded upright (positive) wave following QRS Represents ventricular repolarization
QT Interval	Distance between beginning of QRS to end of T wave Represents total ventricular activity
U Wave	Small rounded, upright wave following T wave Most easily seen with a slow HR Represents repolarization of Purkinje fibers

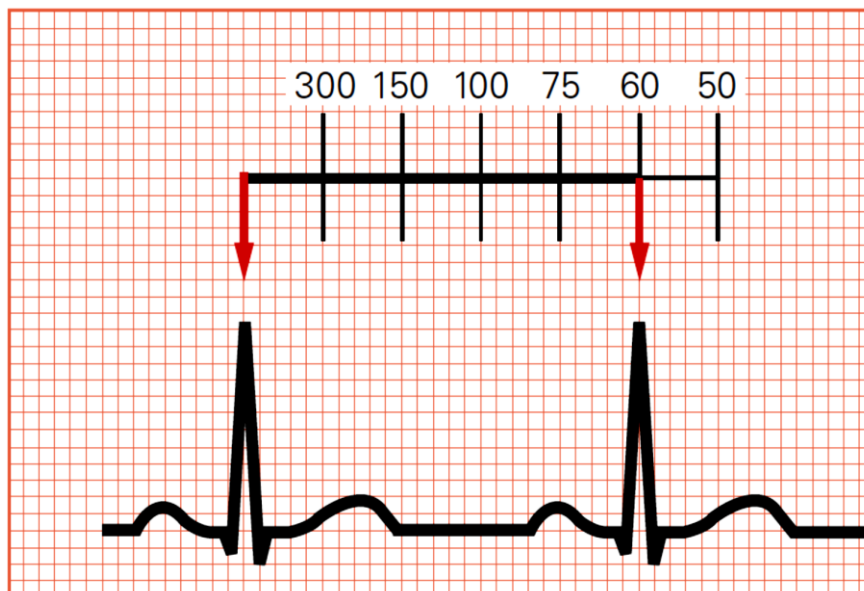
Methods for Calculating Heart Rate

- ✓ Heart rate is the number of times the heart beats per minute (bpm).
- ✓ On an ECG tracing, bpm is usually calculated as the number of QRS complexes.
- ✓ Included are extra beats, such as premature ventricular contractions (PVC), premature atrial contractions (PAC), and premature junctional contractions (PJC).
- ✓ The rate is measured from the R-R interval, the distance between one R wave and the next. If the atrial rate (the number of P waves) and the ventricular rate (the number of QRS complexes) vary, the analysis may show them as different rates, one atrial and one ventricular.

- ✓ The method chosen to calculate HR varies according to rate and regularity on the ECG tracing

Method 1: Count Large Boxes

Regular rhythms can be quickly determined by counting the number of large graph boxes between two R waves. That number is divided into 300 to calculate bpm. The rates for the first one to six large boxes can be easily memorized. Remember: 60 sec/min divided by 0.20 sec/large box = 300 large boxes/min.



Method 2: Count Small Boxes

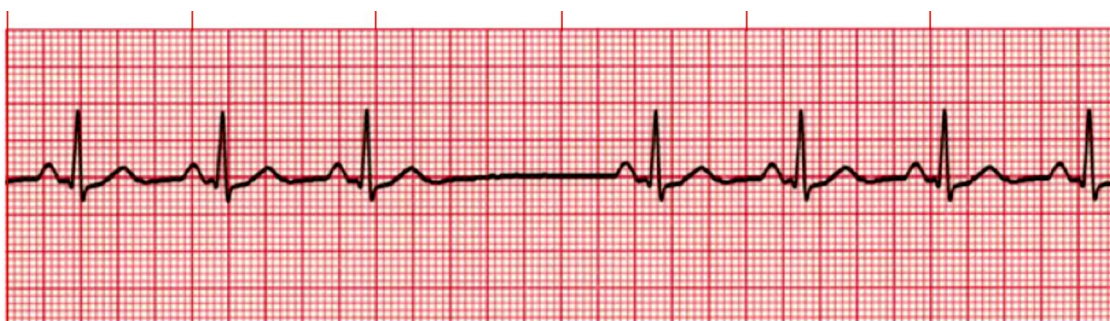The most accurate way to measure a regular rhythm is to count the number of small boxes between two R waves. That number is divided into 1500 to calculate bpm. Remember: 60 sec/min divided by 0.04 sec/small box = 1500 small boxes/min.

Examples: If there are three small boxes between two R waves: $1500/3 = 500$ bpm. If there are five small boxes between two R waves: $1500/5 = 300$ bpm.

Methods 1 and 2 for Calculating Heart Rate			
Number of Large Boxes	Rate/Min	Number of Small Boxes	Rate/Min
1	300	2	750
2	150	3	500
3	100	4	375
4	75	5	300
5	60	6	250
6	50	7	214
7	43	8	186
8	38	9	167
9	33	10	150
10	30	11	136
11	27	12	125
12	25	13	115
13	23	14	107
14	21	15	100
15	20	16	94

Method 3: Six-Second ECG Rhythm Strip

The best method for measuring irregular heart rates with varying R-R intervals is to count the number of R waves in a 6-sec strip (including extra beats such as PVCs, PACs, and PJC) and multiply by 10. This gives the average number of beats per minute.



Using a 6-sec ECG rhythm strip to calculate heart rate: 7 x 10 = 70 bpm.

ECG Interpretation

Analyzing a Rhythm	
Component	Characteristic
Rate	The bpm is commonly the ventricular rate If atrial and ventricular rates differ, as in a 3rd-degree block, measure both rates Normal: 60–100 bpm Slow (bradycardia): <60 bpm Fast (tachycardia): >100 bpm
Regularity	Measure R-R intervals and P-P intervals Regular: Intervals consistent Regularly irregular: Repeating pattern Irregular: No pattern
P Waves	If present: Same in size, shape, position? Does each QRS have a P wave? Normal: Upright (positive) and uniform Inverted: Negative Notched: P' None: Rhythm is junctional or ventricular
PR Interval	Constant: Intervals are the same Variable: Intervals differ Normal: 0.12–0.20 sec and constant
QRS Interval	Normal: 0.06–0.10 sec Wide: >0.10 sec None: Absent
QT Interval	Beginning of QRS complex to end of T wave Varies with HR Normal: Less than half the RR interval
Dropped beats	Occur in AV blocks Occur in sinus arrest
Pause	Compensatory: Complete pause following a premature atrial contraction (PAC), premature junctional contraction (PJC), or premature ventricular contraction (PVC) Noncompensatory: Incomplete pause following a PAC, PJC, or PVC

QRS Complex grouping	Bigeminy: Repeating pattern of normal complex followed by a premature complex Trigeminy: Repeating pattern of 2 normal complexes followed by a premature complex Quadrigeminy: Repeating pattern of 3 normal complexes followed by a premature complex Couplet: 2 Consecutive premature complexes Triplet: 3 Consecutive premature complexes
----------------------	--

Classification of Arrhythmias

Heart Rate	Classification
Slow	Bradycardia
Fast	Tachycardia
Absent	Pulseless arrest

Normal Heart Rate (bpm)

Age	Awake Rate	Mean	Sleeping Rate
Newborn to 3 months	85–205	140	80–160
3 months to 2 years	100–190	130	75–160
2 to 10 years	60–140	80	60–90
>10 years	60–100	75	50–90