

## Medical parasitology

### Hemoflagellates (blood and tissue flagellates)

Two genera within hemoflagellates infect human which are:

- Genus *Leishmania*
- Genus *Trypanosoma*

#### \*Morphological forms of hemoflagellates

**1-Amastigote (*Leishmania*)** form Round or oval in shape, 2-5 microns in diameter, surrounded by delicate cell membrane, have single vesicular nucleus with large central karyosome, the kinetoplast (which consists from dot-like blepharoplast and parabasal body beside it) lies at right angle to the nucleus. Closely located nucleus and kinetoplast known as torpedo form. The axoneme is a delicate membrane extends from the kinetoplast to the margin of the body and represents the rest of the flagellum . This form has no free flagellum.

#### **2-Promastigote (*leptomonad*)** form :

Elongated (spindle in shape) have centrally located nucleus and the kinetoplast situated at the anterior end. The vacuole lying in front of the kinetoplast. From blepharoplast, single free flagellum projects from the anterior end, equal or longer than the body length .This form has no undulating membrane.

#### **3-Epimastigote (*crithidia*)** form :

Elongated form, longer and slightly wider than promastigote nucleus rear middle, kinetoplast is anterior to the nucleus. From blepharoplast flagellum arise forming the undulating membrane extending half of the body length, and a free flagellum project from the anterior end

**. 4-Trypomastigote (*Trypanosome*)** form : Elongated form with highly polymorphism from rather short and stumpy to a long slender. Nucleus near middle, kinetoplast is at the posterior end , the flagellum and

undulating membrane pass anteriorly along entire body length and free flagellum extends from anterior end when present .

### **Blood and Tissue Flagellates**

Blood and tissue flagellates belong to the family Trypanosomatidae, class : Kinetoplastidae ,they possess a single nucleus ,a single kinetoplast a single flagellum. This family consist of six genera ,of which *Leishmania* and *Trypanosoma* are pathogenic to man . Species of this family may exist in two or more form ( polymorphism ).

#### **Genus: *Leishmania***

The genus leishmania is characterized by two different stages in its life cycle each of which occurs in a distinct host . **The Amastigote stage** found in the cytoplasm of reticulo-endothelial cell and there reproduction is by binary fission. The other stage takes place in the gut of Phlebotomine sand flies ,where the parasite develops as **Promastigote** .

Leishmaniasis are transmitted by sand flies and cause the following main forms of leishmaniasis in warm regions :-

- ❖ *Leishmania tropica* ( cutaneous leishmaniasis ) *Phlebotomus* sandfly
- Leishmania donovani* (visceral leishmaniasis)
- ❖ *Leishmania braziliensis* ( muco-cutaneous L.) *Lutzomyia*

#### **Life cycle :**

The species of the genus *Leishmania* pathogenic to human do not show morphological differences. They can be differentiated on the basis of biological criteria , laboratory analyzed, the different clinical picture and epidemiological facts. In human and other vertebrates *Leishmanias* parasitize in mononuclear phagocytic cells (macrophages, monocytes,

Langerhans cells) in amastigote forms, this stage ingested by the insect with a blood meal are transformed in its intestine into slender, flagellated promastigote form which multiply and migrate back into the proboscis. At tropical temperatures this process takes five to eight days. When an infected sand fly takes another blood meal, the promastigote forms which are inoculated and parasitized into a new host (human and other vertebrates).

. After reproduction of amastigote by binary fission are ruptured, liberating amastigotes that are engulfed by other phagocytic cells. Biting sand flies pick up both free amastigotes and free parasitized cells.

### **L. tropica:**

#### **Clinical Feature:**

Incubation period is 6 months, it causes disease called Oriental sore, Delhi sore or Baghdad boil, lesions are cutaneous (exposed parts). Lesion starts as a granulomatous nodule surrounded by a red margin.

#### **Pathology:** (Cutaneous Leishmaniasis)

Deposition of promastigotes either as a result of bite of infected sand fly on the surface of skin, or by entering through a puncture wound and transferred into amastigote form inside reticuloendothelial cells of the skin. A cutaneous lesion develops at the site of infective sandfly bite. In the early stage, the lesion is due to the proliferation of reticuloendothelial cells of skin that contain a large number of amastigotes, then the lesion begins as a raised papule about 2.5 cm in diameter. In majority of cases, necrosis and then ulcer formation occurs as a result of disturbance of blood supply. At this stage, the parasite is found along the red margin and not on the floor of the ulcer. The ulcer heals spontaneously, in about 6 months, leaving a depressed scar and a solid immunity.

**Laboratory Diagnosis:** Smear from specimen collected by puncturing the edge of lesion is prepared and stained with leishmania stain to demonstrate amastigote form, material may also cultured on NNN medium to demonstrate promastigote form.

**Treatment:** Such patient, requires treatment with pentavalent antimonial drugs in double doses and this treatment should be continued for long time.

### **Leishmania donovani**

**Geographical distribution and habitat :** Visceral leishmaniasis is widely distributed ,it is endemic in many places in America , Africa, China , South Europe and India. The natural habitat of L.d. in man is reticulo-endothelial system specially spleen , liver, bone marrow and intestinal mucosa. It may be found in endothelial cells of kidneys, suprarenal capsules, lung cerebrospinal fluid and also in the macrophages of intestinal wall. Vector is (Phlebotomus sergenti ).

### **Pathology and Clinical Picture : -**

- Enlarged grossly, and Cut surface shows congestion of liver & spleen
- In bone marrow, Macrophage loaded with L.d. bodies and plasma cells abundantly replace hematogenous tissue.
- Cloudy swelling of kidney - Degeneration myocardis .
- Anemia
- Intestine may present with ulcer because of secondary infection.

**Clinical Picture :** Irregular fever ,loose of weight, marked emaciation and anemia dry skin and brittle hair, pigmentation of the skin and loose of appetite.

**Laboratory Diagnosis :** Demonstration of L.d.bodies (amastigote) from specimens ( blood, spleen, bone marrow, liver ,etc.):

- a) Biopsy or aspirate from these organs is smeared on clean glass slide fixed with methyl alcohol and stained with Giemsa stain.
- b) Animal inoculation is performed by injecting intraperitoneally the inoculated animals are kept at 26°C. Amastigote form of parasite is recovered from injected animals.
- c) Culture may be done on special types of media.
- d) serological test. e) Immunological test.

**Treatment:**

Pentavalent antimonial drugs, meglumine antimonite, sodium stiboglucomate. Other drugs like pentamidine , amphotericin B are used as an alternative to pentavalent.

**Leishmania braziliensis ( muco-cutaneous leishmaniasis )**  
**Geographical distribution and habitat**

Central and south America. Amastigote form occurs in the macrophages of skin and mucous membrane of the nose and buccal cavity (Vector is forest sand fly , Lutzomyia,)

**Clinical Feature :** A specific ulceration granuloma of the skin occur after inoculation period ,few days, later the lesion involves mucosa of mouth ,nose, pharynx, and larynx, the lesions may be papules, nodules , or ulcers.

**Pathology :**The initial lesion has tendency to enlarge radially form in an ulcer with clear cut margin and oozing surface, Amastigotes are there in large number towards the periphery of lesion.

**Diagnosis and treatment:** Similar to all three species .

المحاضرة السادسة - طفيليات نظري - المرحلة الثانية

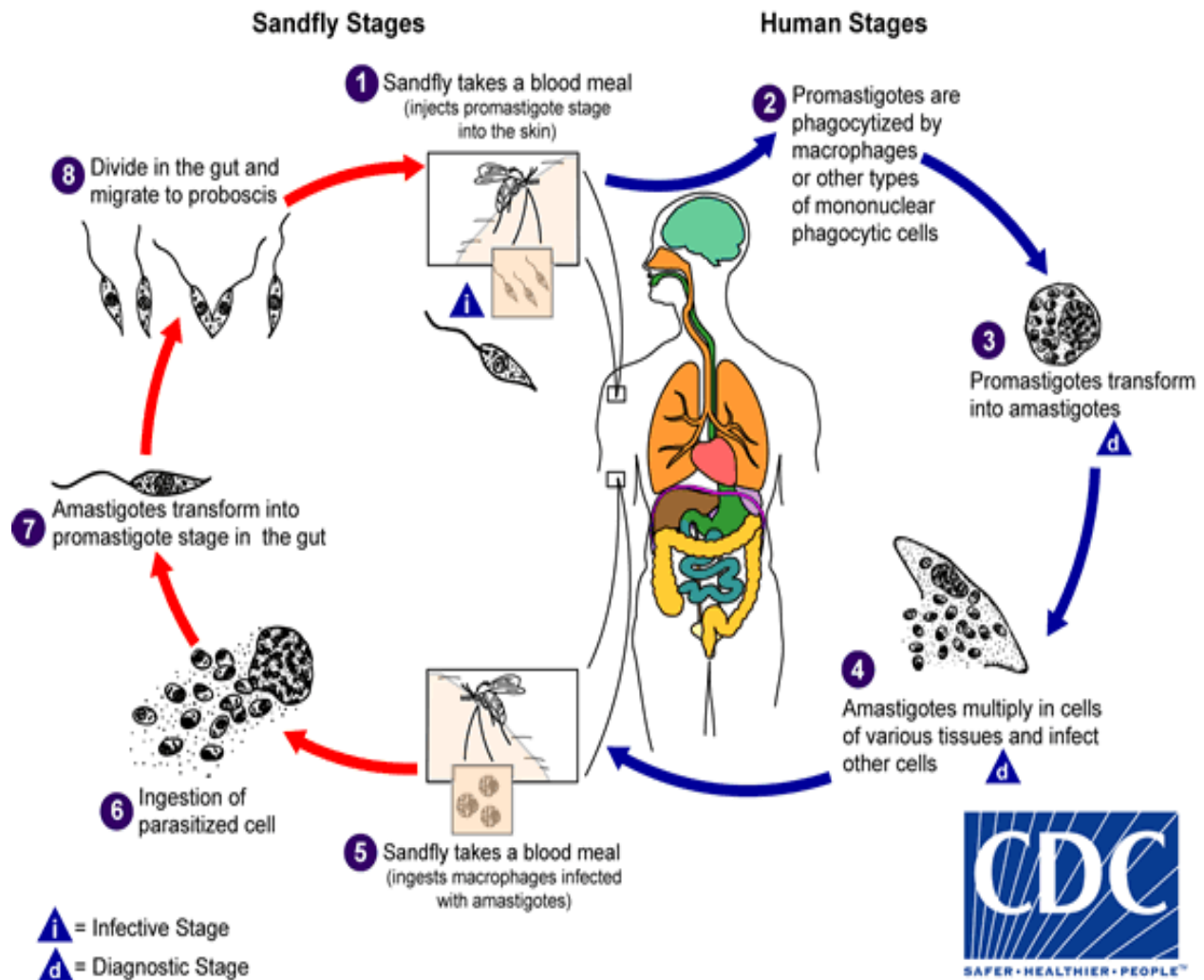


Figure (1) life cycle of the *Leshmania* parasite.

المحاضره السادسه - طفيليات نظري -المرحله الثانيه