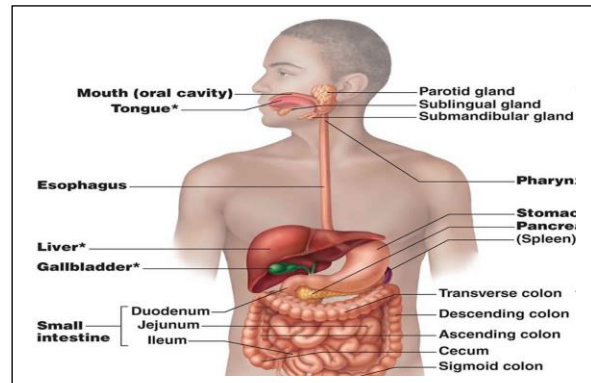


Lab:8 (gastrointestinal tract)

Mouth → pharynx → esophagus → stomach → small intestine → large intestine.

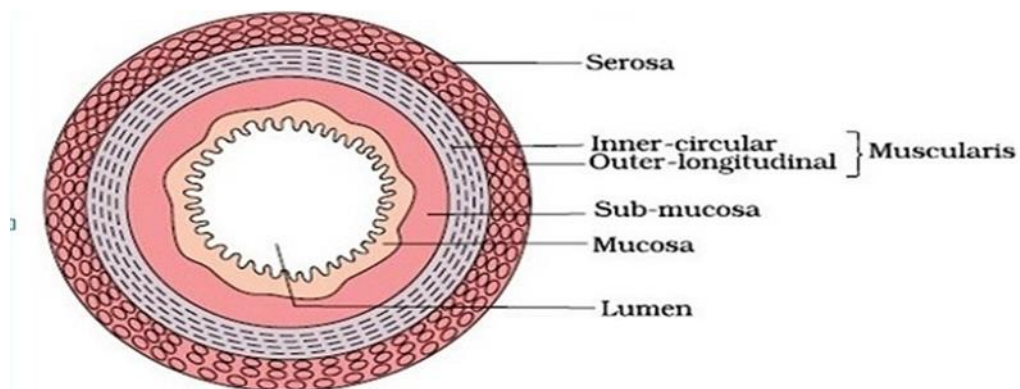
accessory organs

- ✓ salivary glands
- ✓ teeth
- ✓ liver
- ✓ gall bladder
- ✓ pancreas



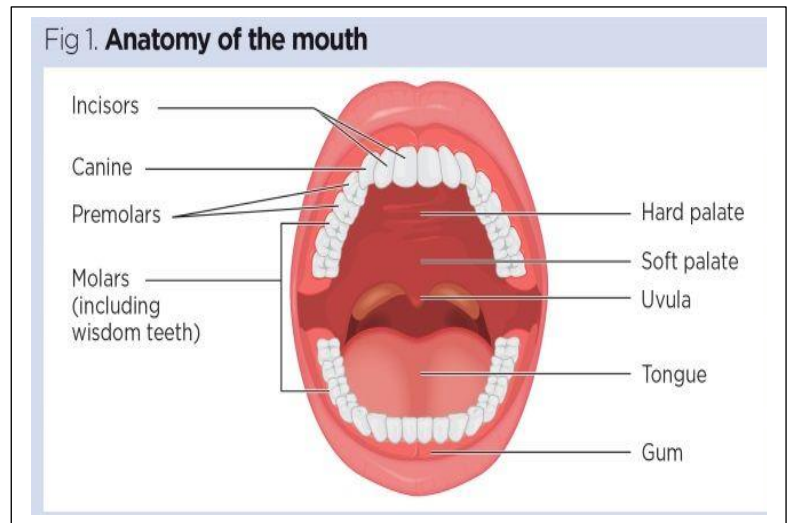
The wall of the alimentary canal consists of 4 layers:

- Outer **serosa**: visceral peritoneum, mainly fibrous and areolar CT
- ↓
- muscular**: is several layers of smooth muscle
- sub mucosa**: blood vessels, lymphatic vessels, nerves, connective tissue
- ↓
- Inner **mucosa**: mucous membrane lining.



Oral Cavity (Mouth) Anatomy

1. Lips
2. Cheeks
3. Tongue
4. Teeth
5. Hard palate and Soft palate
6. Gums.



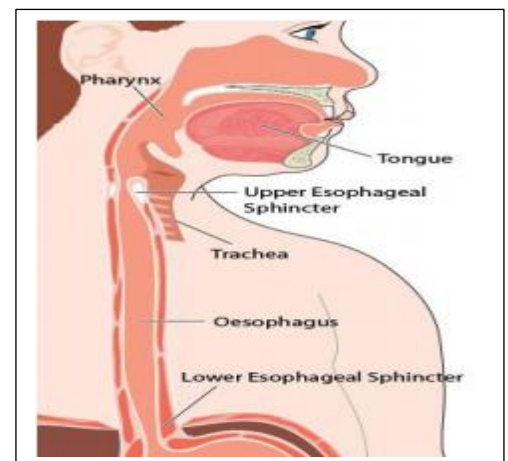
Pharynx

The pharynx, usually called the throat, is part of the respiratory system and digestive system. It carries air, food and fluid down from the nose and mouth. It contains three sections: the nasopharynx, oropharynx and laryngopharynx.

Esophagus

Location : extend from pharynx to stomach through the diaphragm.

- ✓ contain 2 Esophageal Sphincters:
- ✓ Upper Esophageal Sphincter
- ✓ Lower Esophageal Sphincter



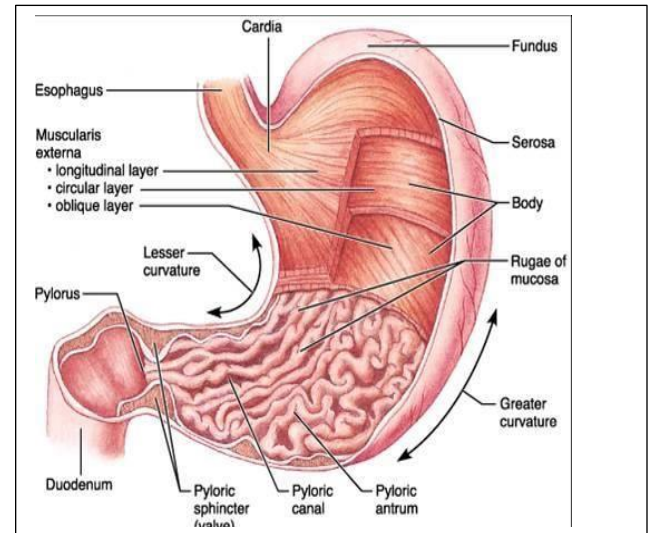
Stomach

- ✓ Location: on the left side of the abdominal cavity
- ✓ Openings: Two

1. Upper opening(cardiac opening).
2. Lower opening (pyloric sphincter).

Regions:

- 1) Cardiac region: position is near the heart.
- 2) Fundus region
- 3) Body: mid portion (largest part).
- 4) Pylorus: funnel-shaped terminal end.

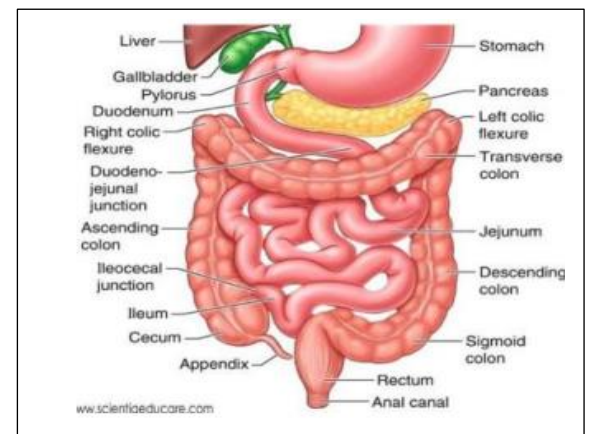


Small Intestine

- ✓ Location : within the abdominopelvic cavity
- ✓ composed of three subdivisions:

- ✓ Duodenum
- ✓ Jejunum
- ✓ Ileum

- ✓ The wall of the small intestine contain
- ✓ Circular folds
- ✓ Villi: fingerlike structures
- ✓ Microvilli: tiny projections of the plasma membrane.



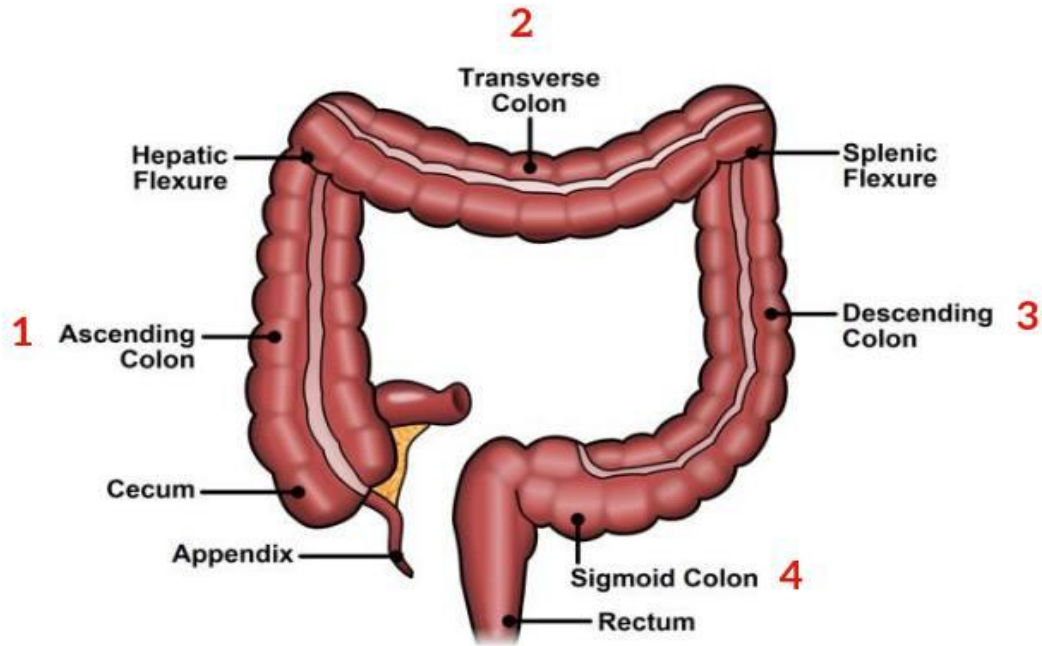


Large Intestine

Larger in diameter
composed of :

- ✓ Cecum
- ✓ Appendix
- ✓ Colon: divided into four sections
 - Ascending colon
 - Transverse colon
 - Descending colon
 - Sigmoid colon
- ✓ Rectum
- ✓ Anal canal and Anus
 - ✓ Anal canal contain :
 - External anal sphincter formed by skeletal muscle
 - Internal involuntary sphincter formed by smooth muscle.

The colon is divided into four sections



احذر أن يستولي عليك الإحباط فتصبح صفراً في الحياة، اصبر ، وقاوم ، وتحمل فالعثرة التي تسقطك .. أحياناً تُنعشك أزماناً

سَيمرُ كُلُّ مُر

افتخر بإنجازاتك مهما كانت صغيرة

أن تحقق هدفاً صغيراً كل يوم يعلو بك على سلم النجاح، خيرٌ من أن لا تنجز

عيد مبارك .. أعادهُ الله عليكم بالصحة والعافية

د. زهراء ماجد ..