

Selection Of Artificial Teeth

Teeth selection is very important as the selection of the appropriate shade, size, and form of the artificial teeth determines the esthetic and function of the denture.

Objectives of teeth selection

1. The teeth should be in harmony with the surrounding tissues.
2. They should maintain the vertical dimension.
3. They should be efficient for mastication.
4. Anterior teeth are selected based on esthetic, whereas the posterior teeth should be selected based on the function.

I- Selection of Anterior teeth:

Anterior teeth are primarily selected to satisfy esthetic requirements, so the dentist's professional obligation is to give the patient adequate information, guidance, and opportunity to choose their teeth. Anterior teeth selection is the area of prosthodontic care in which the patient should be given a primary responsibility to determine the esthetic outcome.

Preextraction records for artificial teeth selection:

- 1- Preserved extracted teeth.
- 2- Previous diagnostic casts with natural teeth.
- 3- Pre-extraction radiograph.
- 4- Pre-extraction photograph.
- 5- Observation of teeth of close relatives.
- 6- The old denture might help in teeth selection by ask the patient, it (like or dislike) the teeth then and decide change or not.

Factors of selecting of anterior teeth

1. Shade. 2. Size. 3. Form.

1. Shade: It is the degree of darkness of the color. There are two basic shades, the yellow and grey, and the other shades vary in between. Many patients will ask for very light shade, tell them that the proper shade gives more natural appearance, never force the patient to accept a shade that they do not want, they will never be satisfied with the denture.

The factors of shade selection:

1- Age: The younger the patient, the lighter the shade is preferred. The shade of natural teeth will be darkening with age because of:

- A. Deposition of secondary dentin.

- B. Consequent reduction in size of the pulp chamber.

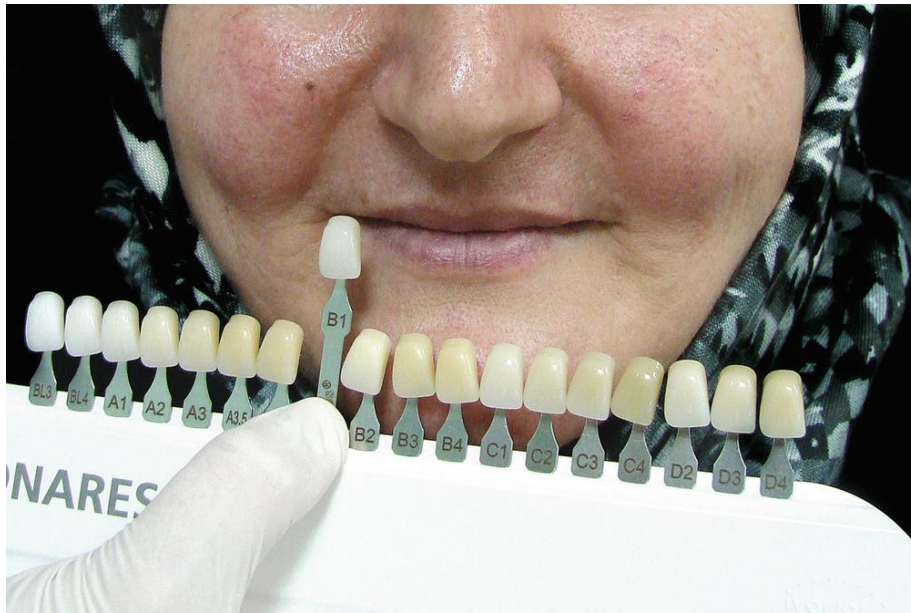- C. Wearing away of enamel.

- D. External staining of the exposed dentin from oral fluids, foods, or tobacco.

2- Gender: The gender may affect the shade; it seems that females are given lighter and brighter teeth than males.

3-Complexion: The color of the face should harmonize the shade of the teeth. Lighter teeth are suitable for lighter skin, while darker teeth are suitable for darker skin. Although people with dark skin seemed to have very light teeth, this is because of contrast in the skin and teeth color.

4- Patient preference: Show the patient a complete shade guide and select the two tabs that are the lightest and the darkest, hold them against the patient lip and ask them to point to the one that they prefer this method called (method of pair comparison). More than two or three shades should be selected and comparison between them would help in final right selection.



Method of pair comparison with the Shade guide.

2. Size. To select the size of anterior teeth, we have to consider the following:

1- Length. The length of anterior teeth is controlled by:

a. Length of upper lip:

- In short lip more than 2 mm seen from the maxillary central incisors.
- In medium lip length 1.5-2 mm seen from the maxillary central incisors.
- In long lip nothing can be seen from the maxillary central incisors.

b. Level of lower lip: Length of mandibular anterior teeth should be with the level of lower lip.

c. Inter-ridge distance:

When the space is available, it is more esthetically acceptable to use a tooth long enough to eliminate the display of the denture base (teeth are more attractive in appearance than denture base materials).

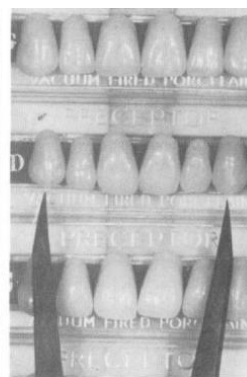
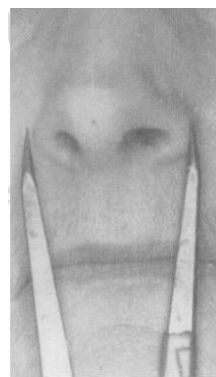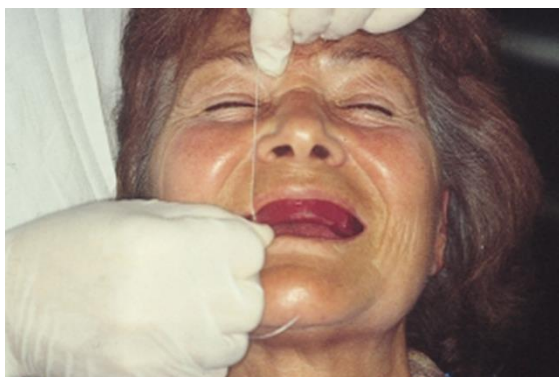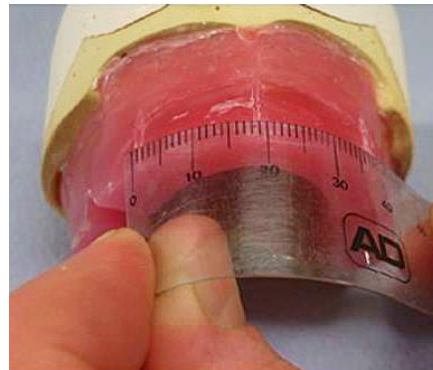
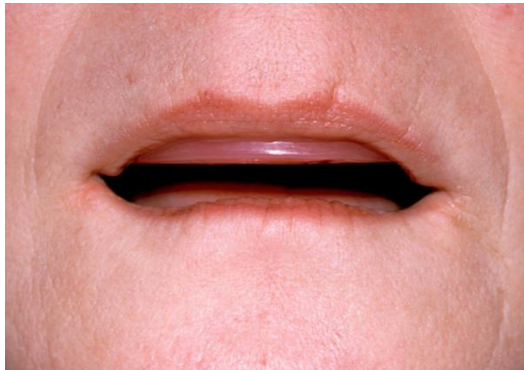2- Width.

a- The width from the tip of left canine to the tip of right canine is almost equal to the width of the nose (interalar width) when measured by the caliper. (Width of six anterior teeth = interalar width + 7 mm).

b- The width of maxillary central incisor equals approximately to 1/16 of bizygomatic width, and the width of maxillary anterior teeth equals to 1/3.36 of bizygomatic width.

c- Width of the anterior teeth can be measured on maxillary occlusal rim depending on the intraoral anatomical landmarks like: (buccal frenum, corner of the mouth, and canine eminence).

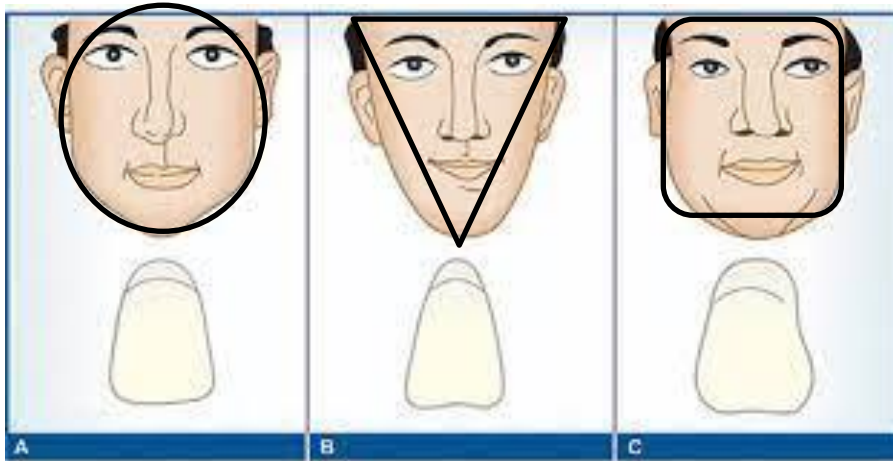
3- Patient preference: Use the method of pair comparison to assist a patient to decide what size of tooth they prefer. Set two different sizes of teeth on a piece of wax rope, place them under the upper lip, and find out which one the patient prefers. Two or three presentations may have to reach a suitable decision.



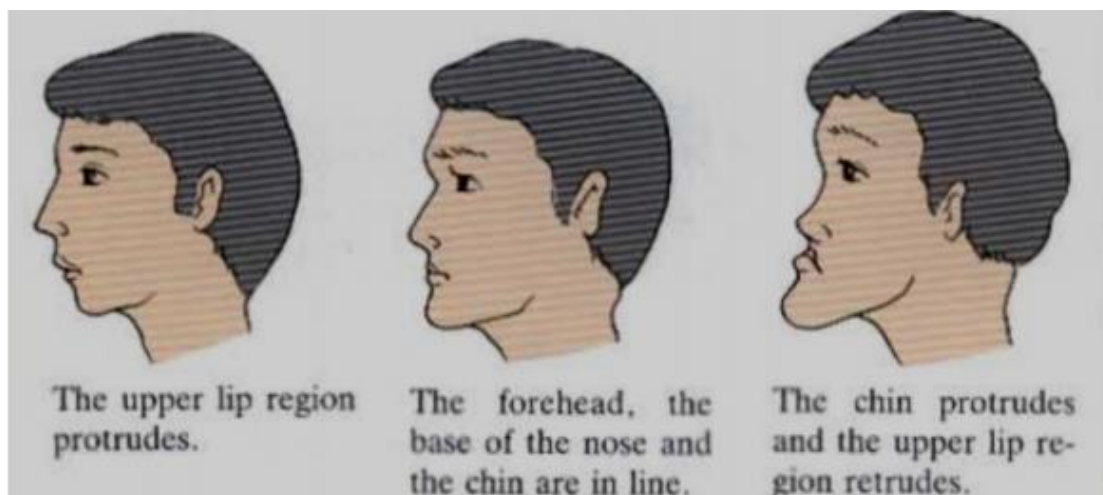
3. Form. The outline of the teeth depends on the following factors:

1- Facial form.

A. Frontal out line: The face could be classified into: square, ovoid, and tapering. The maxillary central incisor form should be in harmony with patient face.



B. Profile view: The face could be classified into: straight, convex, and concave. The labial surface of maxillary central incisor viewed from mesial aspect should be in harmony with profile of face.



2- Gender:

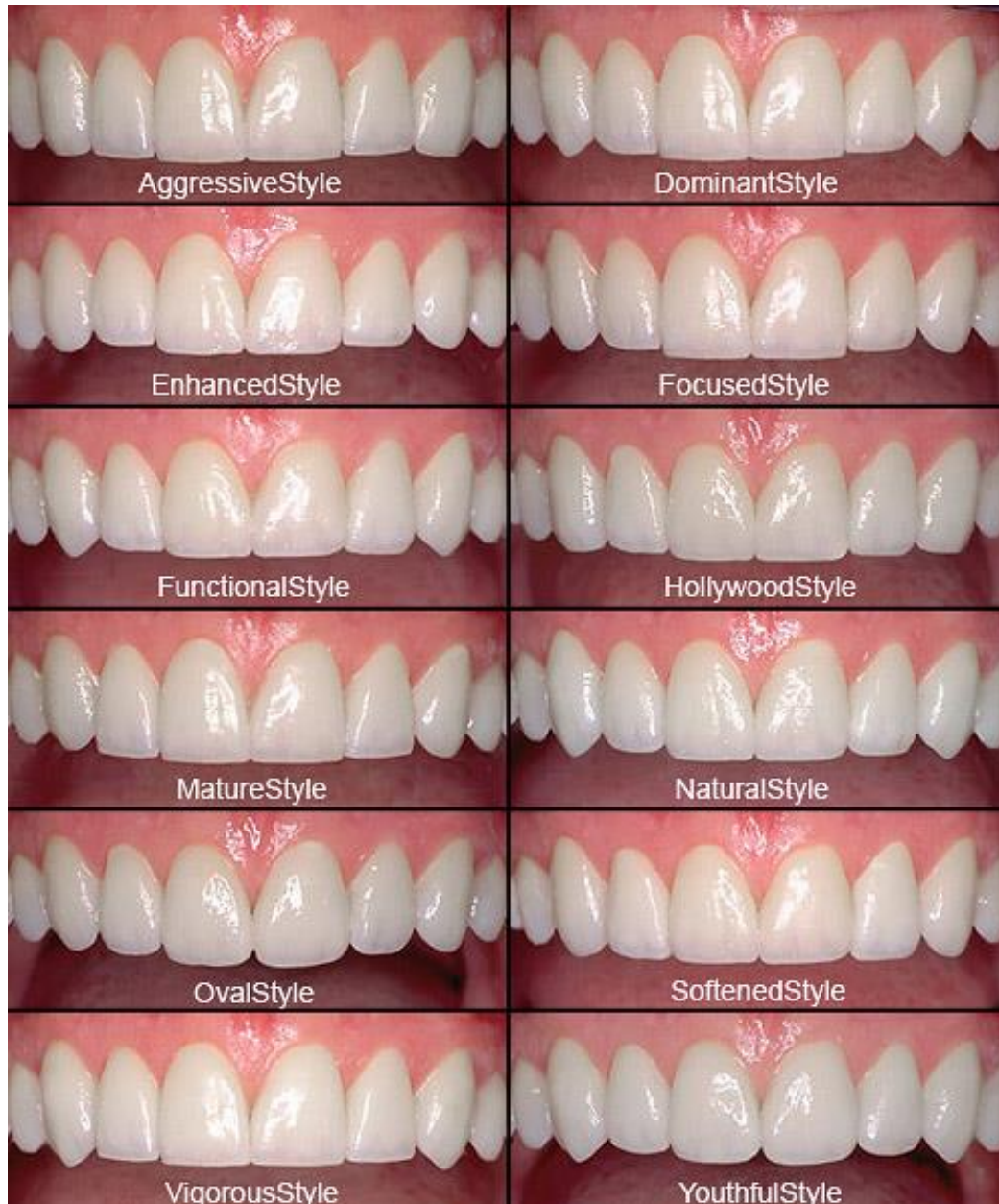a. Masculine form: is square, cuboidal, and angular form.

b. Feminine form: is more rounded, ovoid, and tapering features.

3- Age: In old patients the teeth tend to have square form due to attrition, more round features disappear and line angle quite seen in those patients.

4- Personality: It seems reasonable that a large vigorous type of persons have teeth of more square, large teeth with prominent markings, different from those of delicate appearing persons.

5- Patient preference: Allow the patient to select between the same size teeth but different forms. Set two different forms of teeth on the right and left sides of a piece of wax rope, and ask the patients which they prefer.



Material of artificial teeth

There are two main types, **acrylic** and **porcelain** teeth.

	acrylic	porcelain
1-	They are made from acrylic resin.	We have vacuum fired and air fired, the vacuum fired is better because they are harder and have luster.
2-	They are not brittle, but poor abrasion resistance, so they might become worn down with consequent loss of vertical dimension.	They are brittle and thus susceptible to fracture, more resistance to abrasion.
3-	Esthetic very good, but cannot maintain luster for long time.	Excellent esthetic, does not stained, and maintain luster for long time.
4-	Chemical bonding with denture base	Mechanical bonding by pins or undercut holes.
5-	Easily ground and polished.	Difficult to grind and polish.
6-	Transmit less force to mucosa because they have greater resilience, so they cushion the underlying supporting tissue from occlusal load.	More forces transmit to the mucosa.
7-	There is no clicking during contact.	There is clicking during contact.
8-	Thermal expansion same as that of acrylic denture base.	Thermal expansion is much lower than acrylic causes stresses in acrylic denture base and crazing may appear around teeth.
9-	Preferred when there are natural opposing teeth or gold bridge or when there is insufficient interocclusal distance where insufficient place to accommodate the holes and pins to secure the mechanical anchorage of porcelain teeth, and grinding become necessary.	Preferred for young patient, because it look more vital, smooth, and difficult to abrade, and maintain luster for long time.

