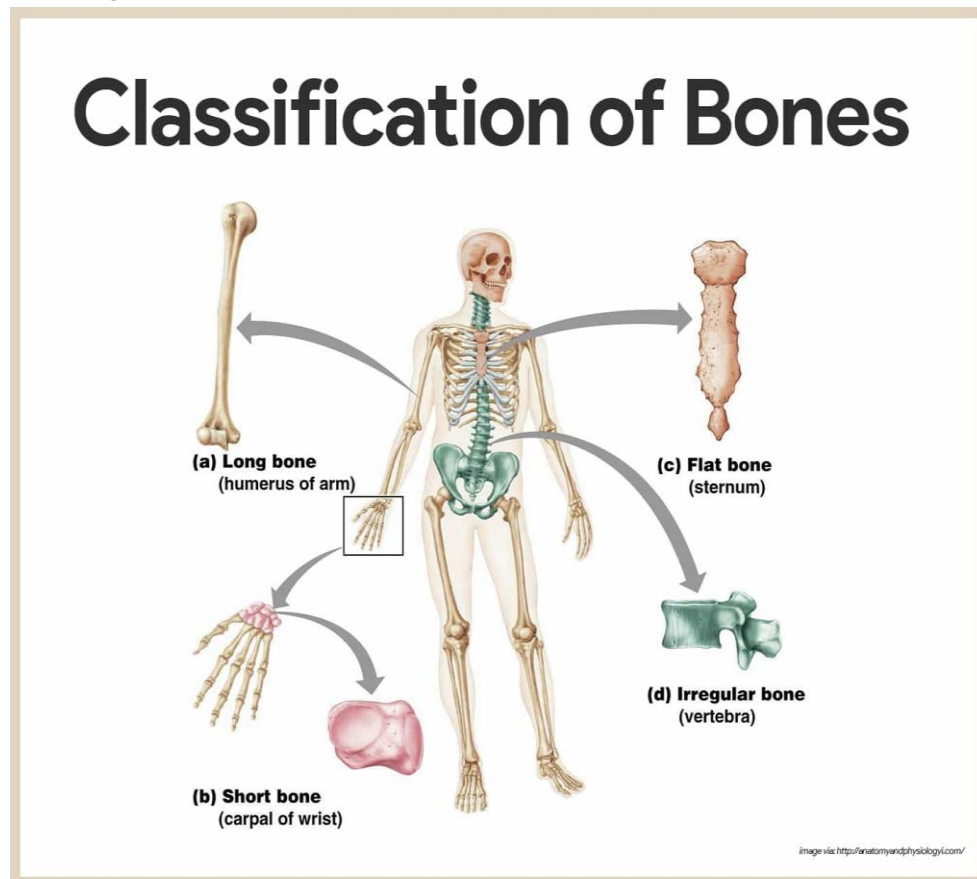


Lab-6-

Skeletal system

Parts of the skeletal system

- ✓ Bones
- ✓ Joints Bones
- ✓ **Classification of Bones :**
 - ✓ 1.long
 - ✓ 2.short
 - ✓ 3.flat
 - ✓ 4.irregular

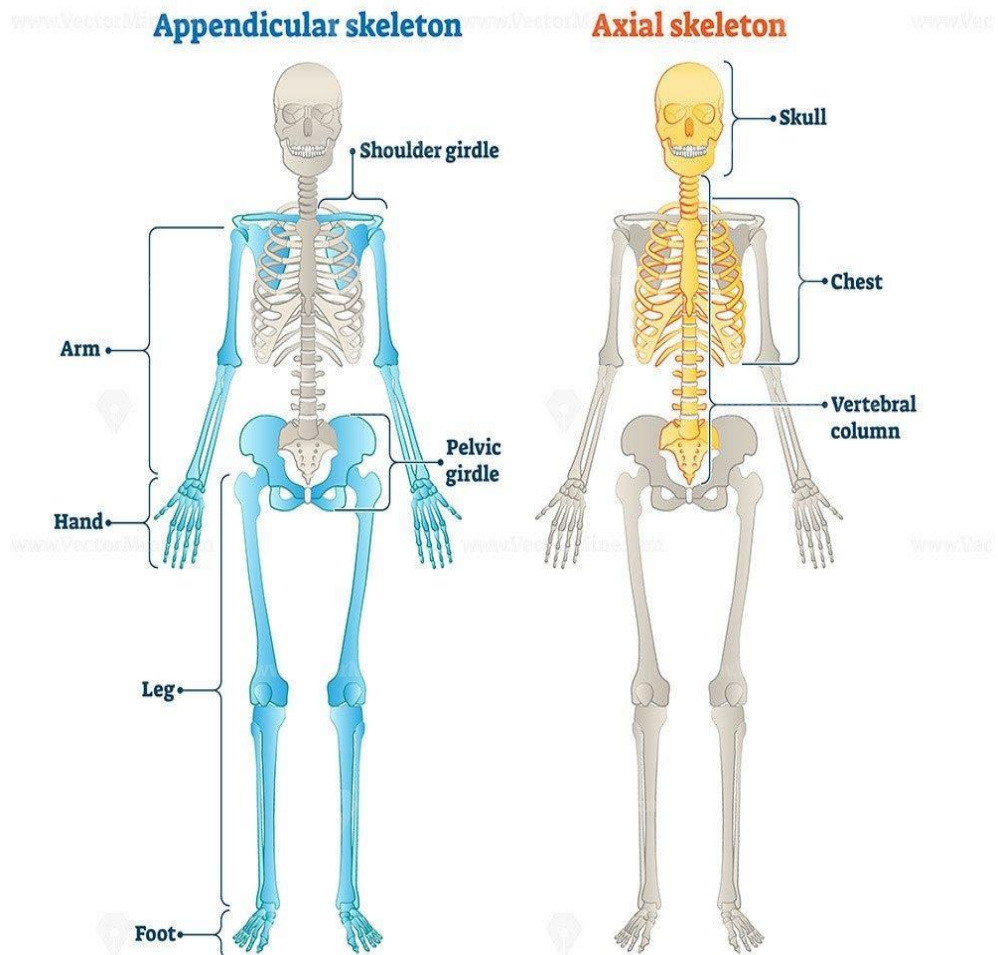


skeletal system Divided into two divisions

1. Axial skeleton

- Skull
- Vertebral column
- Thorax

DIVISIONS OF THE SKELETAL SYSTEM





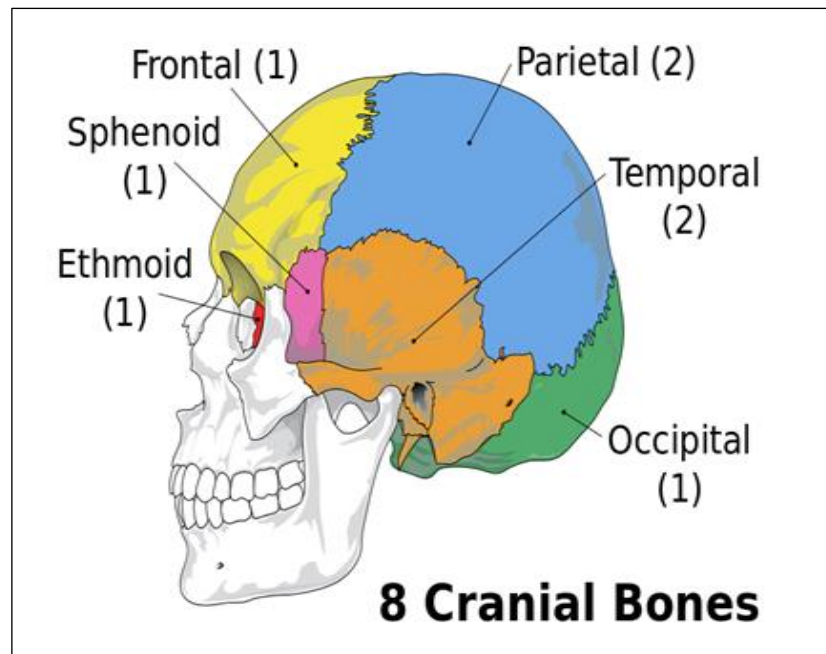
2. Appendicular skeleton

- Upper limbs
- lower limbs

Component of skull

1) The cranial bones:

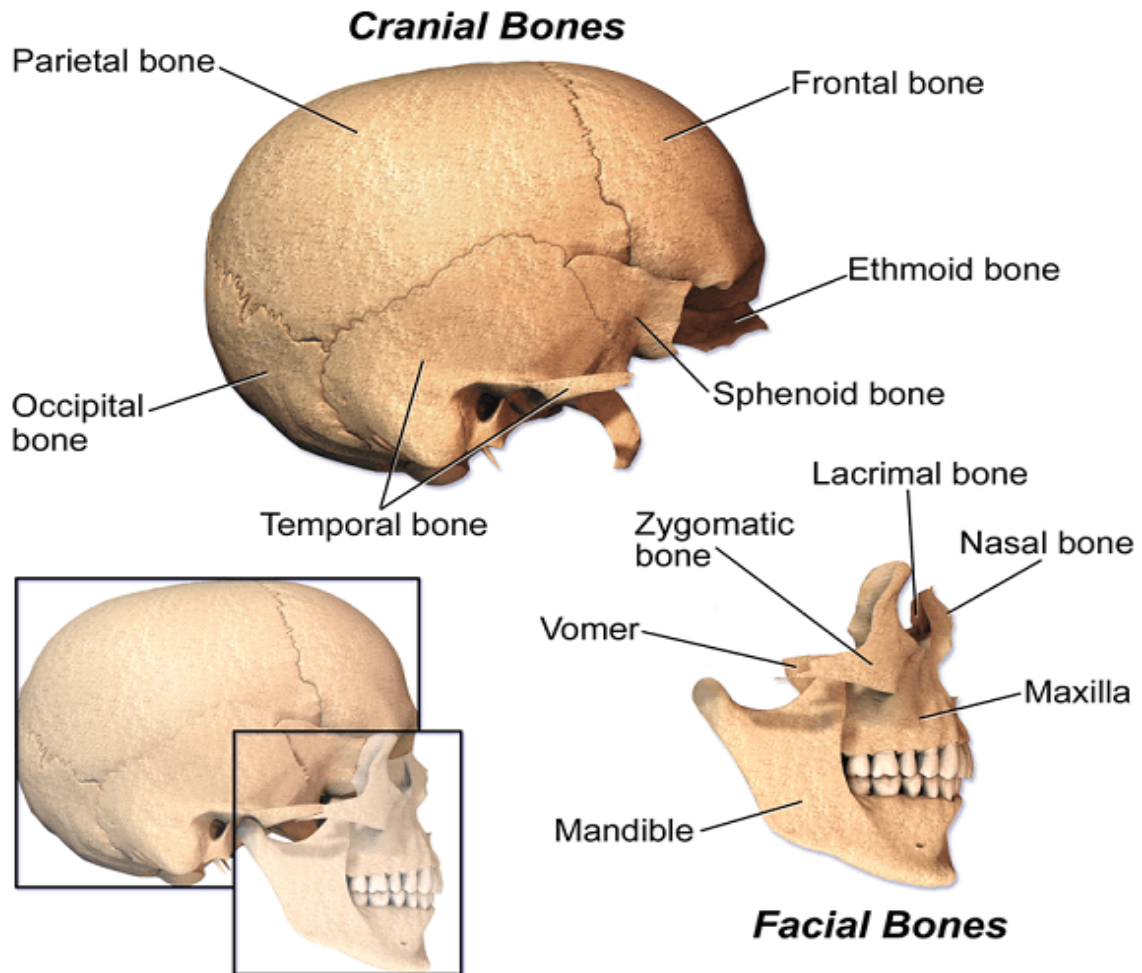
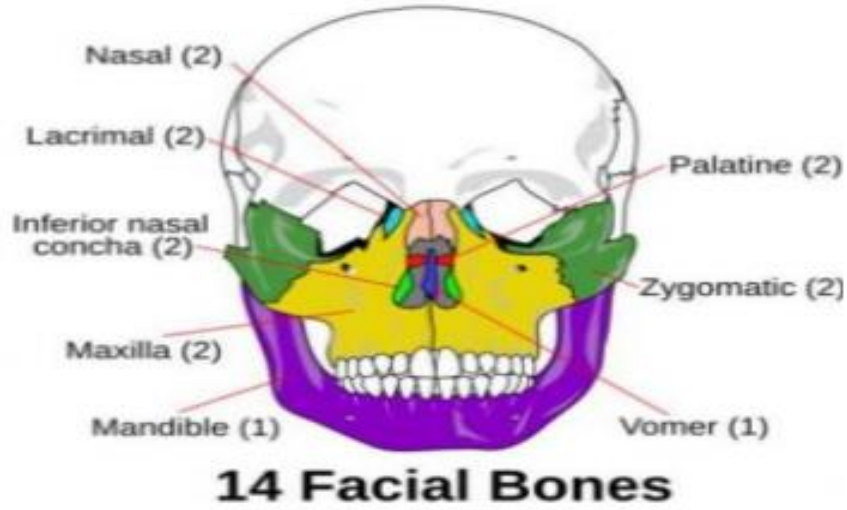
- ✓ Parietal (2)
- ✓ Temporal (2)
- ✓ Frontal (1)
- ✓ Occipital (1)
- ✓ Ethmoid (1)
- ✓ Sphenoid (1)



2) Facial bones:

In the human skull, the facial skeleton consists of fourteen bones in the face:

- Inferior turbinal (2)
- Lacrimal bones (2)
- Mandible (1).
- Maxilla (2)
- Nasal bones (2)
- Palatine bones (2)
- Vomer (1).
- Zygomatic bones (2)





The Vertebral Column

- **Vertebral Column divided in to :**

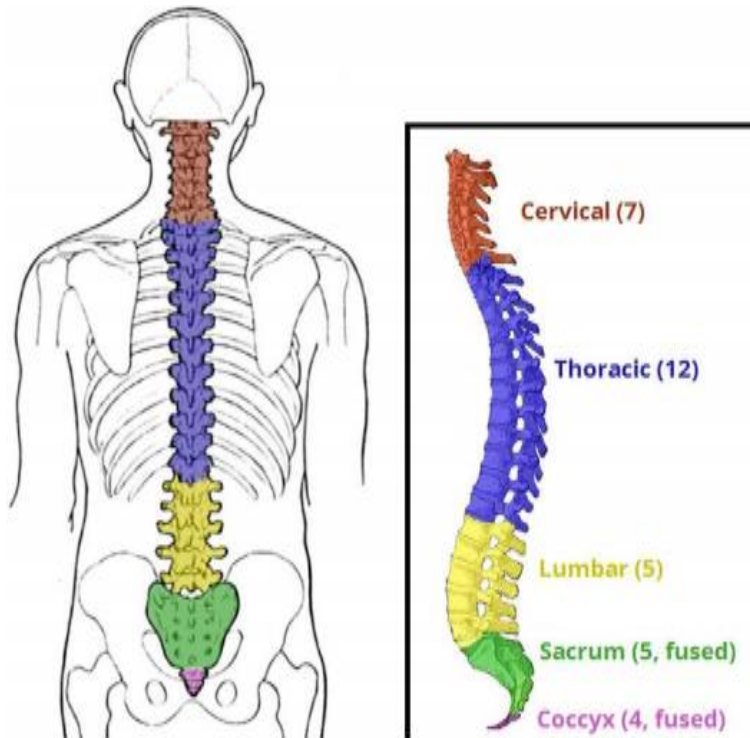
7 cervical

12 thoracic

5 lumbar

1 sacrum (5 fused)

1 coccyx (4 fused)



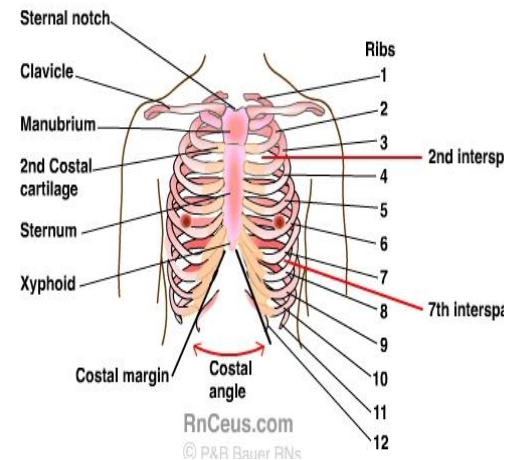


Thorax

The thorax is the superior part of the trunk located between the neck and abdomen.

The thoracic cavity consist of :

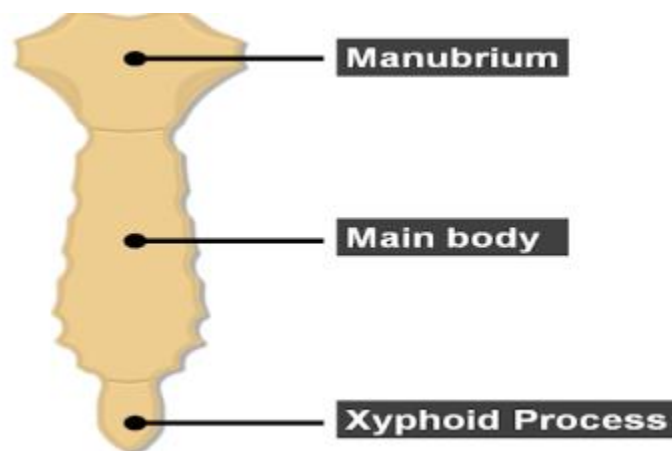
1. sternum
2. twelve pairs of ribs
3. twelve thoracic vertebrae



Sternum

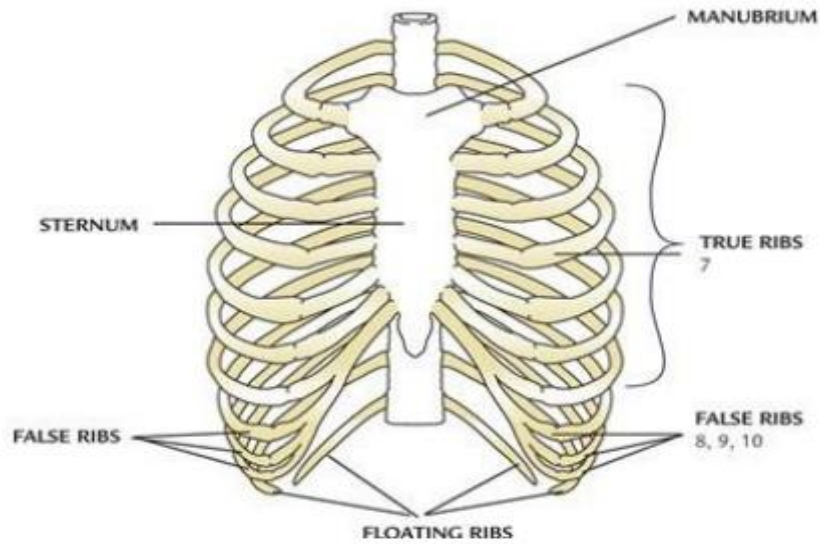
It consists of three parts:

1. **The manubrium sternum:** upper part of the sternum
2. **The body of the sternum:** is the middle and large part
3. **The xiphoid process:** the lower smallest part of the sternum.



twelve pairs of ribs

- True ribs (first seven pairs)
- false ribs (Three pairs)
- Two pairs of floating ribs



مهما أوتيت علماً وفهماً وفقهاً ودراية ورواية، "

إن لم تكن مصحوبة بحسن الخلق، وحسن الاسلوب والجود بالعتاء ،

فلن يتعدى علمك عتبة بابك...

خُلقت عظيمًا وإن خذلتك ظروفك، إن وجدت أنك في غير مكانك، لا تنسَ الحكمة من وجودك، **"

تظنُّ أنك هُزمت ولا تعلمُ أن الله يجعلُ أعظمَ انتصارِك في وقتٍ ومكانٍ لم يخطر ببالِك..

**د. زهراء ماجد