



Department of Anesthesia Techniques
Title of the lecture:- Histology



Younis.Abdulridha@mustaqbal-college.edu.iq
Ataa_khalil@mustaqbal-college.edu.iq

Lec4: Histology

Is the study of the tissues of the body and how these tissues are arranged to constitute organs.

Tissues are aggregates or groups of cells organized to perform one or more specific functions

Tissues are made of two interacting components: **cells** and **extracellular matrix (ECM)**.

The ECM consists of many kinds of molecules, most of which form complex structures, such as collagen fibrils and basement membranes.

The functions of ECM

- a- Supports for the cells
- b- Transporting nutrients to the cells
- c- Carrying away their wastes and secretory products.

The human body consists of Four basic types of tissue:

- 1- Epithelial tissue
- 2- connective tissue
- 3- Muscular tissue
- 4- Nervous tissue

Epithelial tissues are thin tissues that covers a body surface or lines a body cavity. They form the external skin, the inner lining of the mouth, digestive tract, secretory glands, the lining of hollow parts of every organ such as the heart, lungs, eyes, ears, the urogenital tract, as well as the ventricular system of the brain and central canals of the spinal cord.



Department of Anesthesia Techniques
Title of the lecture:- **Histology**



Younis.Abdulridha@mustaqbal-college.edu.iq
Ataa_khalil@mustaqbal-college.edu.iq

Functions of epithelial tissue :

- 1- covering ,lining and Protection surface (skin)
- 2-Absorption (tall columnar epithelium of intestine)
- 3- Secretion (epithelia of glands)
- 4- sensation (sensory cells- taste buds)
- 5- contractility (often associated with glands such as sweat and mammary glands)

Epithelial tissues consist of two types:-

- A- Covering or lining epithelial tissues
- B- Glandular epithelial tissues

Classify Covering epithelial tissues covers the outer layers or lining of the organs, ---

- according to the number of cells layers classified to:-

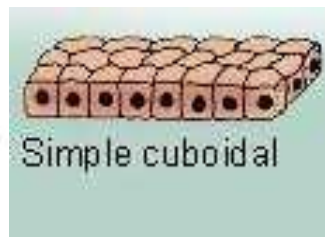
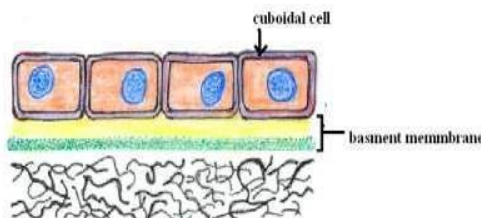
- 1-Simple epithelial tissue
- 2-Stratified epithelial tissue

Simple epithelial tissue :-composed of only one layer based on basement membrane

1- Simple cuboidal epithelial tissue:-

Location: secretory ducts of small glands, kidney tubules

Function: allows secretion and absorption





Department of Anesthesia Techniques
Title of the lecture:- **Histology**



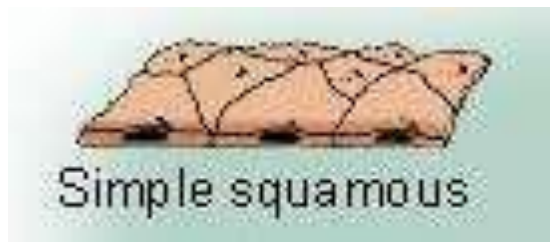
Younis.Abdulridha@mustaqbal-college.edu.iq
Ataa_khalil@mustaqbal-college.edu.iq

2- Simple squamous epithelial tissue:-

Location: blood and lymphatic vessels being called **endothelium**

Lining the abdominal and plural cavities called **mesothelium.**

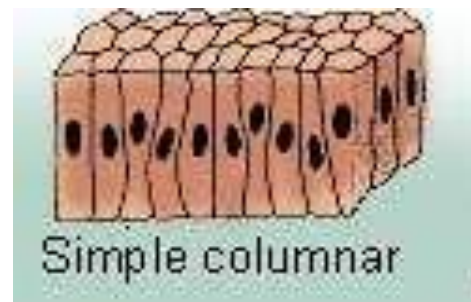
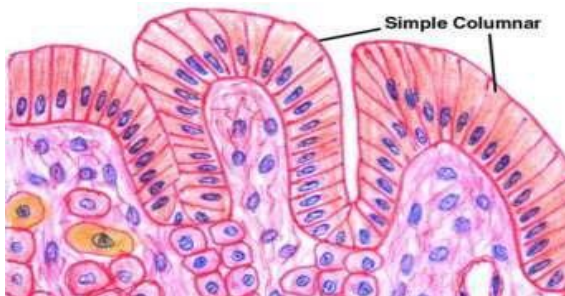
Function: secretes lubricating substance, allows diffusion and filtration



3- Simple columnar epithelial tissue :-

Location: bronchi, uterine tubes, uterus called **ciliated columnar** ;
and cover digestive tract - called **non ciliated columnar epithelium**

Function: allows absorption, secretes mucous and enzymes



4- Pseudostratified columnar epithelial tissue:- are tissues formed by a single layer of cells that give the appearance of being made from multiple layers, especially when seen in cross section. Several layers of nuclei suggest several layers of cells but in fact all cells are in contact with underlining extracellular matrix and show several layer of nuclei , composed of four types of cell.

Location: trachea and most of the upper respiratory tract (ciliated cells)

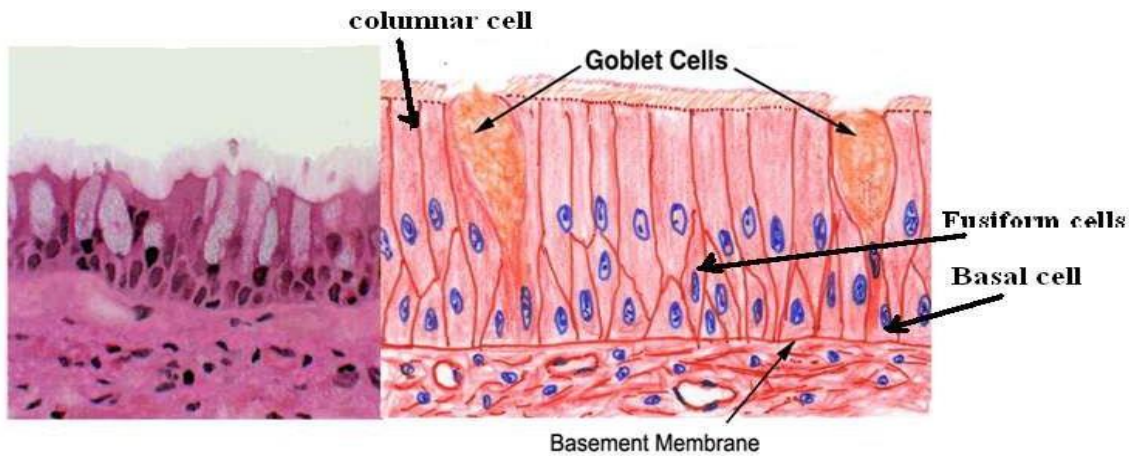


Department of Anesthesia Techniques
Title of the lecture:- Histology



Younis.Abdulridha@mustaqbal-college.edu.iq
Ataa_khalil@mustaqbal-college.edu.iq

Function: secretes mucus which is moved with cilia

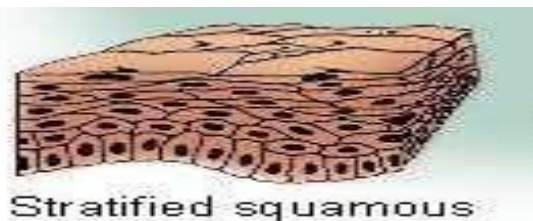


Stratified epithelial tissue :- Composed of more than one layer based on basement membrane. classified to :-

1-Stratified squamous epithelial tissue

There are two types of stratified squamous epithelial tissue:

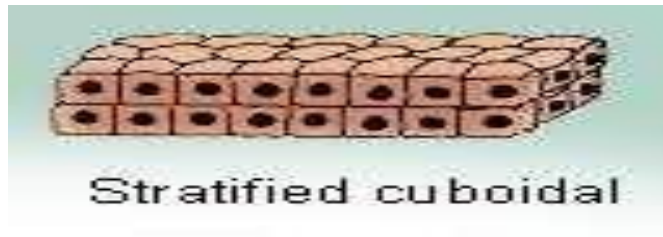- **Non keratinized squamous epithelial tissue** which is covering moist cavities such as mouth , esophagus , pharynx
- **Keratinized squamous epithelial tissue** found on exposed surface of the body such as the skin .





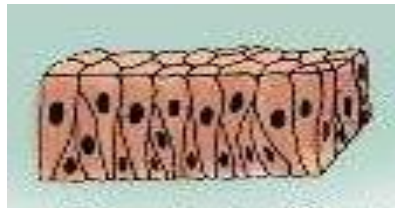
Msc. Ata'a Khalil
ataa_khalil@mustaqbal-college.edu.iq

2- Stratified cuboidal epithelial tissue :- found in the large excretory ducts in the salivary glands and pancreas .



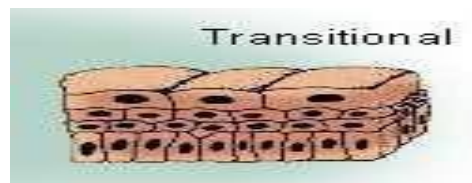
3- Stratified columnar epithelial tissue

Is found in the fornix of conjunctiva while the ciliated Stratified columnar epithelial tissue is found in the larynx .



4- Transitional epithelial tissue

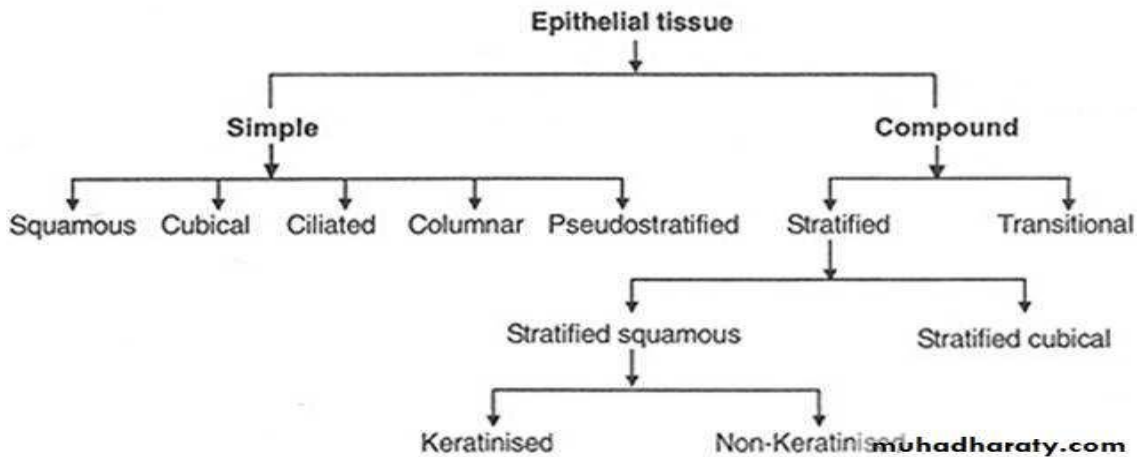
Is found exclusively in the passages of the urinary system .



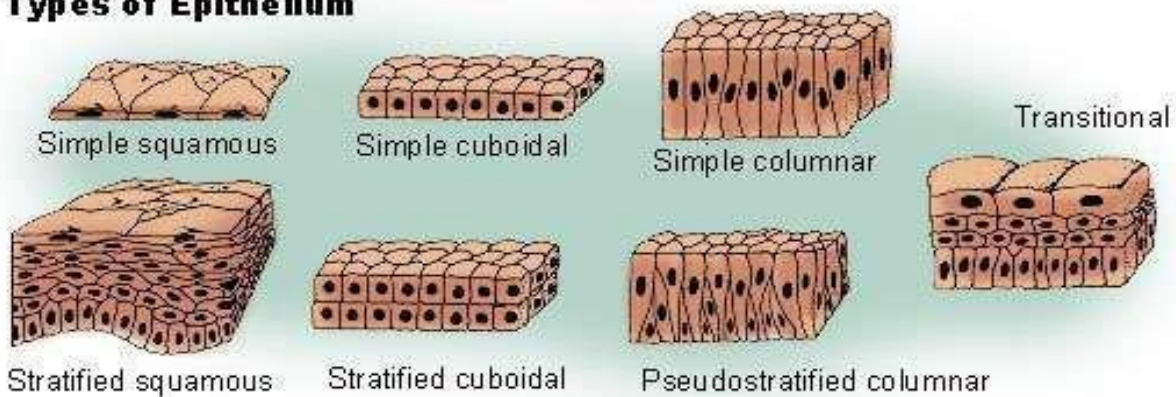


Msc. Ata'a Khalil
ataa_khalil@mustaqbal-college.edu.iq

Classification of Epithelial Tissues



Types of Epithelium



Glandular tissue :

Cells or parenchyma of the glands developed from epithelial tissue, according to the methods of secreted products of gland the glandular epithelial tissues classified to:

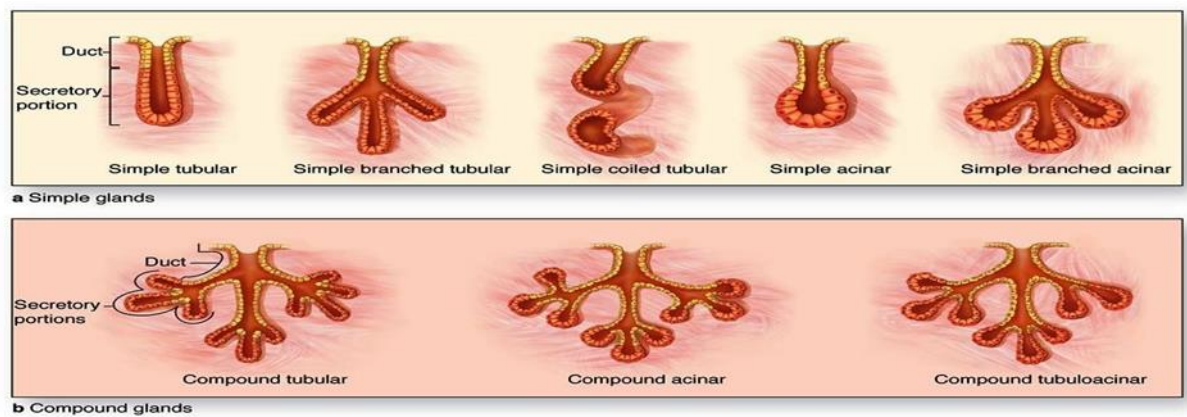
- A- **Exocrine glands**(excrete their product into ducts)like skin
- B- **Endocrine glands**(secrete their products direct into circulatory system)
- C- **Mixed glands** (like pancreas)



Msc. Ata'a Khalil
ataa_khalil@mustaqbal-college.edu.iq

A- Exocrine gland: have a secretory portion, which contains the cells, specialized for secretion and ducts, which transport the secretion out of the gland.

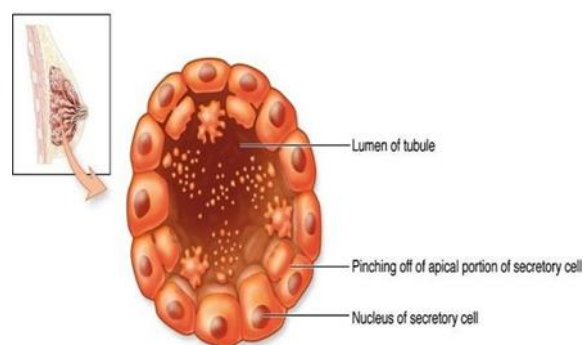
- **According to the structure of the ducts**
 - Simple (unbranched).
 - Compound (two or more branched).
- **According to the structure of secretory portion**
 - Tubular (either short or long and coiled)
 - Acinar (round or globular).



- **According to the way the secretory products leave the cell**

- **Apocrine:** the secretory products is typically a large lipid droplet and is discharged together with some of the apical cytoplasm.

Example: Mammary glands

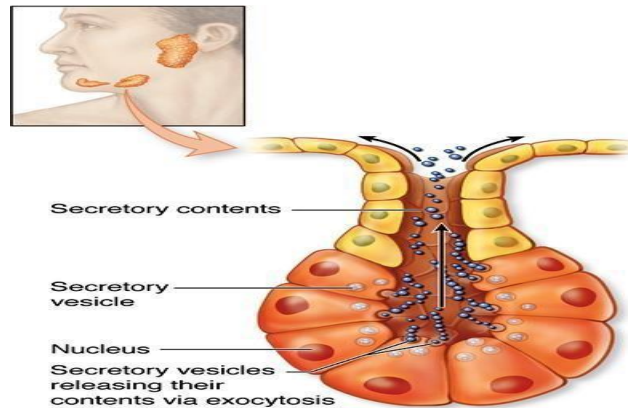




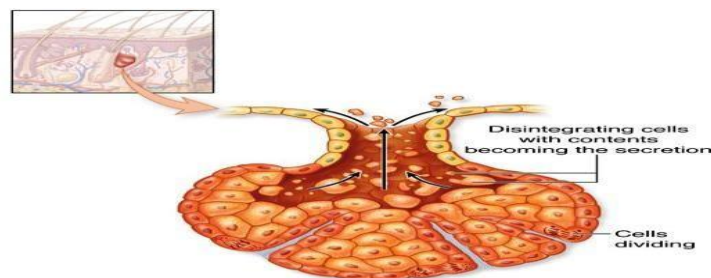
Msc. Ata'a Khalil

ataa_khalil@mustaqbal-college.edu.iq

- **Merocrine (Eccrine):** secrete product usually containing proteins by means of exocytosis at the apical end of the secretory cells Example; (e.g. salivary glands)



- **Holocrine:** the cell filling with secretory product and then the whole cell being disrupted and shed .Example: Sebaceous glands of skin.



B. Endocrine Glands

- Endocrine glands have not any ducts
- Their specific products – hormones are released directly into the bloodstream.
- The major endocrine glands include

Pituitary, Hypothalamus thyroid, Parathyroid, Adrenal, Pancreas, Ovary (females), Testis (males)