

Operative Dentistry

Management of Deep Seated Caries

INTRODUCTION

Dental pulp is a highly vascularized tissue of the tooth and has the potential to heal. It performs many functions throughout the life of tooth therefore; every effort should be made to maintain its integrity and vitality.

Vital Pulp Therapy for Teeth Diagnosed with a Normal Pulp or Reversible Pulpitis

I-Protective Base:

A protective base is a material placed on the pulpal surface of a cavity preparation, covering exposed dentin tubules, to act as a protective barrier between the restorative material or cement and the tooth's pulp. Placement of a liner and protective base such as calcium hydroxide and glass ionomer cement is at the dentist's discretion.

Indications: In a tooth with a normal pulp, when dentin is exposed and all caries is removed during the preparation for a restoration, a protective radiopaque base may be placed between the permanent restoration and the dentin to minimize pulp injury, promote pulp tissue healing, or minimize postoperative sensitivity.

Objectives: A protective base is utilized to preserve the tooth's vitality, promote pulp tissue healing and tertiary dentin formation, and minimize microleakage. Adverse post-treatment signs or symptoms such as sensitivity, pain, or swelling should not occur

II- Indirect Pulp Capping

Sir John Tomes stated in 1859 that: it is better that a layer of discolored dentine be allowed to remain for the protection of the pulp rather than run the risk of sacrificing the tooth. He had observed that discolored and demineralized dentin could be left

behind in deep cavities of the tooth before restoration, often with highly satisfactory results. This is especially applicable if micro-exposures of the pulp are suspected. The removal of this dentine may lead to exposure of the pulp, thus impairing its prognosis. It has been shown that demineralized dentin, if it is free of bacteria, will demineralize once the source of the infection has been eliminated. The diagnosis of the presence of demineralized dentin that is caries-free can be assisted by using a caries disclosing solution. The placement of a suitable material directly on this demineralized dentin is commonly called indirect pulp capping (IPC).

IPC has been defined as the steps undertaken to protect a vital tooth where removal of all affected tissues would result in a pulpal exposure.

In this context a non-exposed pulp is one that exhibits no signs of hemorrhage at or near the pulp chamber. When carrying out such a procedure it is vitally important that the infection is removed and is not allowed to recur.

Material used for IPC

- 1) This can be achieved with the placement of an antibacterial liner such as calcium hydroxide or zinc oxide–eugenol cement, which is aimed at stimulating secondary dentin formation.
- 2) With the advent of adhesive dental materials, another possible restorative option is the placement of calcium hydroxide cement followed by an adhesive liner such as glass–ionomer or resin modified glass–ionomer cement. The aim is to provide a combination of an antibacterial barrier and an adhesive seal against the further ingress of bacteria.

Indication of IPC:

- 1) When there is a radiographically evident deep carious lesion encroaching on the pulp.
- 2) Tooth has no history of spontaneous pain.
- 3) Tooth responds normally to vitality test.

Procedure (IPC):

1. Field must be isolated with rubber dam isolation to minimize bacterial contamination of the treatment site.
2. All peripheral carious dentin is removed with large round bur or spoon excavator.
3. Area adjacent to the pulp is debrided off only the soft carious dentin.
4. CaOH₂ and ZOE — type liners Placed.
5. Base or adhesive cement applied over the lining for complete sealing
6. After 4 - 6 W (3 months) or more Cement removed.
7. Internal surface of the cavity inspected for remineralization and hard dentin (2nd dentin) formation.
8. Remove any residual soft dentin.
9. Permanent restoration applied.

III- Direct Pulp Capping

Direct pulp capping can be described as the dressing of an exposed pulp with the objective of maintaining pulp vitality.

Indications

Indications for pulp capping include

1. Teeth with recent (24 h) traumatic exposures or mechanical non-carious exposures during cavity preparation.
2. Pulp capping should be considered only for immature permanent teeth, or for mature permanent teeth with simple restorative needs.
3. Mature teeth with inflamed pulps, as with carious pulp exposures, should not be pulp capped.
4. Pre-operative tooth sensitivity frequently has been mentioned as a contraindication to Pulp capping.

Requirements for a successful vital pulp therapy

Vital pulp therapy has a high success rate if the following conditions are met:

- (1) The pulp is not inflamed;
- (2) Hemorrhage is properly controlled; Various methods have been proposed to achieve pulpal hemostasis, including mechanical pressure with a sterile dry cotton pellet, or with one soaked in saline, hydrogen peroxide, sodium hypochlorite, in concentrations of 2.5%, 3%, or 5.25%, is a biocompatible and effective solution for achieving hemostasis before pulp capping and the disinfectant chlorhexidine also has been described as an effective hemostatic for pulp capping
- (3) A non-toxic capping material is applied; traditionally, calcium hydroxide has been the most common direct pulp-capping agent. Calcium hydroxide is antibacterial and disinfects the superficial pulp.

A major disadvantage of calcium hydroxide materials

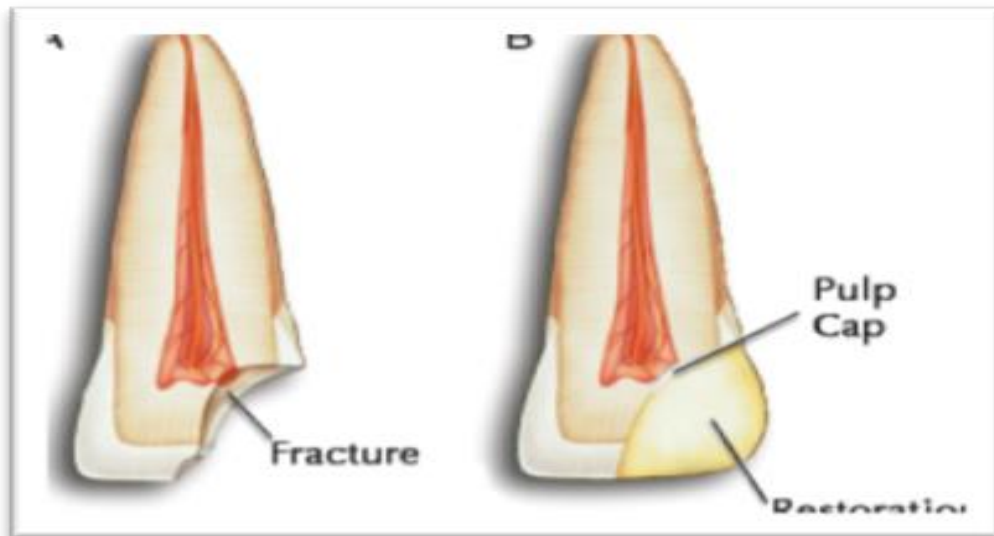
1. They do not seal the exposed pulp from the external environment. Therefore, an additional base material, such as a resin-modified glass ionomer, can be placed to help seal the pulp against bacterial ingress during the healing phase.
2. Dentin bridges beneath calcium hydroxide pulp caps contain 'tunnel defects' that leave the pulp open to recurring bacterial infection via microleakage
3. Calcium hydroxide materials tend to soften, disintegrate, and dissolve over time, leaving voids and other potential pathways for bacterial infiltration.

Therefore, various other materials, including zinc oxide eugenol, glass ionomers, resin adhesives, and mineral trioxide aggregate (MTA), have been proposed as capping agents for vital pulp therapy. MTA is an alkaline material that stimulates dentinal bridging and appears to have particular promise as a pulp-capping material.

- (4) The bacteria seal out base and restoration.

Technique

1. After adequate anesthesia has been obtained, place a rubber dam and disinfect the tooth with a chlorhexidine solution and gently rinse with anesthetic or sterile saline. If any hemorrhage occurs, dab with a sterile cotton pellet until hemorrhage ceases. As noted previously, a sodium hypochlorite or chlorhexidine solution may be used to aid in hemostasis.



2. Mix pure calcium hydroxide with sterile water, saline, or anesthetic solution, and apply directly to the exposure site. A hard-setting calcium hydroxide liner also can be used, and is preferable if the pulp is small.
3. Next, apply and light-cure a resin modified glass ionomer base/liner material such as to protect the calcium hydroxide dressing and to provide a better seal.
4. Finally, use a good temporary and wait for 4 to 6 weeks for final restoration.

Recall

The tooth should be evaluated using electrical pulp testing (EPT), thermal testing, and palpation and percussion tests at 3–4 weeks, 3 months, 6 months, 12 months, and every year thereafter. Periodic radiographs are needed to detect the presence of periapical radiolucency, and for immature teeth, continued development of the root. Hard tissue barriers sometimes can be seen at the treated exposure site as early as 6 weeks after treatment.

Prognosis

The success of the pulp-capping procedure relies on the ability of calcium hydroxide to disinfect the superficial pulp and dentin and to necrosis the superficial inflamed pulp. The quality of the bacteria-tight seal provided by the base, bonding system, and restoration is also of critical importance. The reported prognosis for direct pulp capping is in the range of 80% when performed under ideal conditions, that is, on an uninfamed pulp and with a good coronal seal.

IV- Partial pulpotomy

The phrase 'partial pulpotomy' or 'Cvek pulpotomy' describes removal of inflamed pulp tissue to the level of healthy coronal pulp. A sterile diamond rotating at high speed under copious water spray is used to surgically excise inflamed pulp tissue. The excision is considered complete when the pulp stump no longer bleeds excessively. The rationale for the Cvek pulpotomy is this: if the inflamed tissue is removed, the healthy underlying tissue is more likely to remain healthy and to seal the exposure with hard tissue bridging of the exposure site. Of course, the other requirements for successful pulp capping, such as hemostasis and a bacteria-tight seal, are met. Pulpotomies have been used routinely in treatment of primary and young permanent teeth after traumatic pulp exposures, but their use in mature permanent teeth is a relatively new concept, and is considered unproven for carious exposures.

Indications

Indications for a partial pulpotomy are similar to those for direct pulp capping. As with simple direct pulp capping, an immature permanent tooth or a mature permanent tooth with uncomplicated restorative needs is preferable. The partial pulpotomy should be selected as an alternative to direct pulp capping when the extent of pulpal inflammation is expected to be greater than normal.

Technique

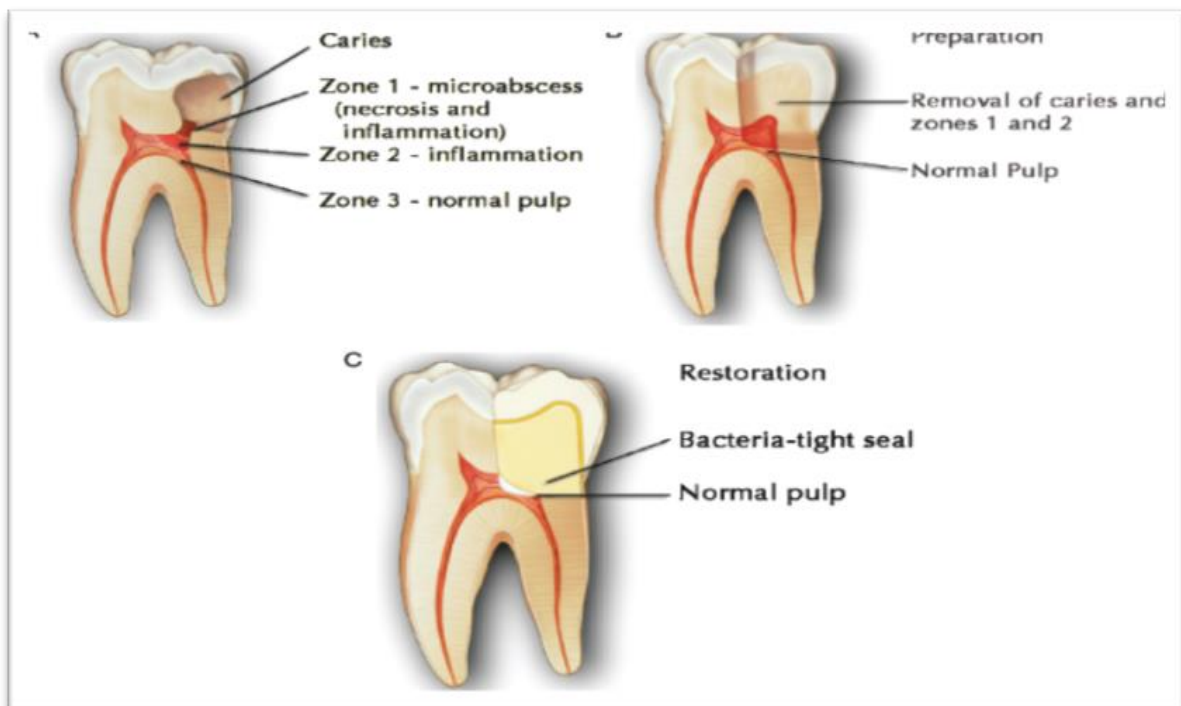
Accomplish anesthesia, isolation, and surface disinfections described in the section on direct pulp capping.

At the exposure site, remove 1–2mm of the superficial pulp tissue using a sharp, sterile diamond rotary instrument. The diamond should be running at very high speed with copious water spray.

If excessive bleeding continues, extend the preparation apically. Remove any excess blood by rinsing with sterile saline or anesthetic solution and dry with a sterile cotton pellet.

As described previously, sodium hypochlorite or chlorhexidine can be used to facilitate hemostasis. Take care to avoid formation of a blood clot, which compromises the prognosis.

If the pulp is large enough to allow an additional 1– 2mm loss of tissue through necrosis, mix and apply a thin layer of pure calcium hydroxide. If the pulp is not large enough to accommodate any further loss of tissue, mix and apply a hard-setting calcium hydroxide liner such as Dycal.



As in teeth with conventional direct pulp caps, place an appropriate resin-modified glass-ionomer liner or base, a dentin/ enamel adhesive and restorative material.

Recall

Schedule follow-up examinations, using the time intervals and procedures described for pulp capping.

Prognosis

The partial pulpotomy offers several advantages over direct pulp capping.

- a) Superficial inflamed pulp tissue is removed during preparation of the pulpal cavity.
- b) Calcium hydroxide disinfects the pulp and dentin and removes additional inflamed pulp tissue.
- c) In addition, the pulpotomy provides space for the materials required to provide the requisite bacteria-tight seal.

The prognosis for success of partial pulpotomies is in the range of 95%. However, this success rate is for traumatized teeth where the level of pulpal inflammation is very predictable. The success rate for treatment of carious exposures is unknown currently.

V- Full pulpotomy

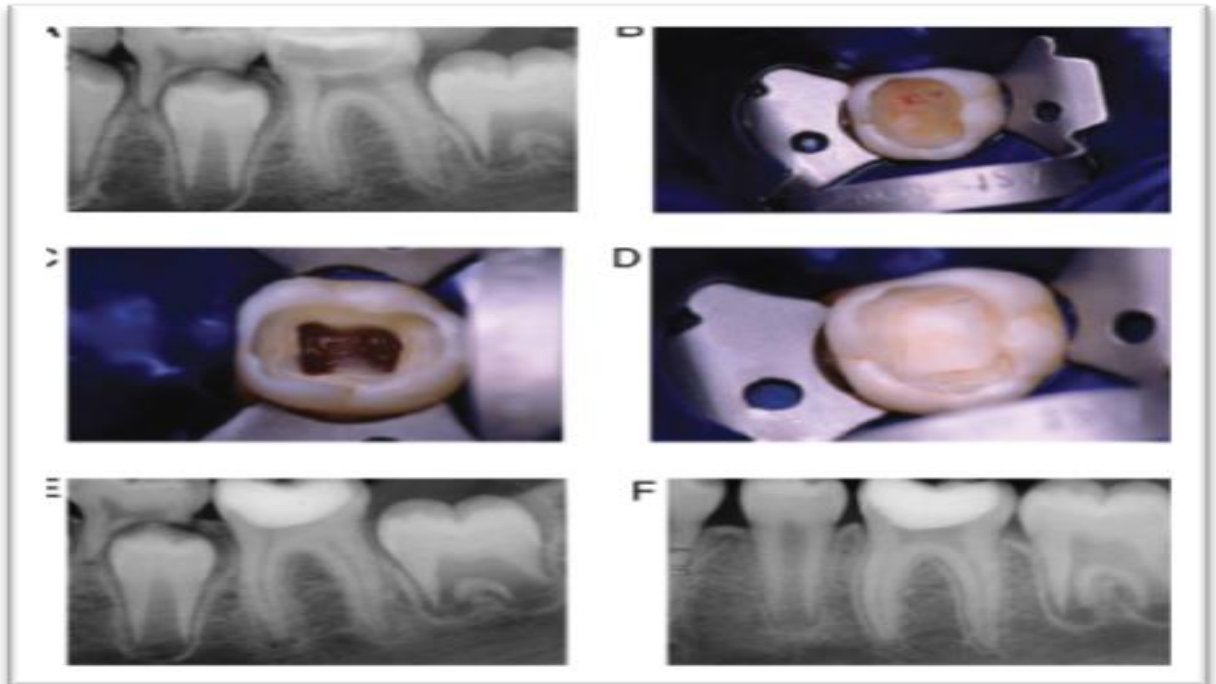
A 'full pulpotomy' involves removal of the entire coronal pulp to the level of the root canal orifice(s).

Indications

The indications for a full pulpotomy are similar to those for a partial pulpotomy, except that the pulp in question is likely to have more extensive inflammation, if the coronal pulp is rather small in size.

Technique

- a) The technique for a full pulpotomy is similar to that of the partial pulpotomy, except that the entire mass of coronal pulp tissue is removed, normally to the canal orifices, but as much as 2–3mm apical to the orifices.
- b) The tissue is capped with calcium hydroxide in a manner similar to partial pulpotomy.



Recall

Recall evaluations are performed at the same intervals recommended for a tooth treated with a direct pulp cap or partial pulpotomy.