

Al-Mustaqbal university college

Practical anatomy

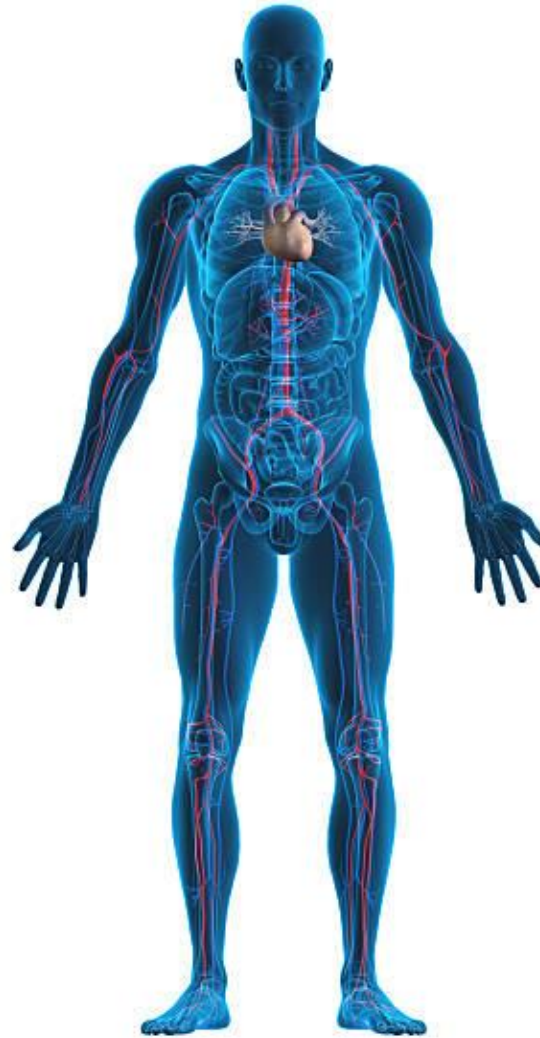lab.1:

Terms and surface anatomy

Assist lecturer

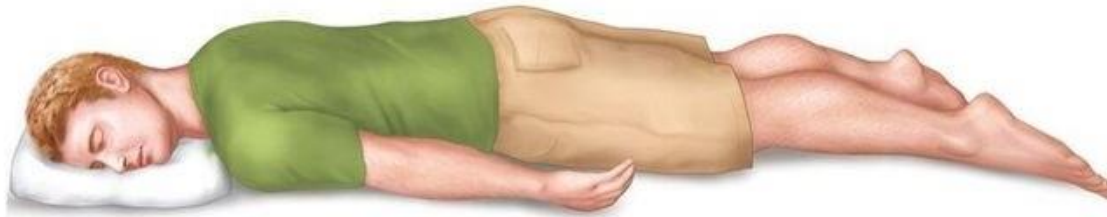Mahdi Al-Anawy

Anatomical position

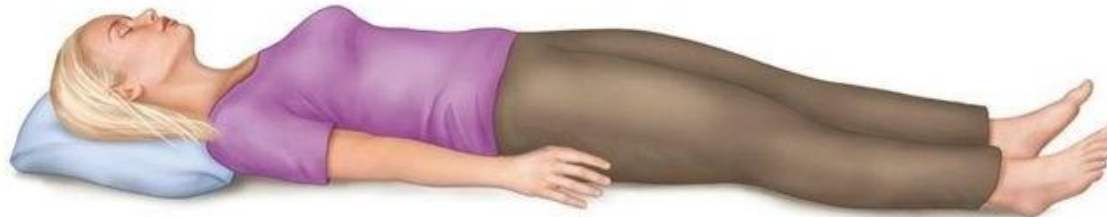

Supine and prone positions

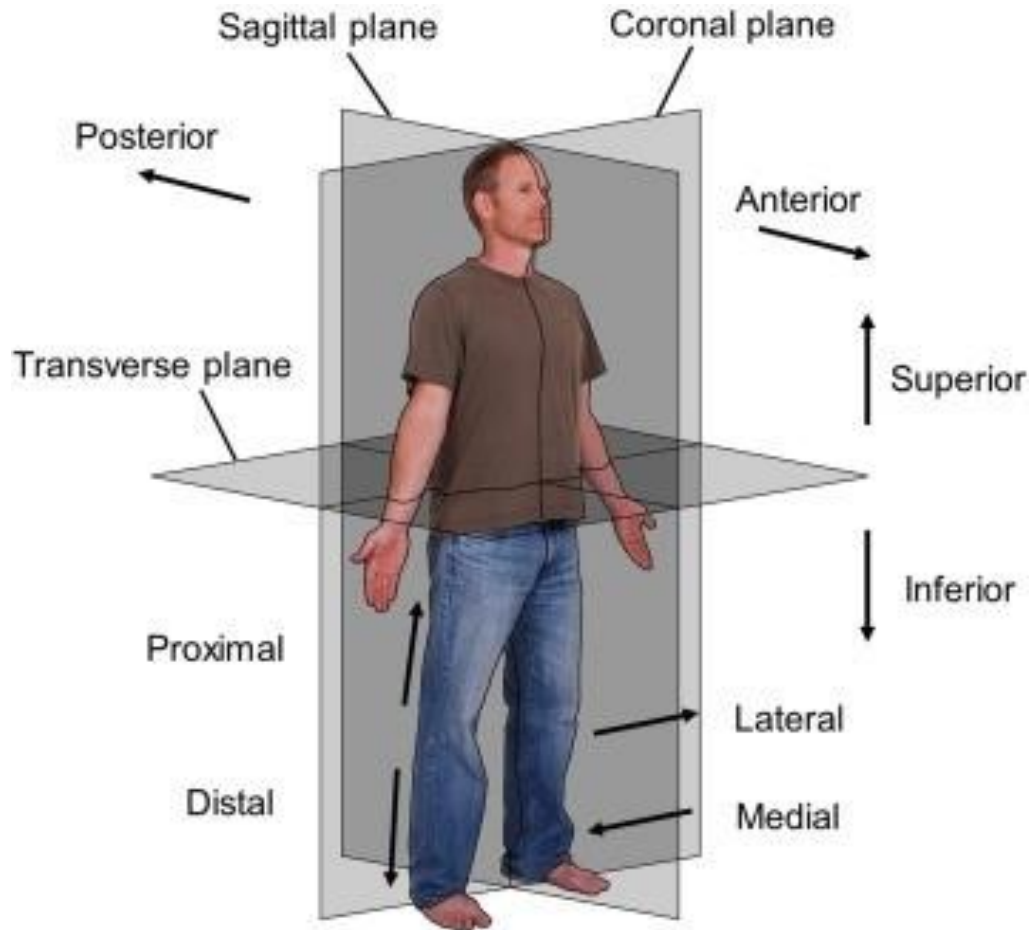
Prone



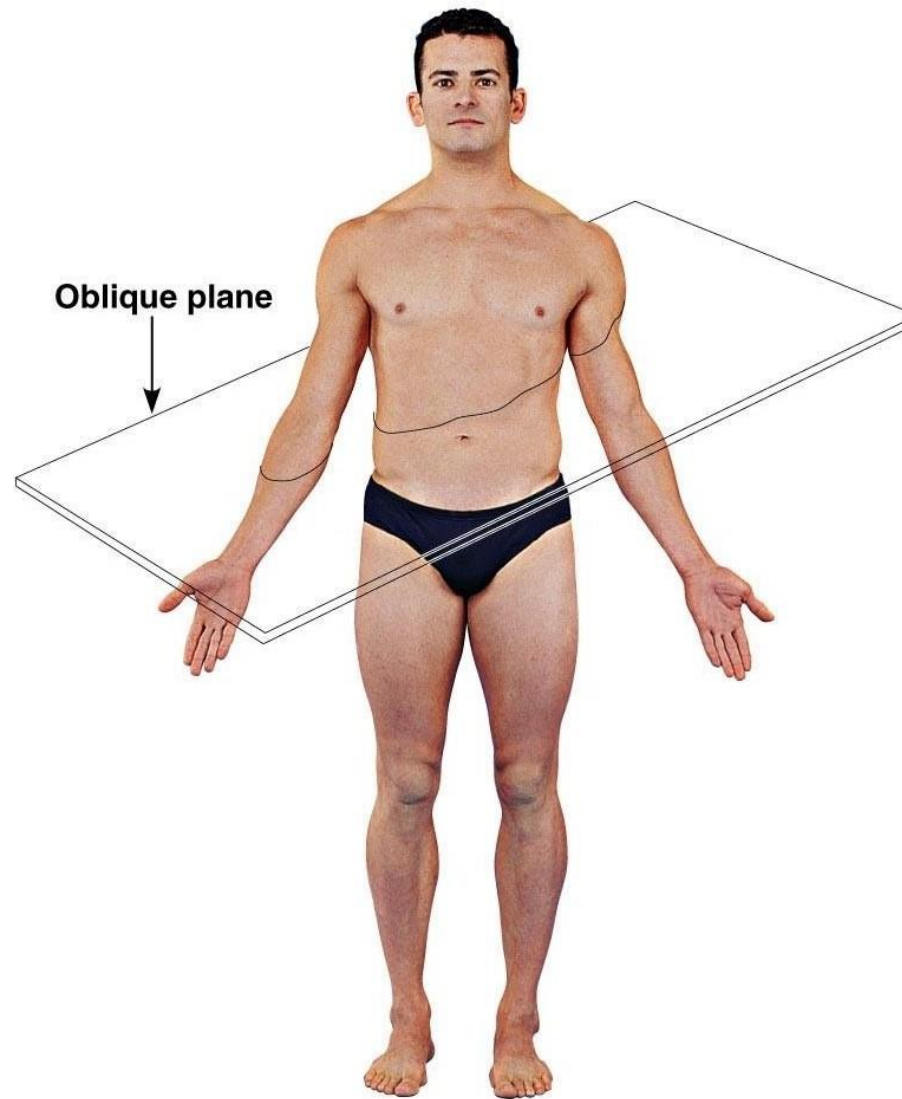
Supine



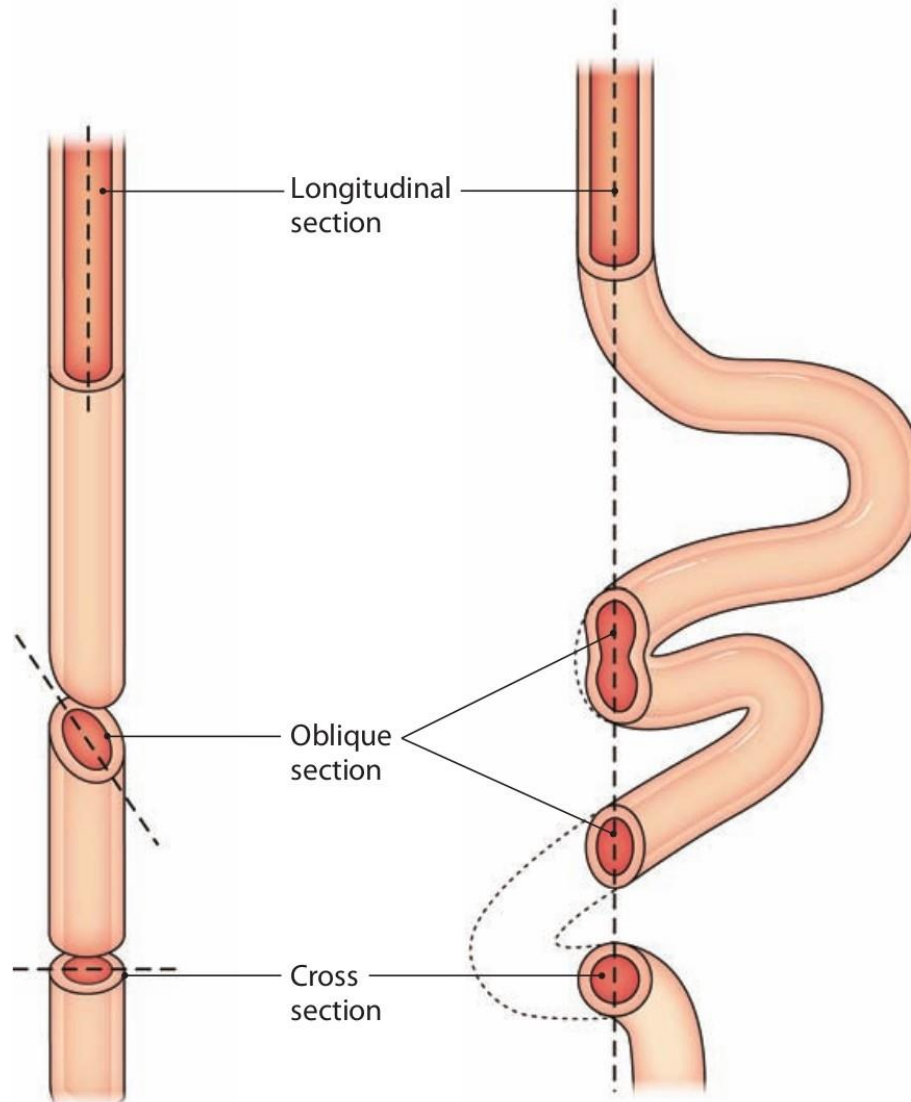
Body planes and terminology



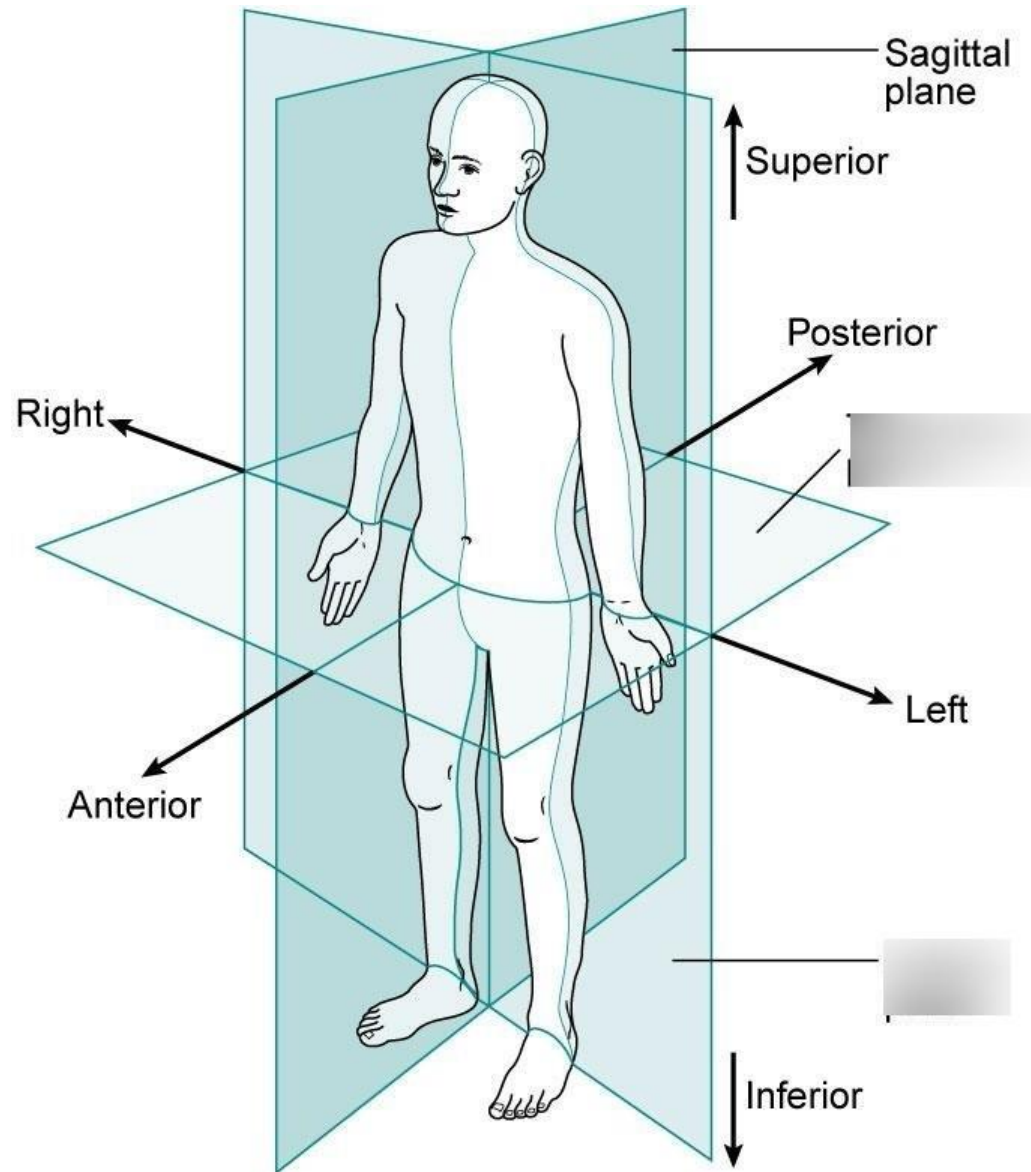
Other planes



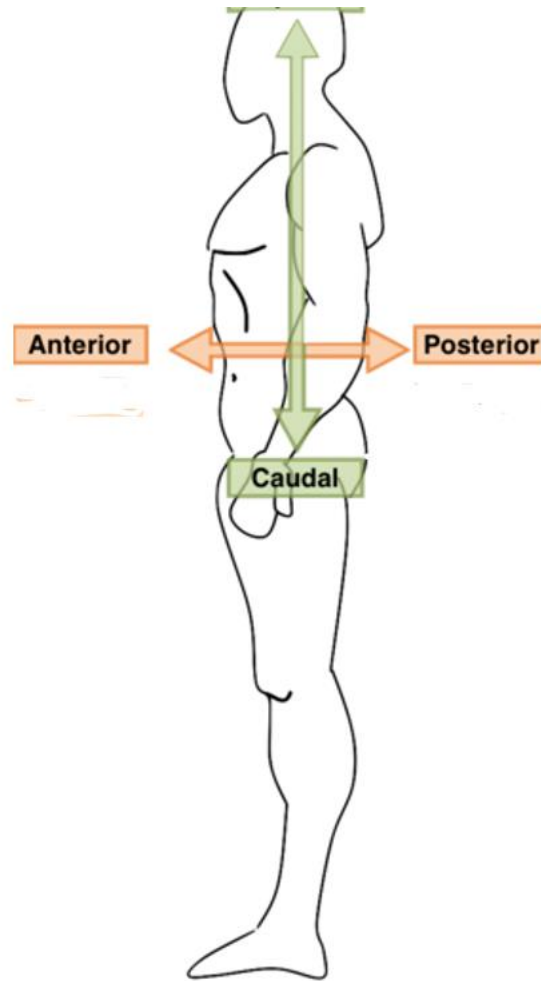
Planes of sections



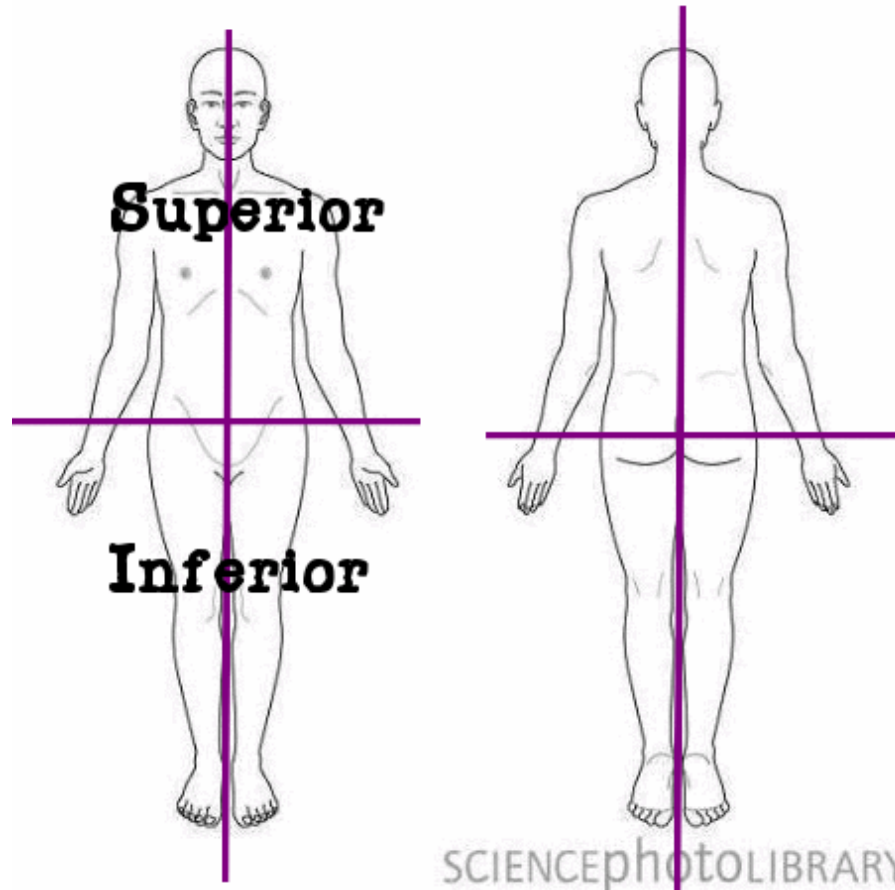
Anterior and Posterior



Anterior and posterior examples

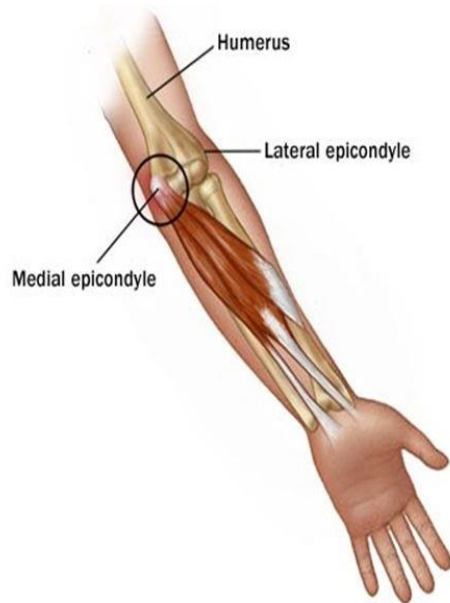

Superior and inferior

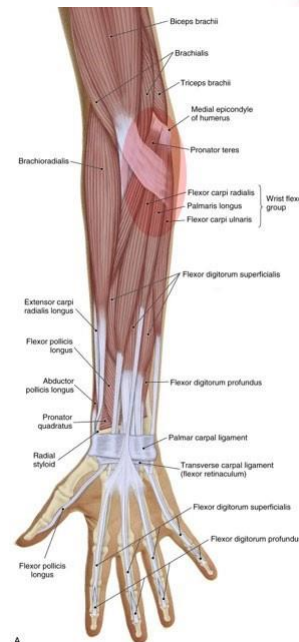
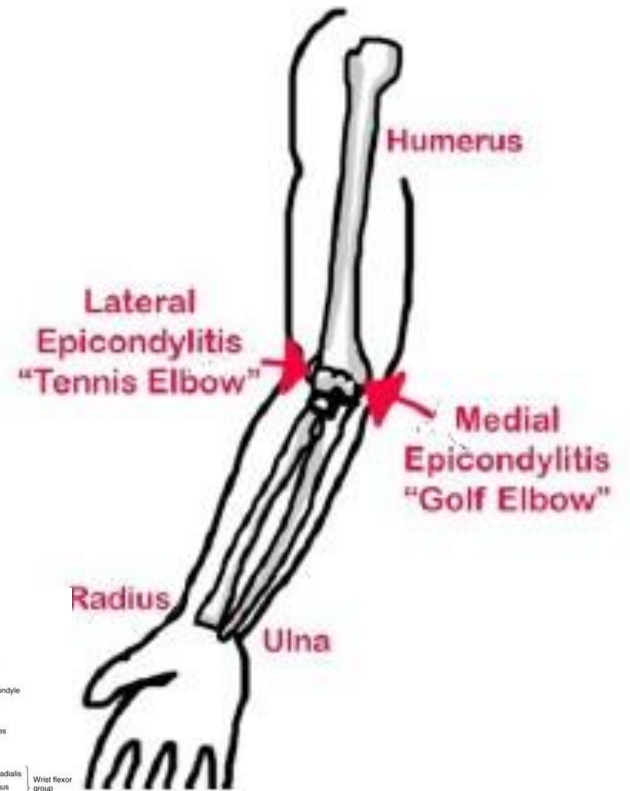


Medial and lateral

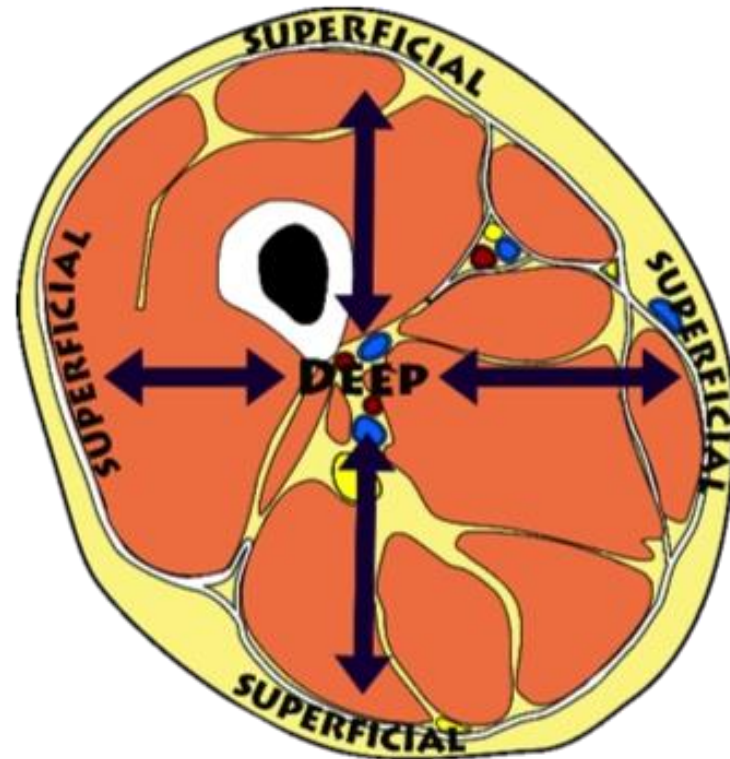
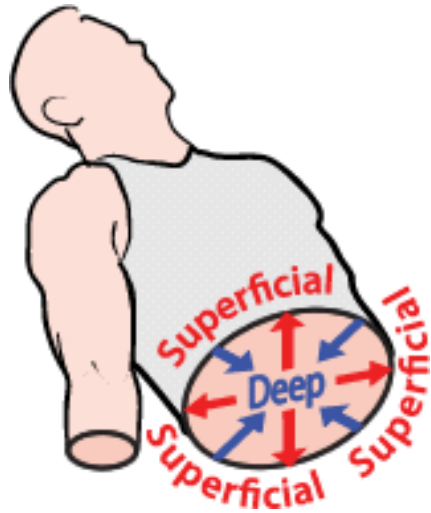
Golfer's Elbow and Tennis Elbow



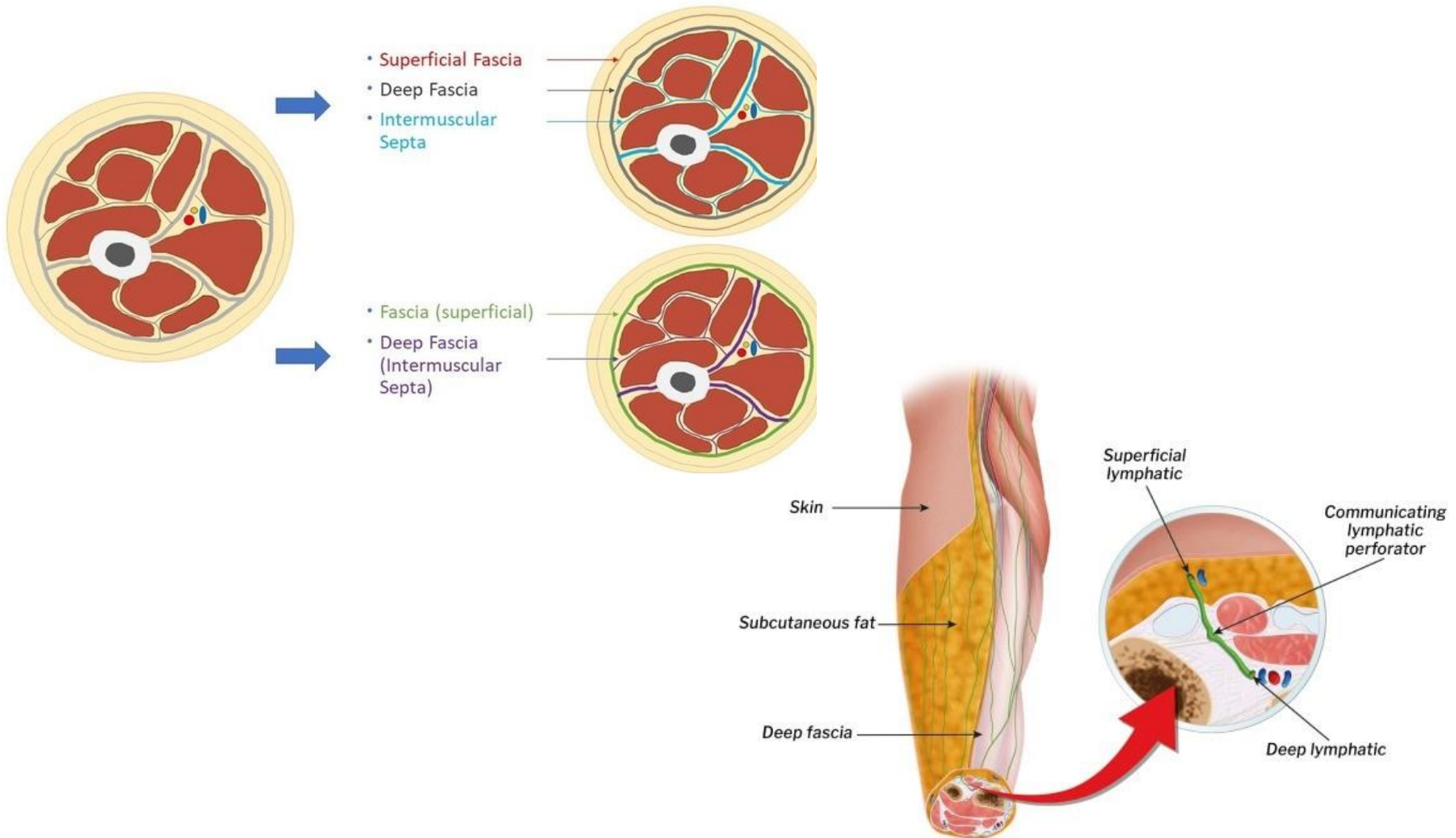
- Golfer's Elbow:
 - Medial Epicondylitis
- Tennis Elbow:
 - Lateral Epicondylitis



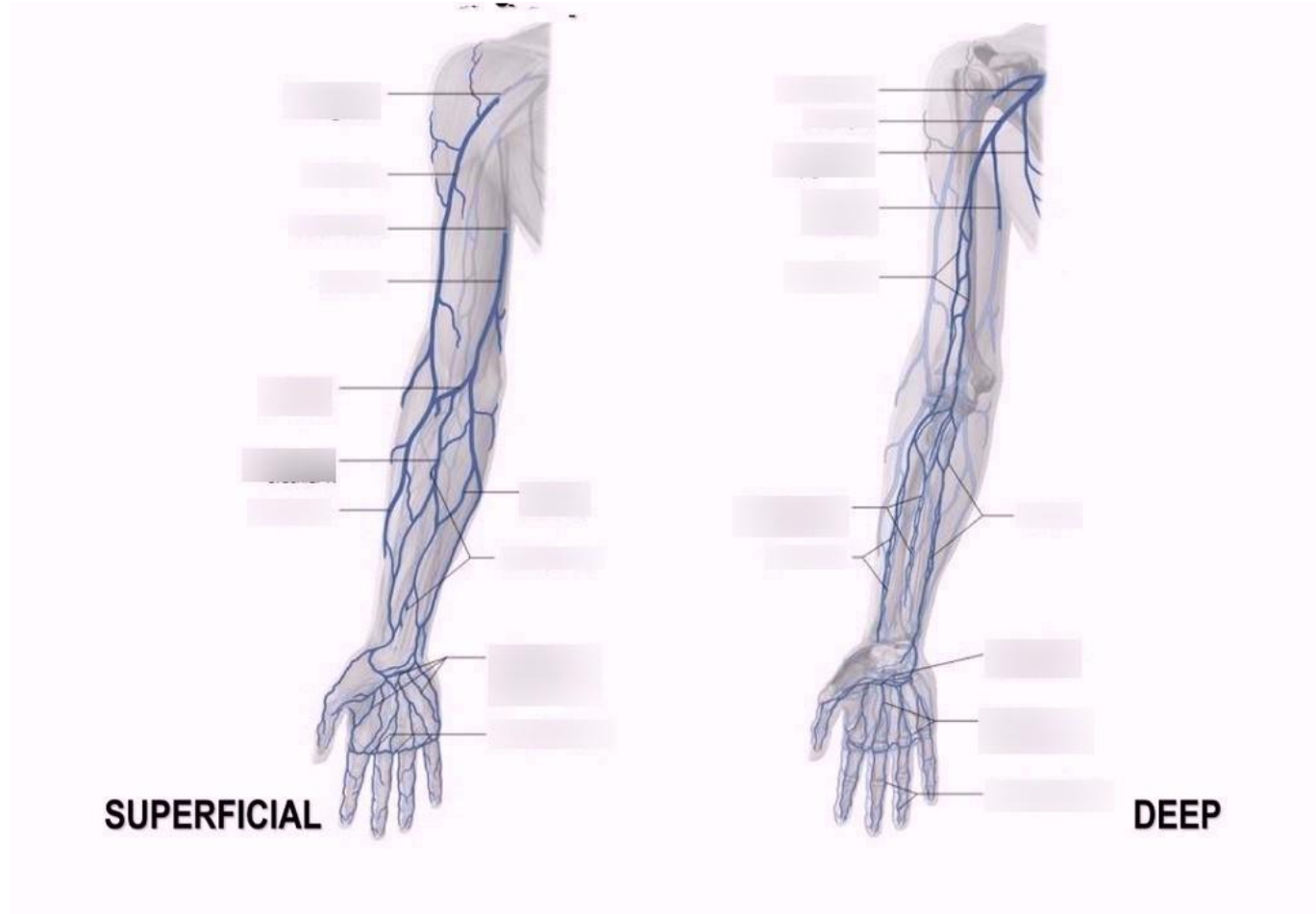
Superficial and deep



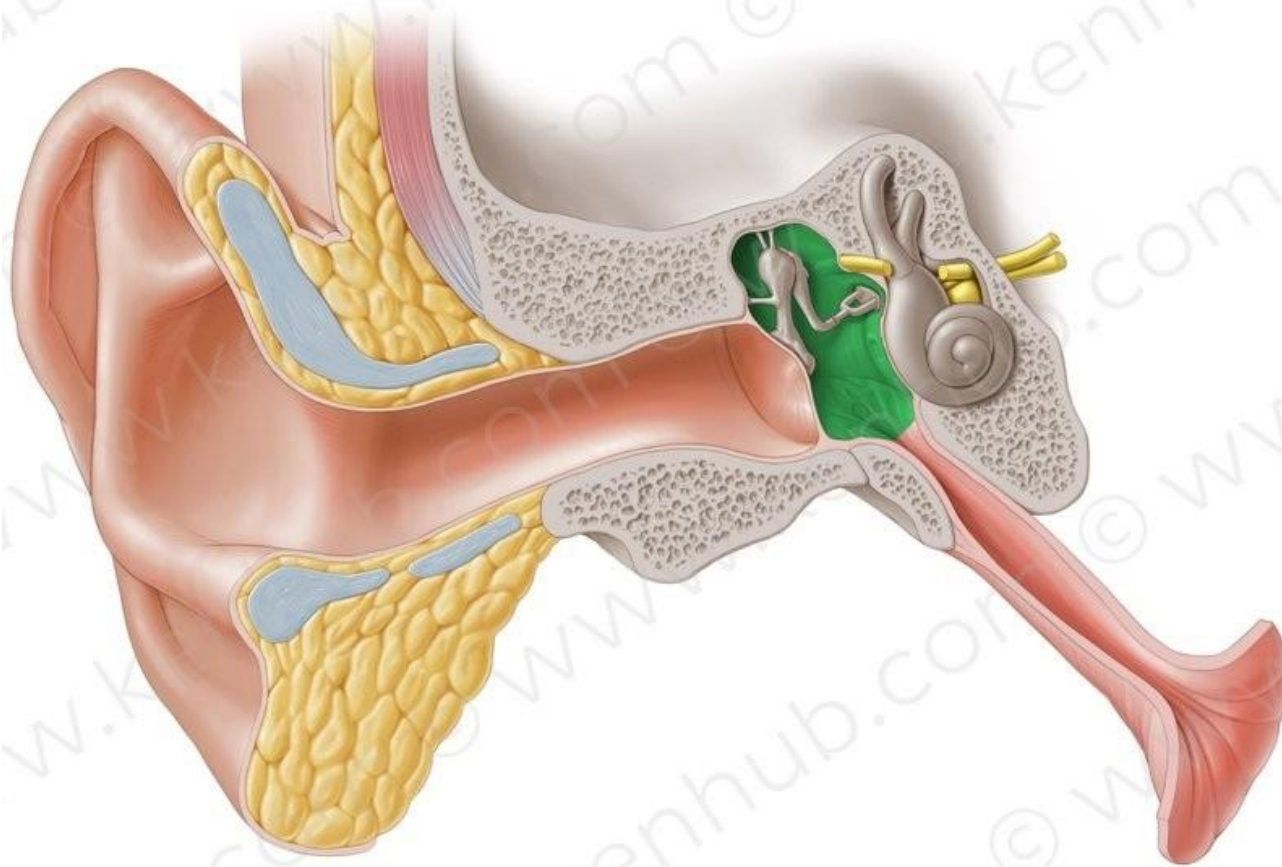
Superficial and deep examples



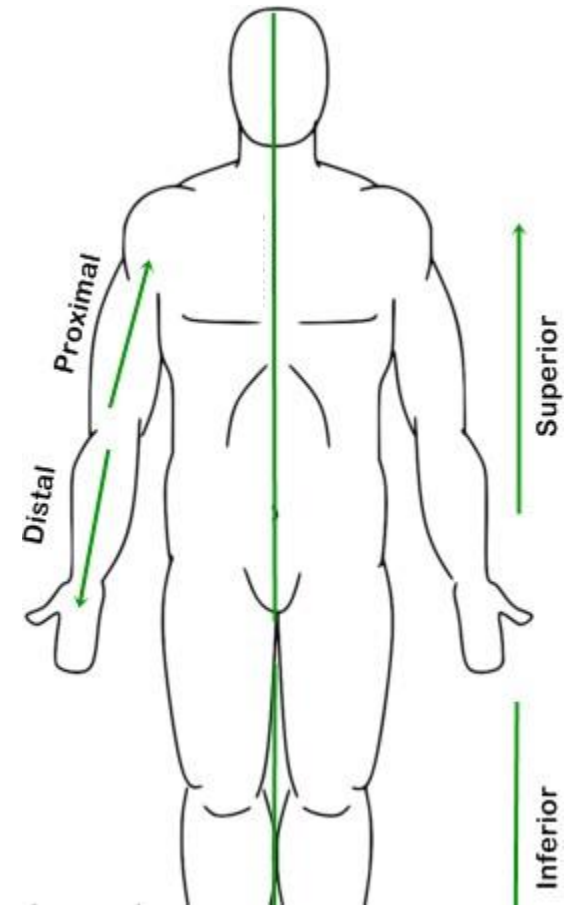
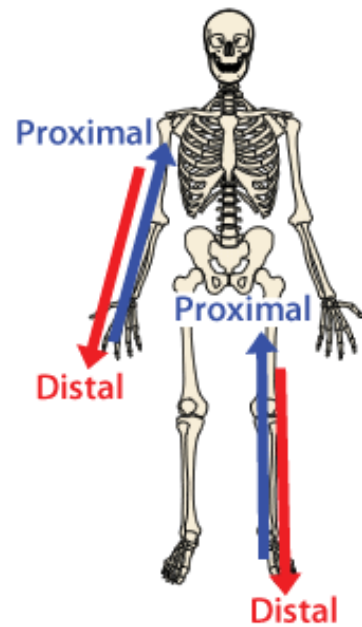
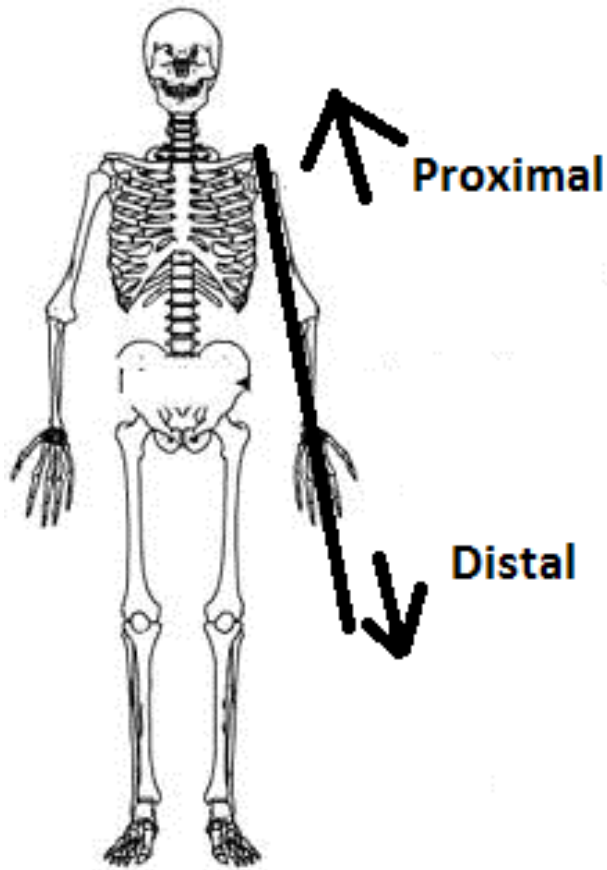
Superficial and deep examples



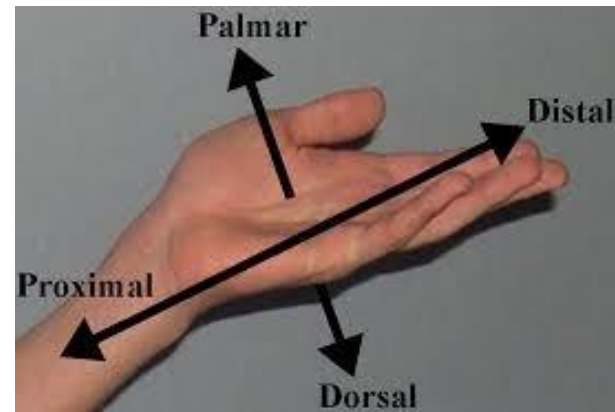
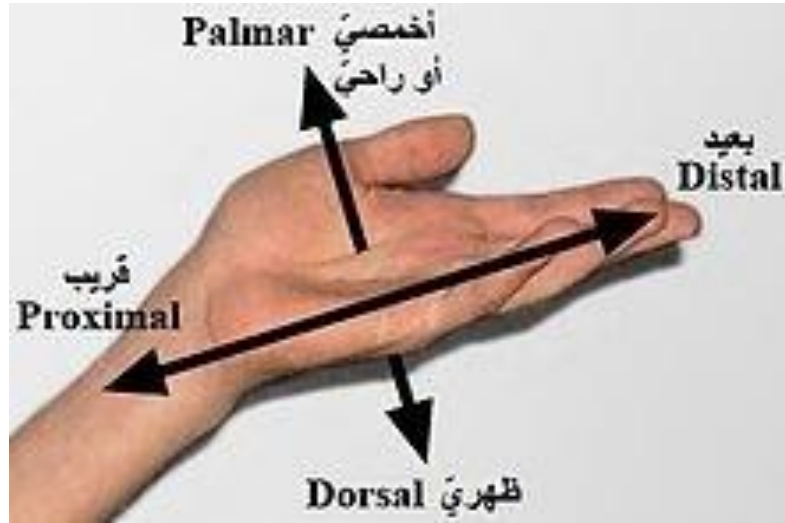
Internal and external



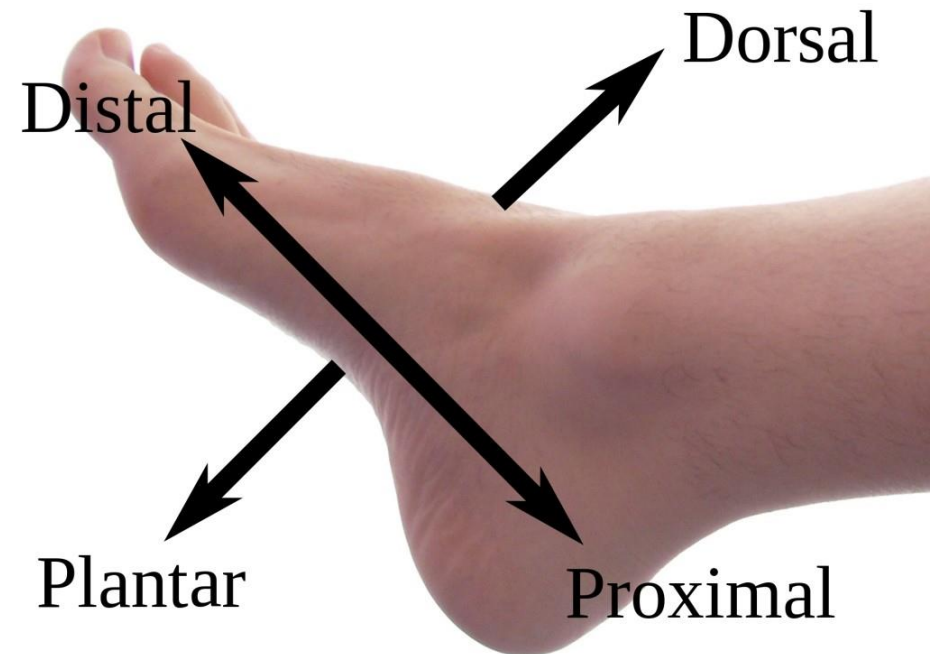
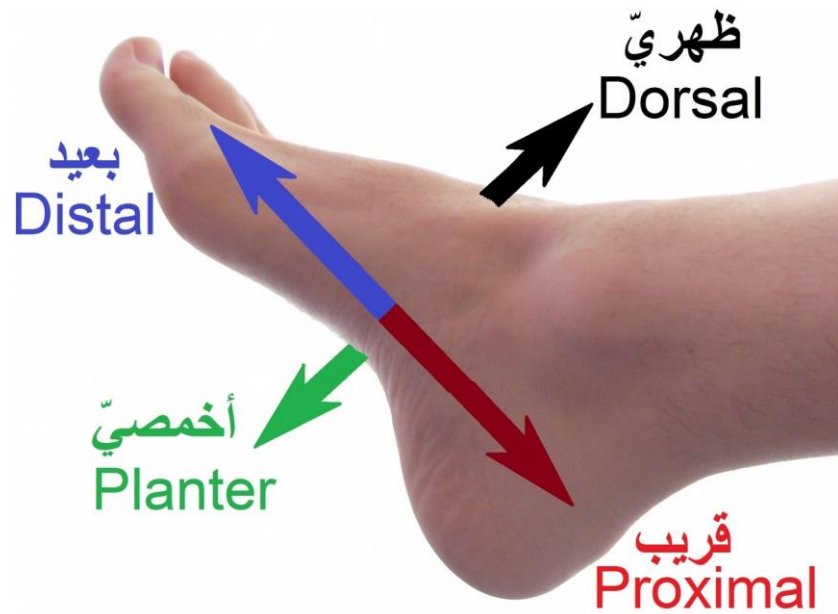Proximal and distal



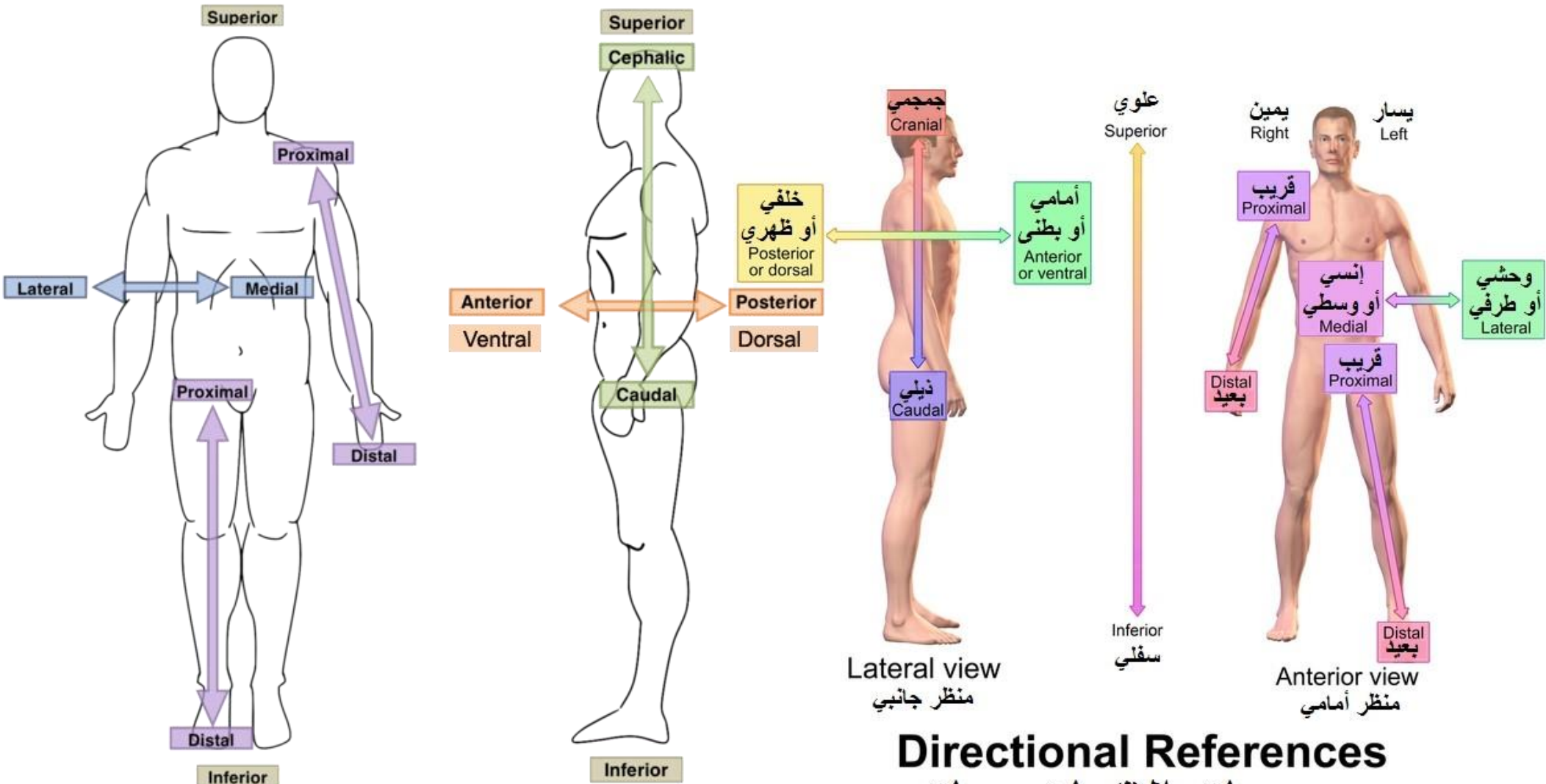
Hand directions



Foot directions

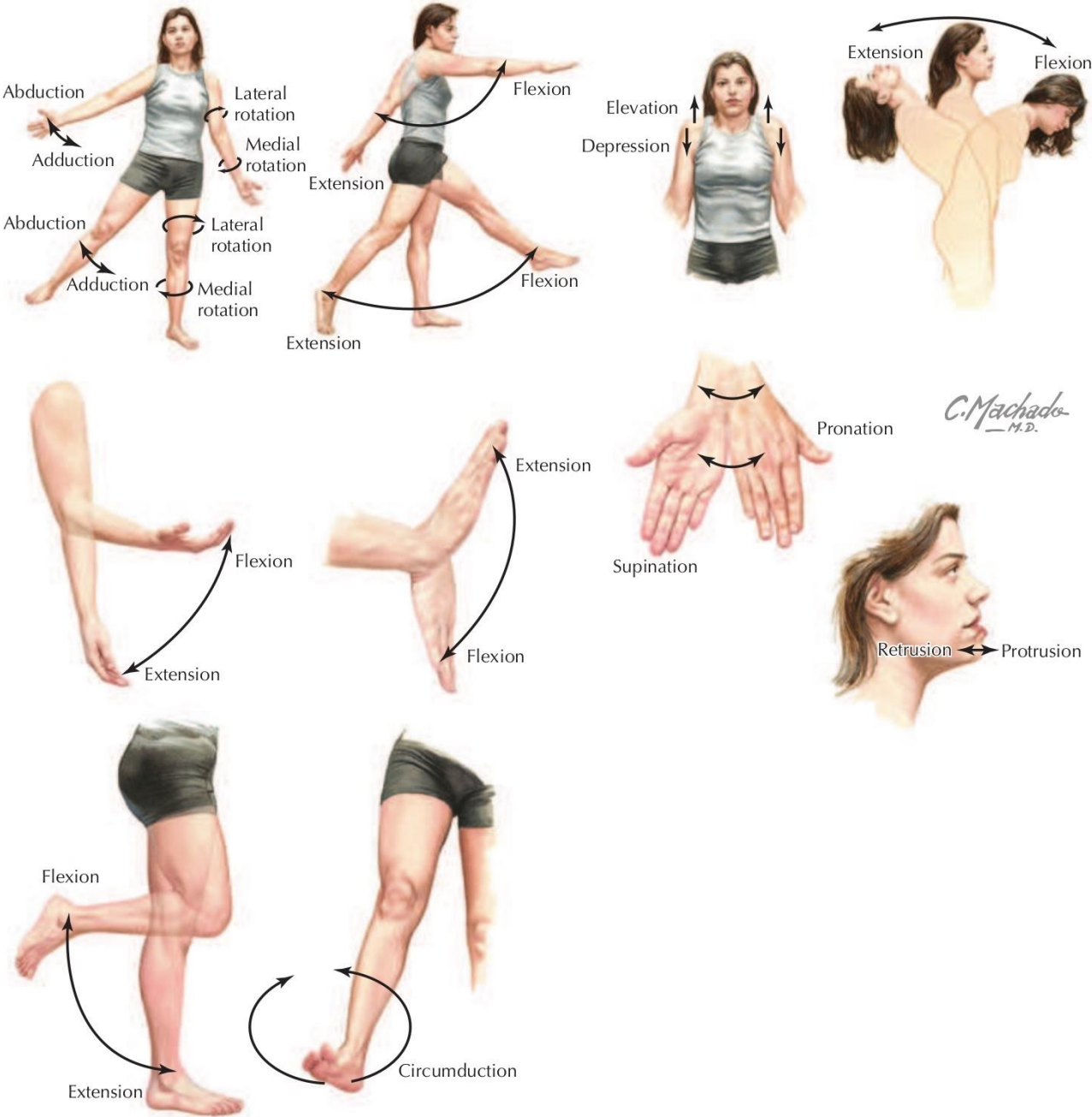

Body planes and terms of direction

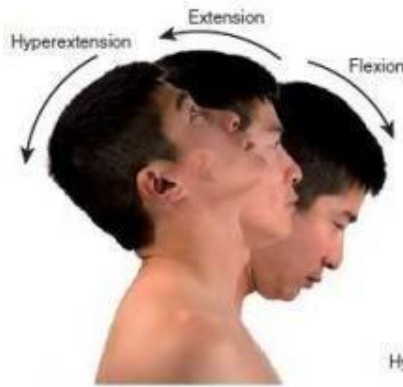


Directional References مرجعيات الإتجاهات

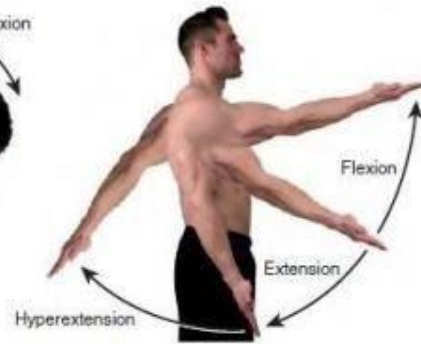
Terminology(movements)



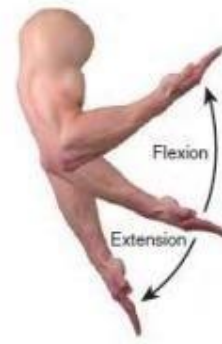Flexion and extension



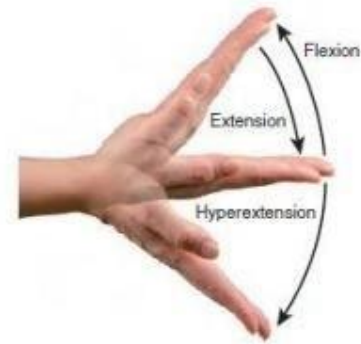
(a) Atlanto-occipital and cervical intervertebral joints



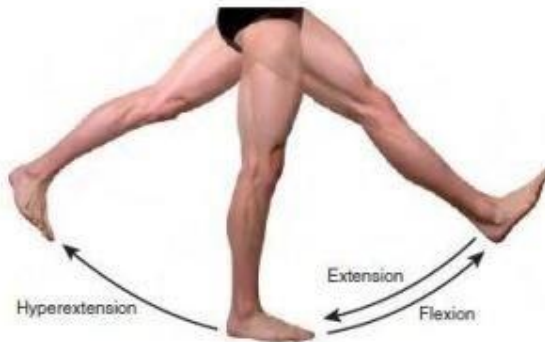
(b) Shoulder joint



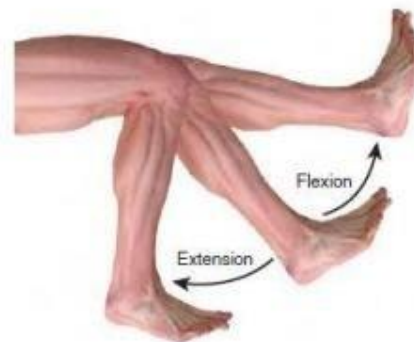
(c) Elbow joint



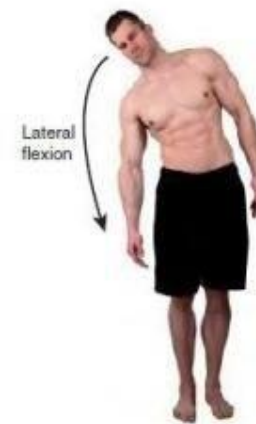(d) Wrist joint



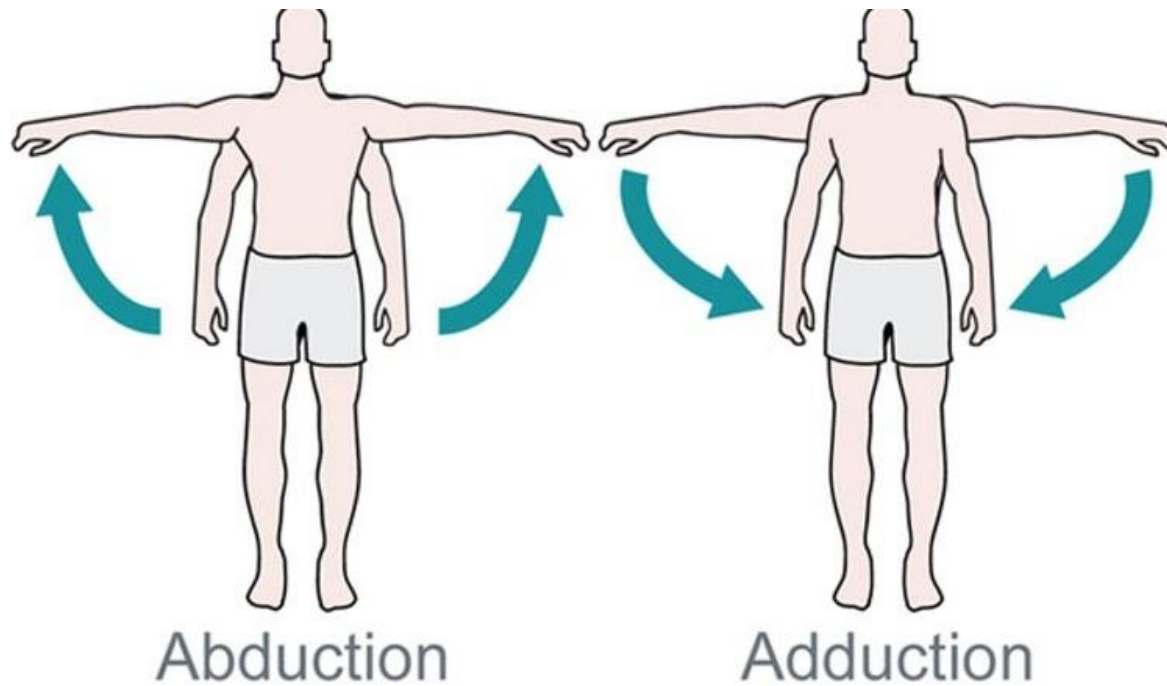
(e) Hip joint



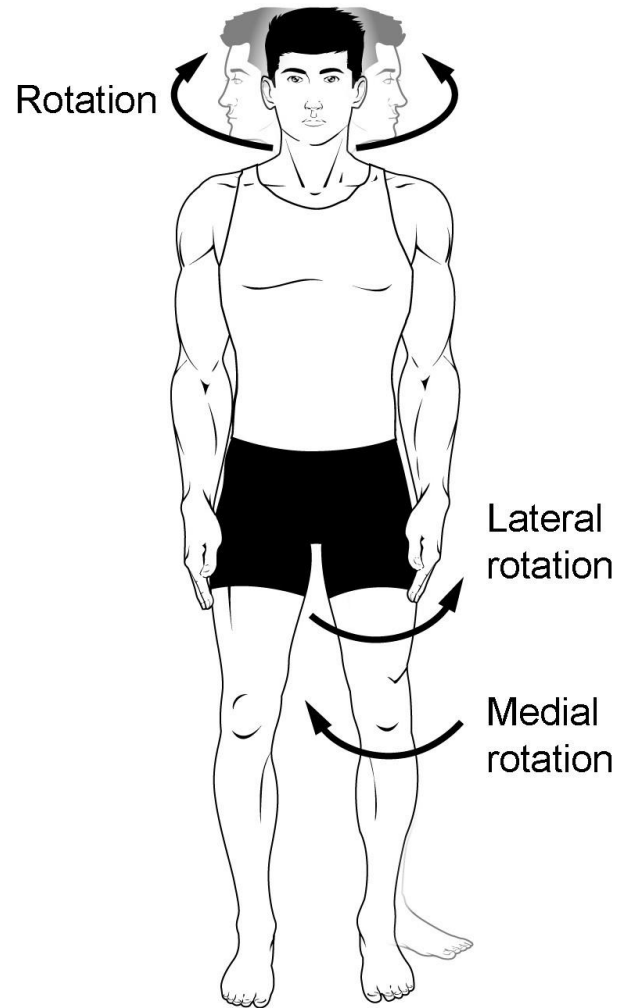
(f) Knee joint



Abduction and adduction



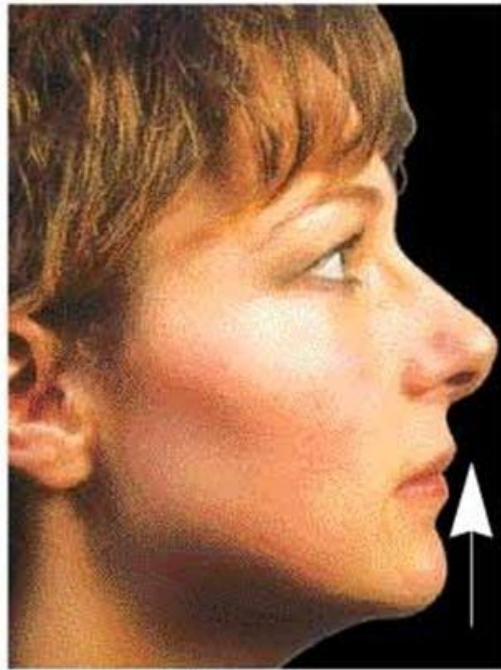
Rotation



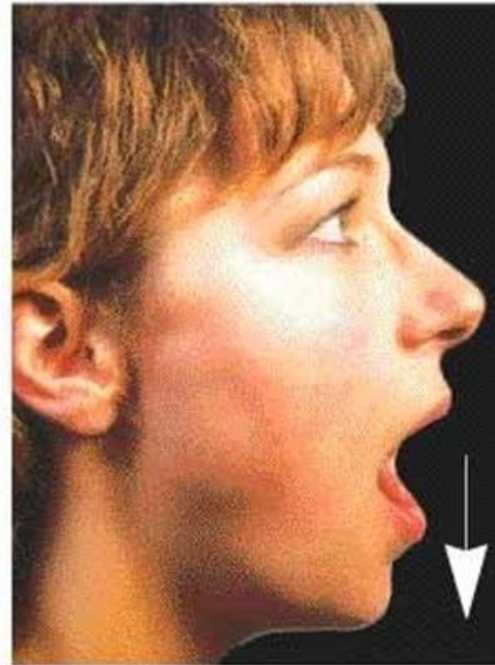
Rotation of the head,
neck, and lower limb

Elevation and depression

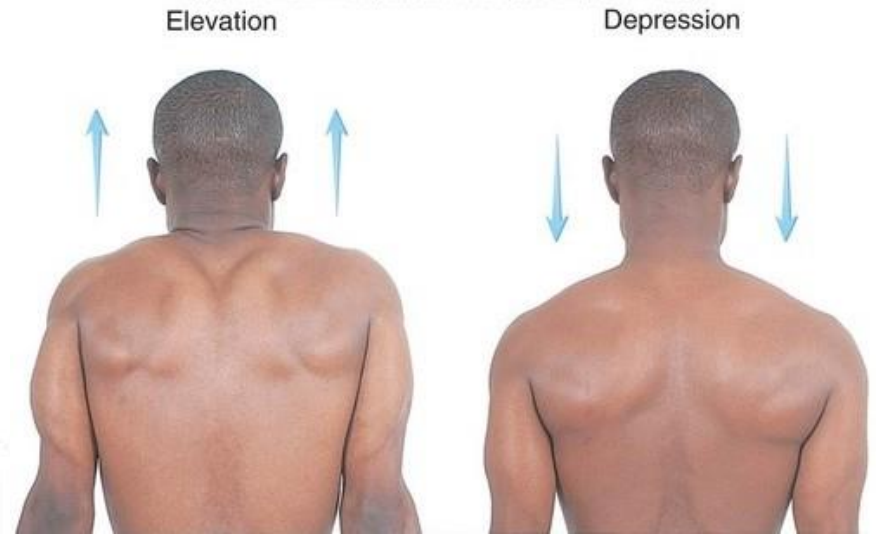
Elevation & Depression



Elevation



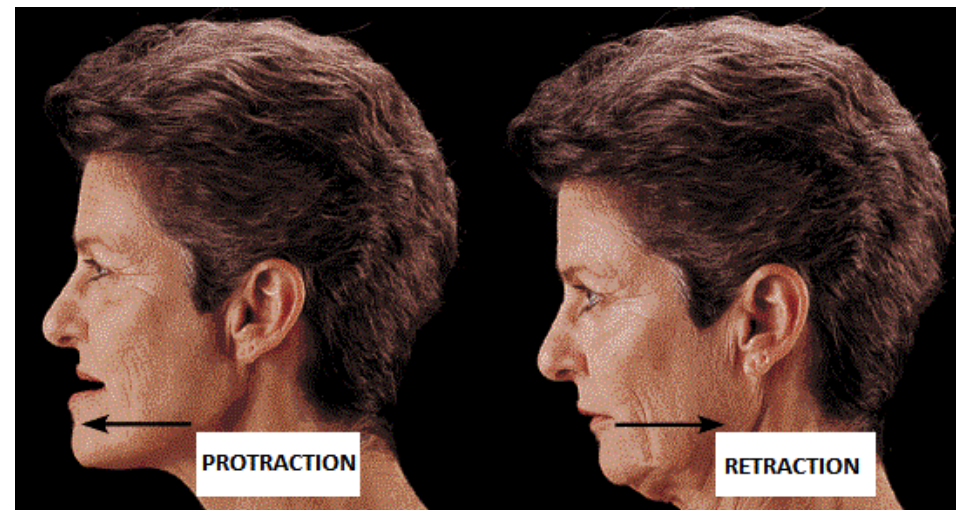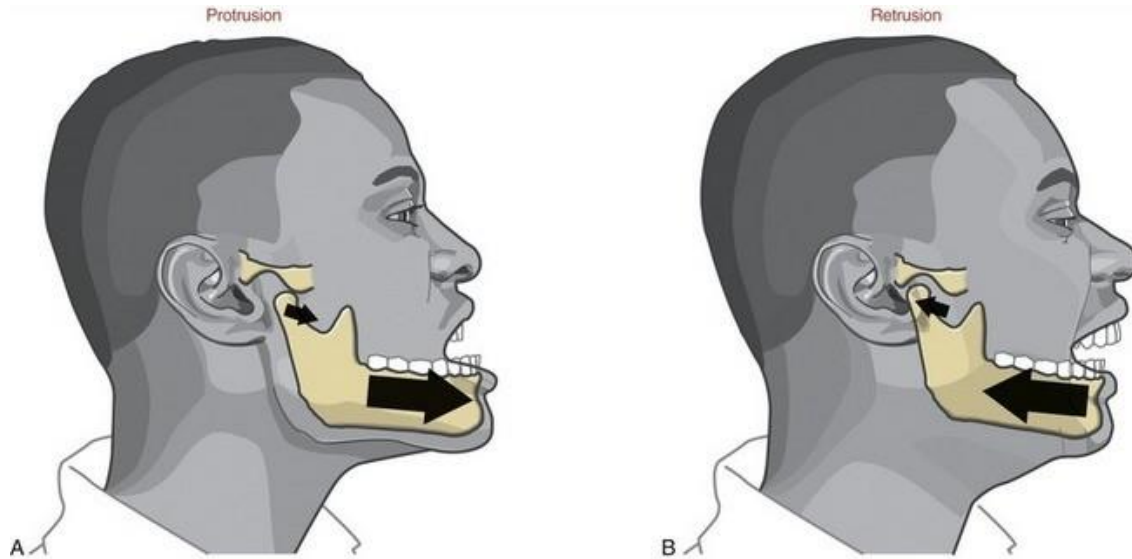
Depression



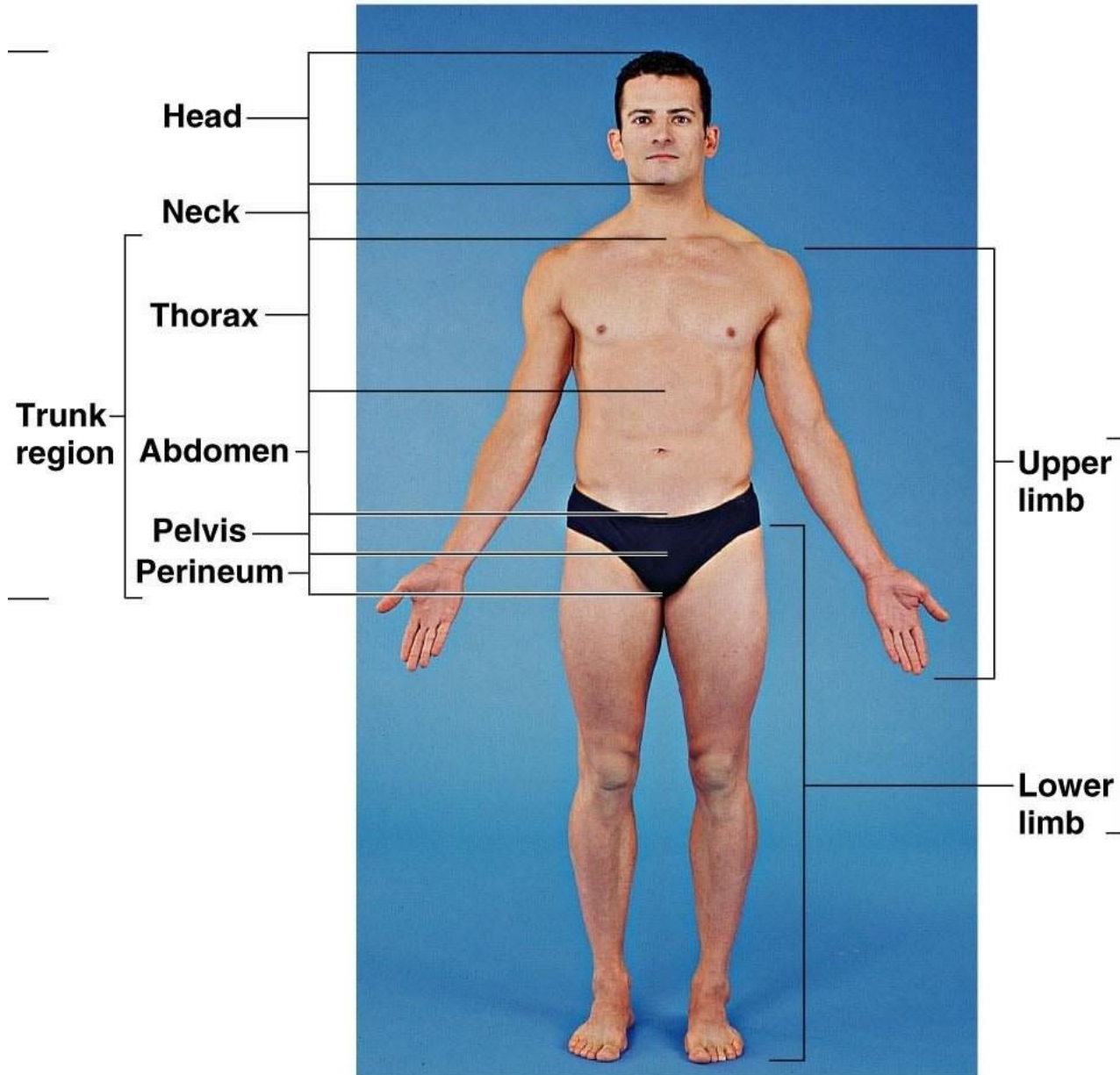
Elevation

Depression

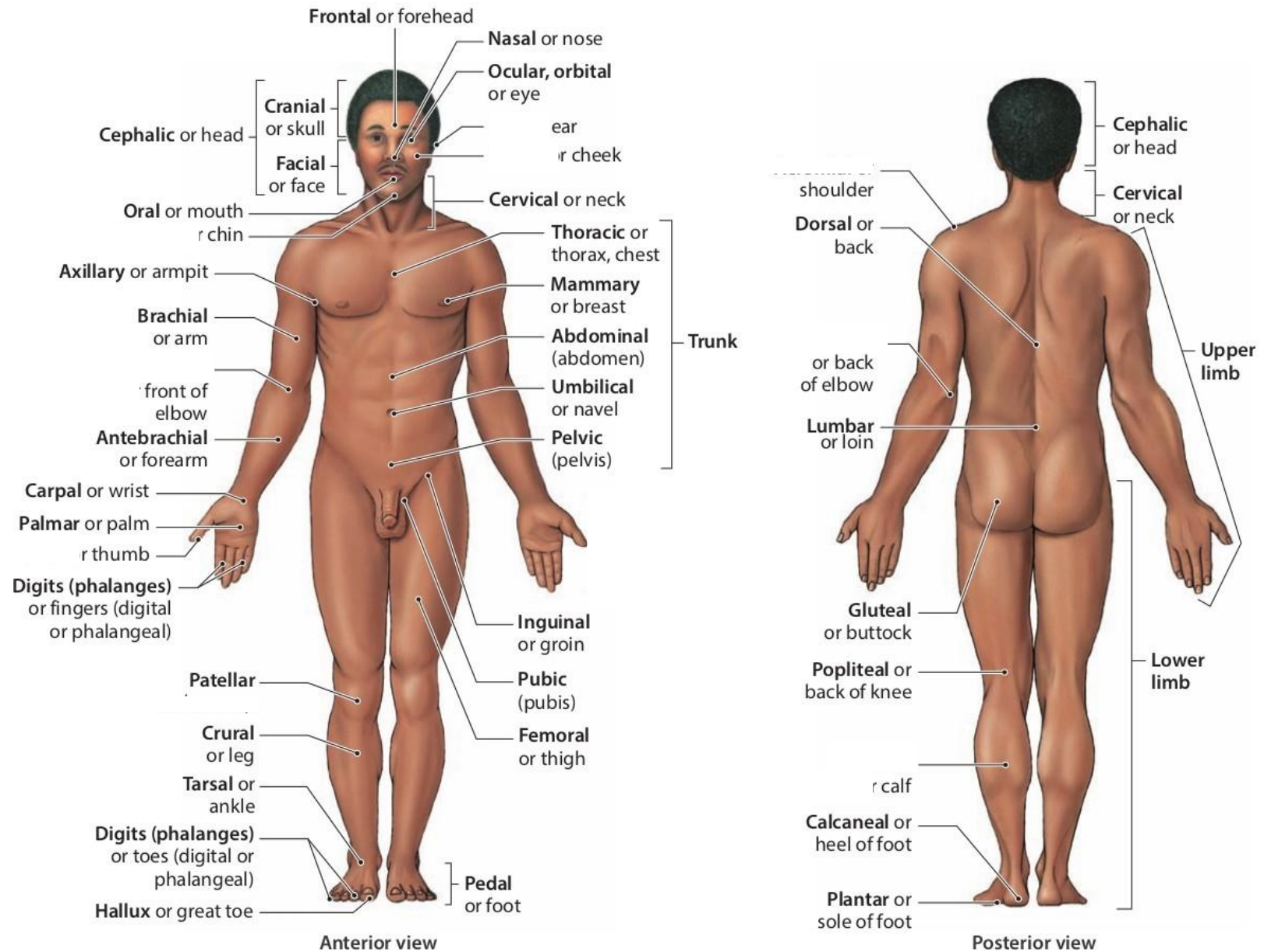
Protrusion and retrusion



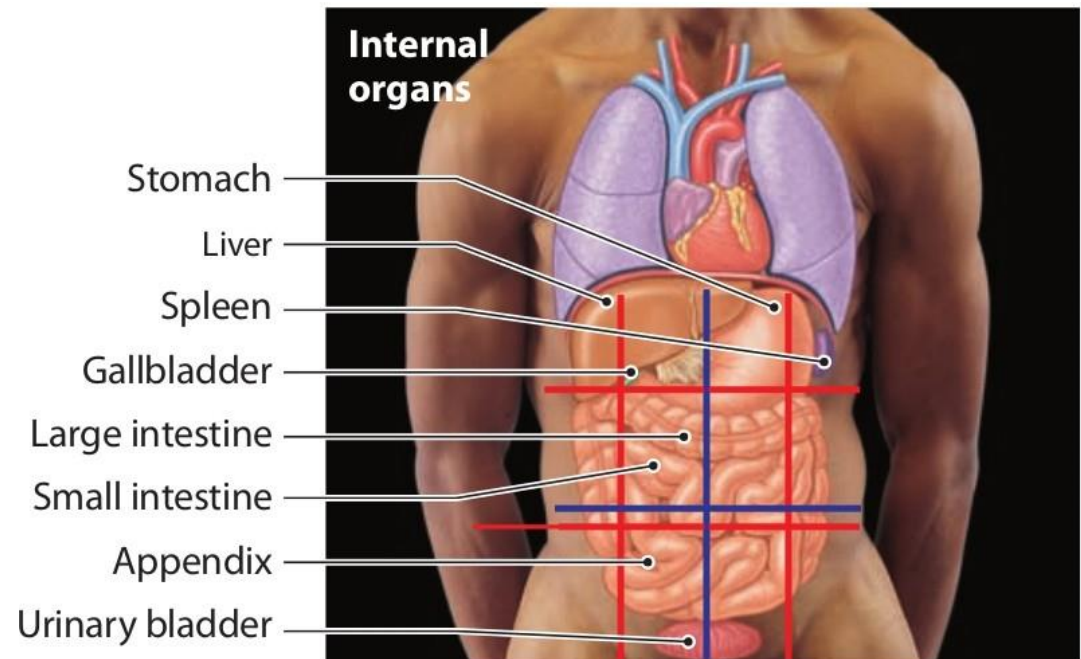
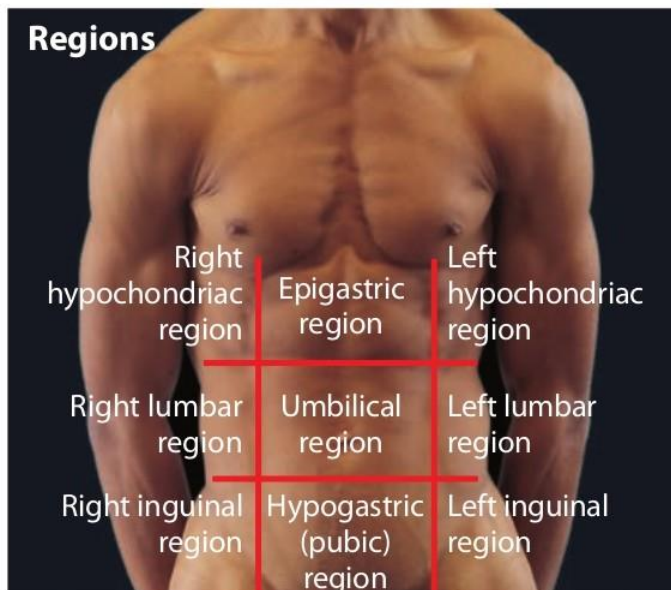
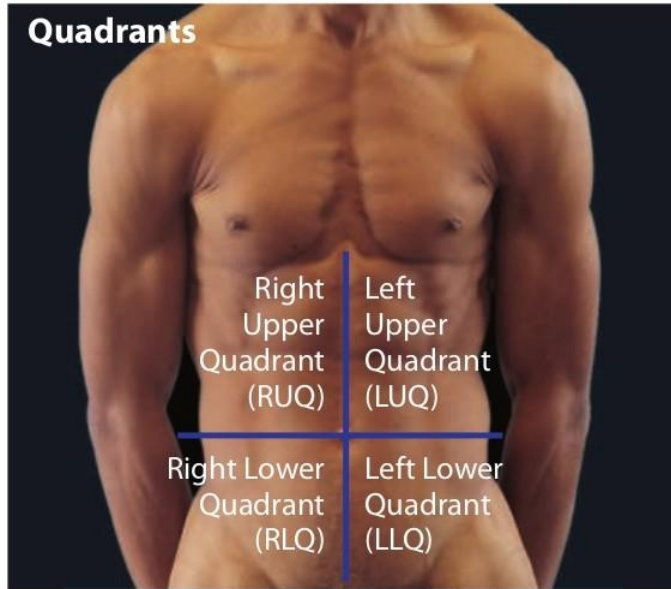
Surface anatomy



Surface anatomy



Abdominal quadrants and regions



Thank you