



**Department of Anesthesia Techniques**

**Title of the lecture: - invasive and non-invasive blood  
pressure monitoring**

**Mohammed AbdulZahra Al\_Mosawi**

**PhD, MSc. Anesthesia and ICU**

**TUMS, SUMS**

**Mohammed.abulzahra@oumus.edu.iq**

# Noninvasive and Invasive Blood Pressure Monitoring

Blood pressure (BP) measurement is a fundamental aspect of monitoring the cardiovascular system during conduct of anesthesia and in intensive care. Monitoring standards mandate that the BP should be recorded at least every 5 minutes during anesthesia.

## Two type of monitoring blood pressure

### 1. Non-invasive

#### a. Manual Intermittent Technique

\*\*Which determined the systolic blood pressure (SBP) using an inflatable cuff and mercury manometer. The pressure at which the arterial pulse disappeared on palpation during cuff inflation was the systolic pressure.

\*\*Using a sphygmomanometer, cuff and stethoscope, systolic and diastolic blood pressure (DBP) is measured by auscultation.

#### b. Automated Intermittent Technique

Most devices are based on oscillometry. Arterial pulsations (oscillations) during cuff deflation are sensed by the monitor

### ## Factors Affecting Blood Pressure Measurements:

#### 1. Cuff Size:

The optimal cuff should have a bladder length that is 80% and a width at least 40% of arm circumference. An inappropriately large cuff will underestimate BP, and a small cuff will overestimate BP.

#### 2. Site:

The forearm and wrist or the ankles are alternate sites when the upper arm is not accessible or the cuff does not fit. The systolic pressure increases and the diastolic decreases as the measurement site moves peripherally. The cuff should ideally be at the level of the heart. 7.5

mmHg should be added or subtracted for cuff positioned 10 cm above or below the level of the heart.

**3. Cardiac Rhythm:** Oscillometry can be erroneous in patients with dysrhythmias.

**Important note:** The international standard limits the maximum cuff pressure obtainable during normal use to 300 mm Hg for equipment specified for adults and 150 mm Hg for equipment specified for neonates.

**Tips for Correct Use:**

- NIBP cuff should preferably not be placed on the same limb as the intravenous (IV) infusion. This may stop or slow the infusion or cause back flow of blood into the infusion tubing.
- The cuff should not be applied over a bony prominence, superficial nerve or joint.
- Padding should be placed under the cuff to prevent skin bruising and nerve damage in susceptible patients.
- Too tight application can cause discomfort and venous congestion. Too loose an application will lead to erroneous reading or the monitor will be unable to make a measurement.
- The frequency of measurement should be only as clinically necessary. Very frequent measurements can increase complications while not necessarily adding to clinically relevant information.
- During prolonged application, periodic inspection and change of cuff site to another location is recommended.

**Complications:**

Complication occur more frequently after prolonged periods of excessively frequent cycles of cuff inflation or deflation and are due to trauma or impaired distal limb perfusion.

- a. Damage to underlying structures: Skin bruising, pain, erythema, petechiae, ecchymoses, limb edema, peripheral neuropathies.
- b. Compartment syndrome.

- c. Erroneous readings and artifacts: This can be due to cuff malposition, incorrect size, leaking cuff, hose or connector. Motion artifacts can occur due to intrinsic factors, e.g. patient movement, shivering, convulsions and extrinsic factors, e.g. external pressure on the cuff.

**Limitations:**

- Rapid BP changes cannot be monitored
- NIBP monitors function poorly at extremes of heart rate and BP
- Prolonged cycle times, e.g. hypertensive patients, poor peripheral circulation, leaking cuff or hose, artifacts, causes patient discomfort.

**INVASIVE BLOOD PRESSURE OR DIRECT ARTERIAL PRESSURE MEASUREMENT:**

Intra-arterial or direct BP provides a continuous display of the arterial waveform along with measurements of MAP, systolic and diastolic pressure. Arterial cannulation with continuous pressure transduction and waveform display remains the accepted standard for BP monitoring.

**\*\* Indications of invasive blood pressure monitoring**

# Major abdominal surgery (pheochromocytoma, large retroperitoneal masses, splenectomy, hysterectomy).

# Neurosurgery—posterior fossa surgeries, meningioma, spinal surgeries

# Cardiac procedures requiring cardiopulmonary bypass – Surgery on aorta, other vascular surgery

# Orthopedic procedure – Oncosurgery – Organ transplants

# Surgery with large fluid shift

# Patient with recent history of myocardial infarction, unstable angina, low ejection fraction – Patient with right heart failure, chronic obstructive pulmonary disease, pulmonary hypertension, pulmonary embolism, Patient in cardiogenic shock, hypovolemic shock, septic shock

Patients with electrolyte or metabolic disturbances

Massive trauma

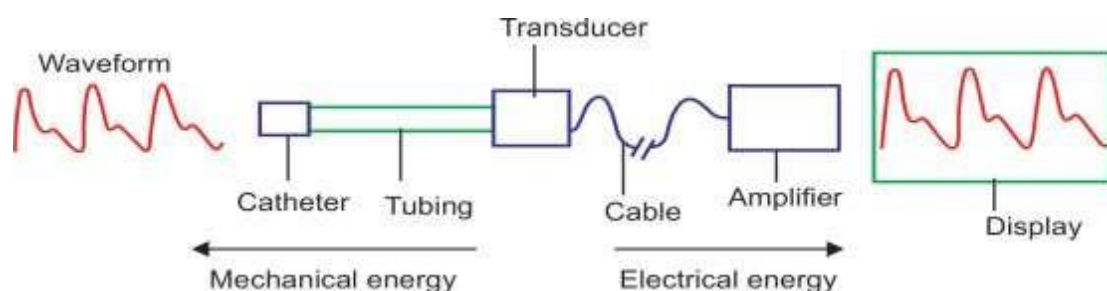
- Noninvasive blood pressure sites unavailable (severe burn, infection, morbid obesity)
- Repeated blood sampling • Arterial blood gas analysis

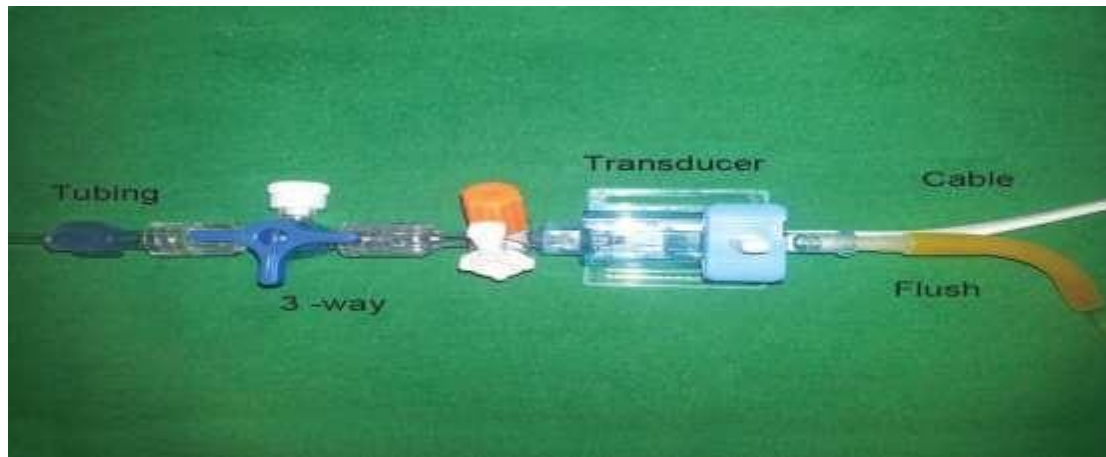
### **CONTRAINDICATIONS:**

- Inadequate circulation to the extremity
- Raynaud's syndrome
- Thromboangiitis obliterans (Buerger's disease)
- Full-thickness burn over insertion site
- Skin infection over insertion site
- Uncontrolled coagulopathy
- Systemic anticoagulation
- Inadequate collateral flow from ulnar artery on Allen test
- Atherosclerosis

### **Components of pressure measurement system**

- Intravascular cannula 20 G or less
- Coupling system
- Transducer
- Analysis and display system
- Flush system





### **Flush System:**

Flush system helps in maintaining the patency of the cannula. It provides continuous flush of plain or heparinized 0.9% normal saline at 1–3 mL/hour through a bag pressurized at 300 mm Hg. It reduces the risk of thrombus formation and prolongs the effectiveness of the cannula. Some practice avoid use of heparin in the flush system as it can cause heparin-induced thrombocytopenia.

### **Zeroing and Leveling:**

Transducer should be at zero or electrically balanced. Zeroing means zero current at zero pressure. This is done by turning the 3-way so that transducer is exposed to the atmosphere pressure and calibrated the pressure at zero. For better accuracy, the transducer should be at the level of RA in the midaxillary line.

### **EQUIPMENT:**

- Arterial catheter (appropriate to the patient size and site) – Radial (20 G)/Femoral (18 G)

20 G for adult and large children – 22 G or 24 G for small children, infant or neonate

- Syringe, 2 cc 1% plain lignocaine with 25 G or 27 G needle
- Syringe, 5 cc with heparinized flush
- Adhesive tape, Stopcock, 3-way

Pressure tubing, Pressure transducer kit with a flushing system.

## SITES:

1. **Radial artery** is preferred over other sites for cannulation, because it is superficial and is associated with less complication. Before proceeding for radial arterial cannulation, one should perform modified Allen's test to assess the collateral circulation of the hand.
2. About 90% of hand circulation is dependent on **ulnar artery**. Ulnar artery is also a good option for cannulation when the hand circulation depends on radial artery or in case unavailability of radial artery. Complications include hematoma, thrombosis and in extreme case ischemic complication leads to gangrene of the hand.  
\*\*Catheterization is usually more difficult than radial catheterization because of the ulnar artery's deeper and more tortuous course.

### **Important note:**

In case of brachial artery cut down for cardiac catheterization, radial or ulnar artery cannulation should not be performed as it may give false low pressure value. More than three attempts are not feasible for cannulation of same artery as it causes vasospasm of the artery. Repeated attempts may cause ischemia of the hand in extreme case.

**Brachial Artery:** The brachial artery lies in the antecubital fossa. Brachial artery cannulation can be done but better to avoid as there is no collateral flow to the hand in case of brachial artery occlusion. Therefore, other site should be preferred over it.

**Femoral artery** is prone to atheroma formation and pseudoaneurysm, but often provides an excellent access. The femoral site has been associated with an increased incidence of infectious complications and arterial thrombosis. Aseptic necrosis of the head of the femur is a rare, but tragic, complication of femoral artery cannulation in children.

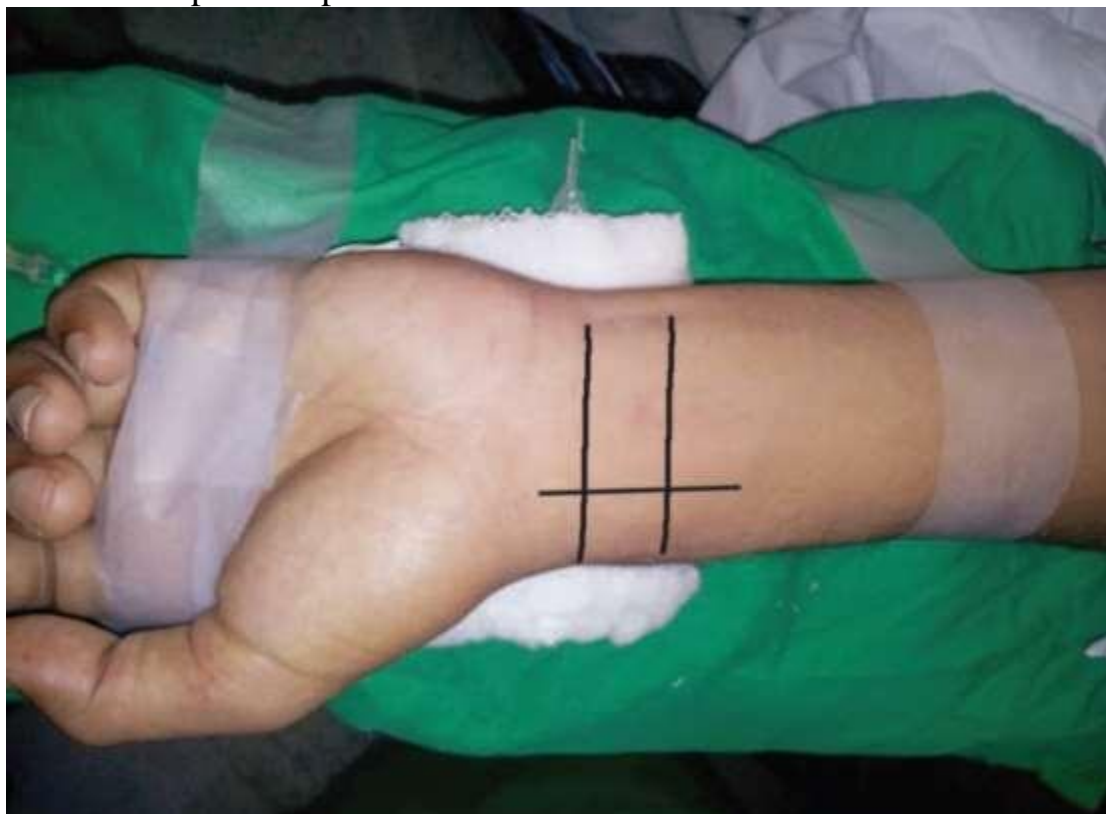**dorsalispedis and posterior tibial arteries** are some distance from the aorta and therefore have the most distorted waveforms.

**Axillary artery** is surrounded by the axillary plexus, and nerve damage can result from a hematoma or traumatic cannulation. Air or thrombi can quickly gain access to the cerebral circulation during vigorous retrograde flushing of axillary artery catheters.

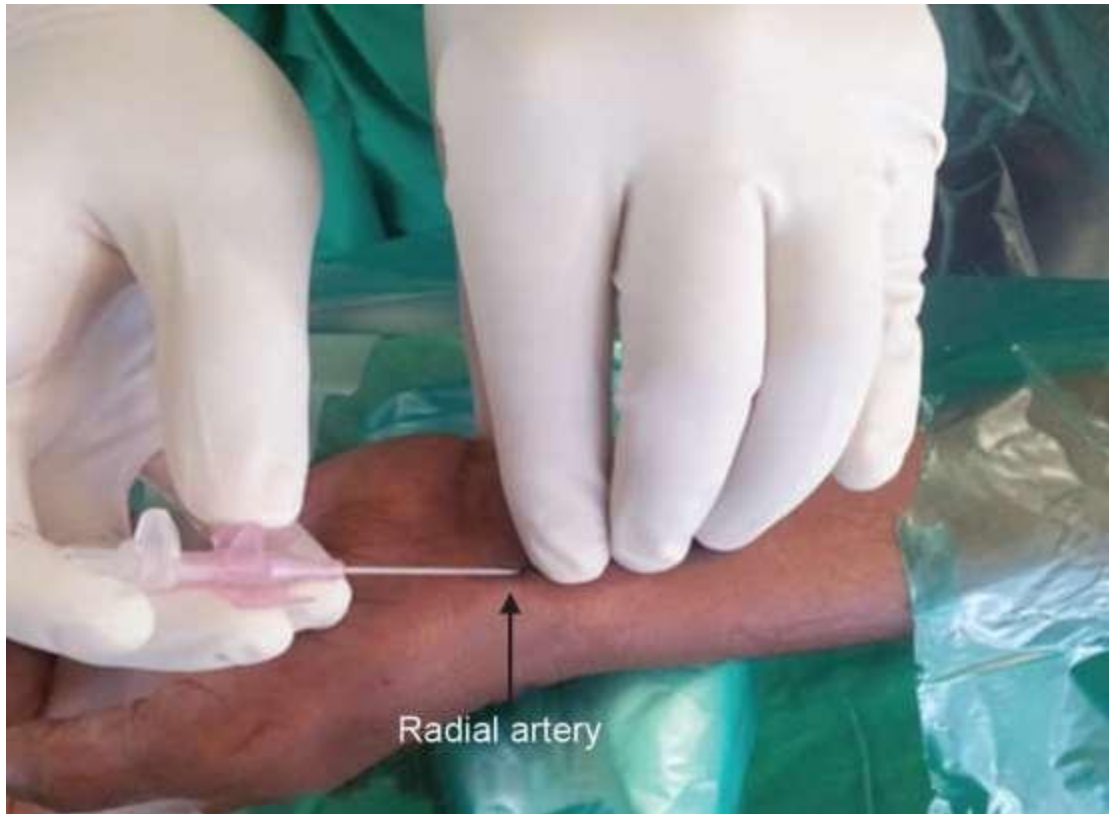
**Superficial Temporal Artery:**

**POSITION:**

Dorsiflexion of wrist over rolled up towel in supination. Paint the area with 4% chlorhexidine gluconate or povidone-iodine and after draping local anesthetic agent 1% lignocaine (without adrenaline) is infiltrated at the site. After completion of the procedure, one should never forget to keep back the hand in anatomical neutral position as prolong hyperextension can lead to neuropathy of the hand. In case of femoral artery cannulation, keep folded towel under the buttocks and upper one-third of the thigh, this makes the site flat especially in pediatric patient. In morbidly obese patient, assistant helps in pulling up the abdomen as it obstruct the plane of puncture site.

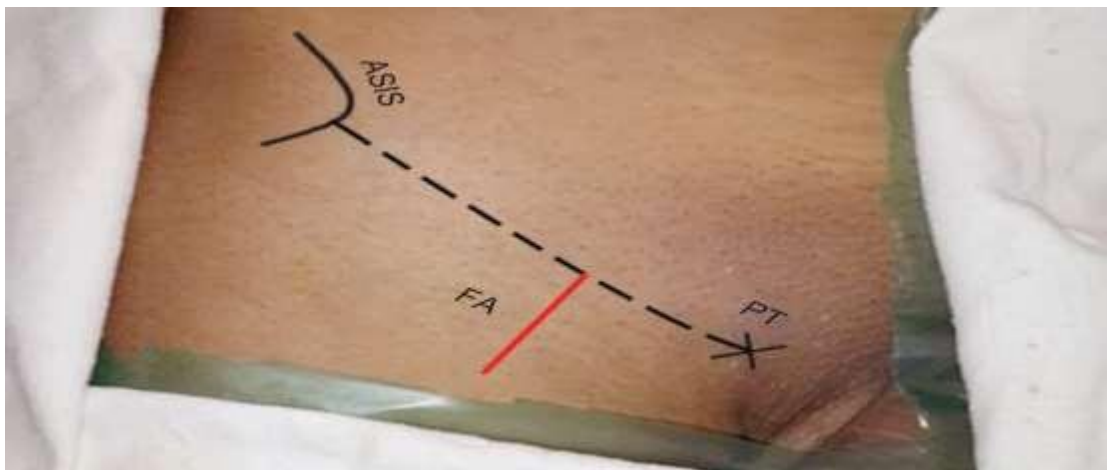






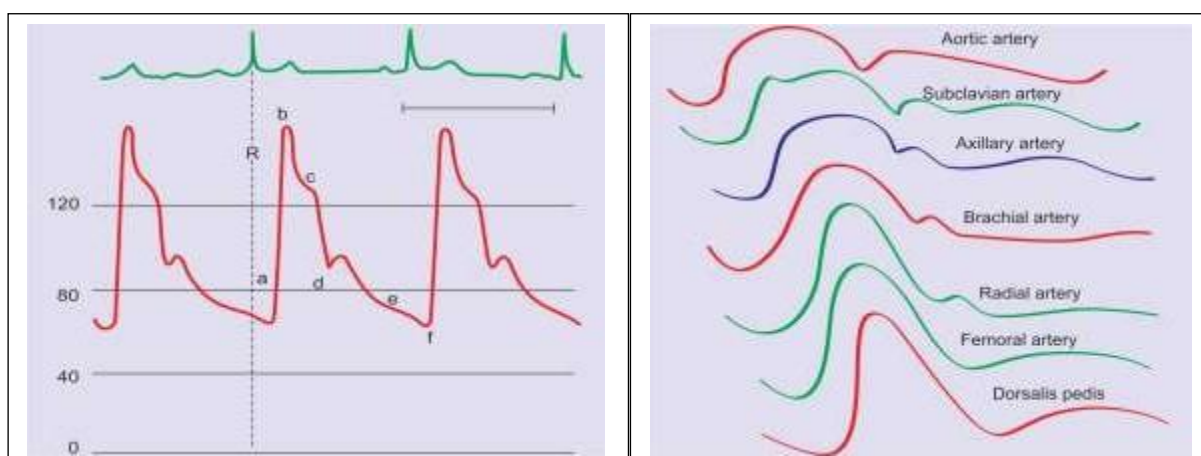
**TECHNIQUE:**

**Direct Cannulation** Palpate the radial artery with three fingers. Introduce the intravenous cannula at an angle of 30–45° while feeling the pulse under the pulp of finger, simultaneously look at the hub of cannula, there will be flash of blood as it enters the artery. Depress the cannula about 10–15° and withdraw the needle a little, continuous flow of blood will be seen at the hub. Stabilize the needle and advance the catheter over it. Remove the needle and attach the 3-way with a syringe-filled with heparinized flush to the hub. Attach the pressure transducer tubing to it. Secure the catheter with suture or adhesive tape.



## COMPLICATIONS:

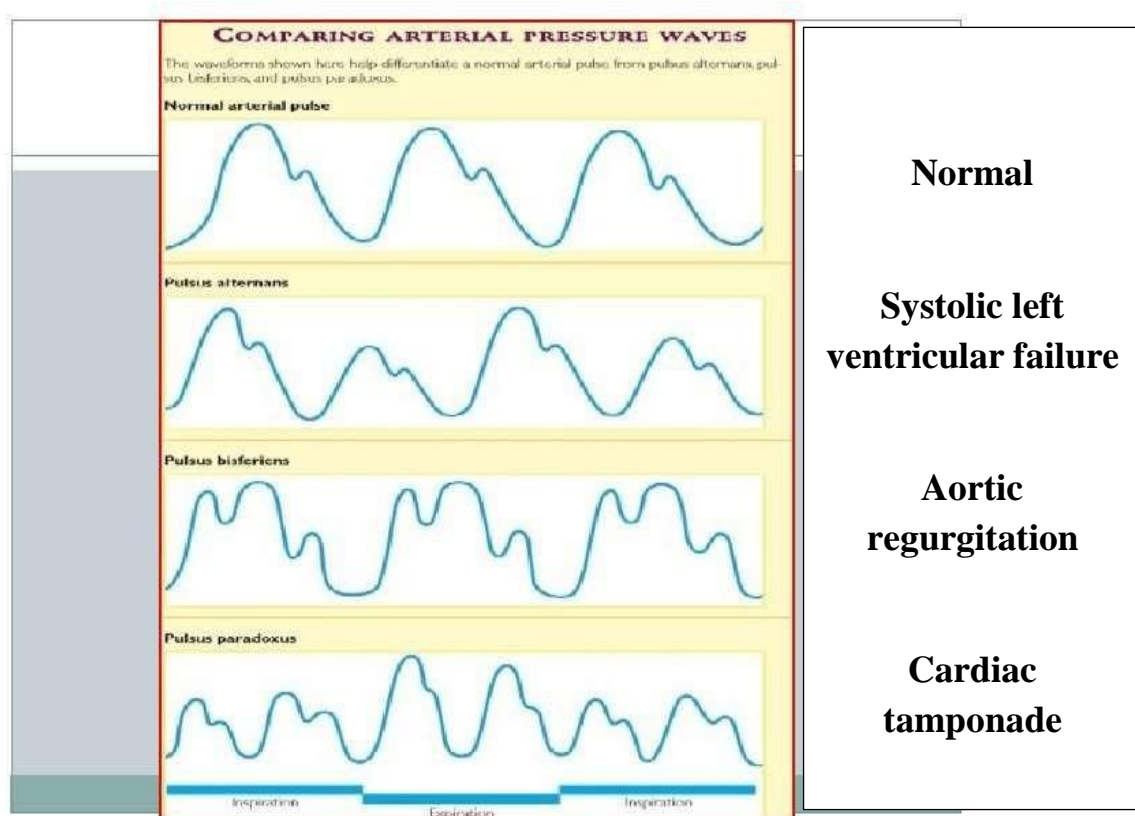
- 1. Infection:** Indwelling catheter infections occur due to poor aseptic technique, infection at the site, poor maintenance on prolong duration in ICU.17 Catheter-induced sepsis and cellulitis require immediate removal of the cannula, wound cleaning and systemic antibiotic therapy.
- 2. Bleeding:** Pressure bandage should be applied over the puncture site for 5–7 minutes (approx clotting time) in case of hematoma.
- 3. Thrombosis and distal ischemia**
- 4. Embolization:** Sudden flushing may cause central or cerebral arterial embolization. Continuous flush with heparinized normal saline at 1–3 mL/hour through the pressurized bag prevents thrombosis formation and embolization.
- 5. Neuropathy:** Median nerve lies close to brachial artery in the antecubital fossa so the risk of injuring nerve more. Peripheral neuropathy may occur in case of large hematoma and hyperextension of the wrist. Axillary plexus and nerve injury can occur in case of axillary artery cannulation.



Normal arterial pressure waveform:

- A, systolic upstroke;
- B, systolic peak pressure;
- C, systolic decline;
- D, dicrotic notch;
- E, diastolic runoff;
- F, end-diastolic pressure;

As pressure wave travels from central to periphery. The central tracing shows more rounded systolic contour and defined dicrotic notch while periphery shows high peak systolic pressure with delayed and smooth dicrotic notch. High systolic pressure, low diastolic pressure, and wide pulse pressure are observed in peripheral tracing because of high peripheral vascular resistance



One can interpret the qualitative information by observing the morphology of the waveform, such as **contractility**, **stroke volume** and **vascular resistance**. The contractility can be roughly estimated by the rate of pressure rise during systole.

Stroke volume can be represented by the area under the arterial pressure waveform from the beginning of systole to the aortic valve closure.

The heart rate, rhythm, pulse pressure can be assessed.

Decrease in systolic pressure during the positive-pressure ventilation is suggestive of hypovolemia.

Pulse pressure is estimated by subtracting diastolic pressure from systolic pressure, low pulse pressure is seen in aortic stenosis while high in aortic regurgitation and sepsis.

**THANK YOU**