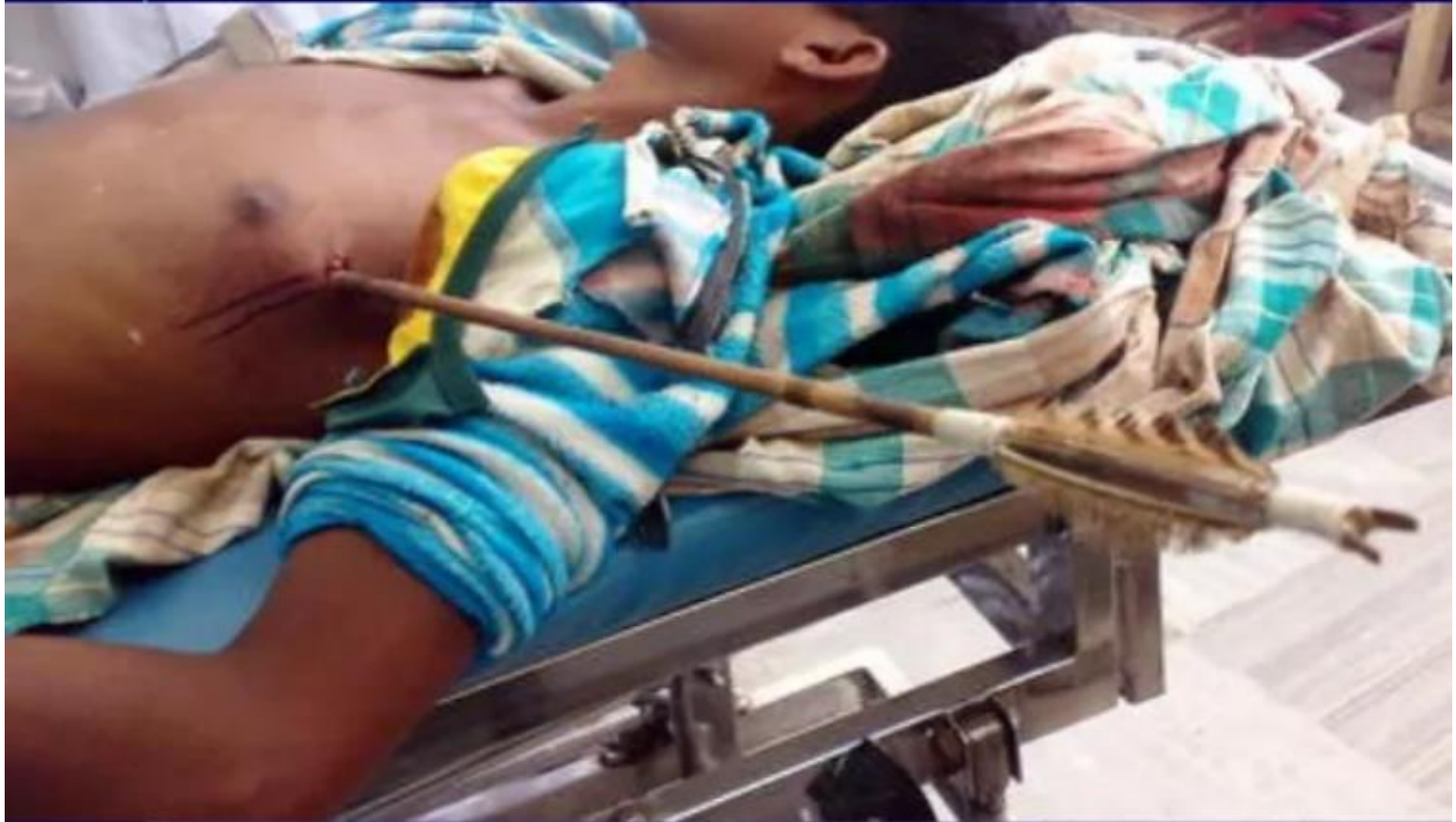

# CHEST TRAUMA

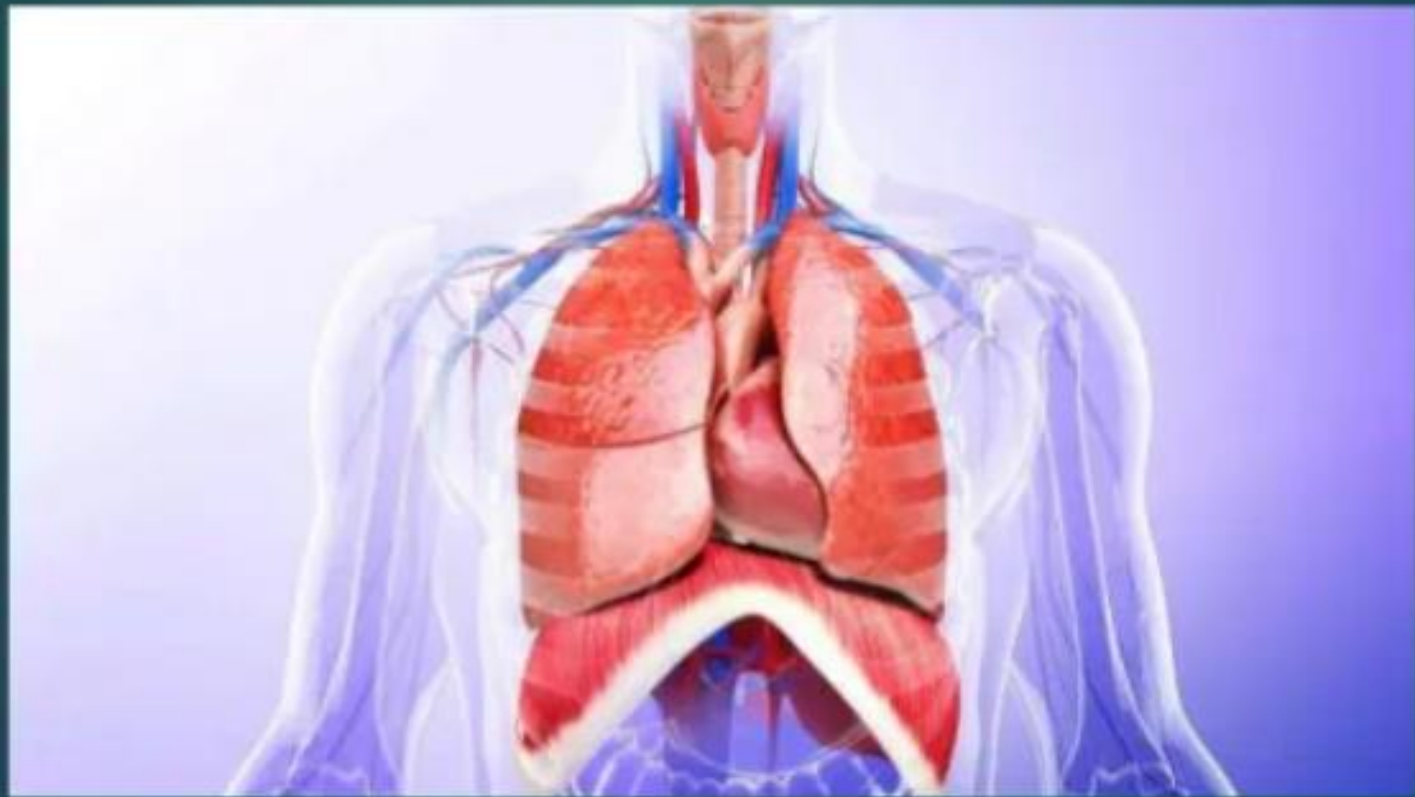



# Summary

- Introduction
- Definition
- Incidence
- Causes
- Types
- Clinical manifestation
- Diagnostic evaluation
- Management


# Introduction



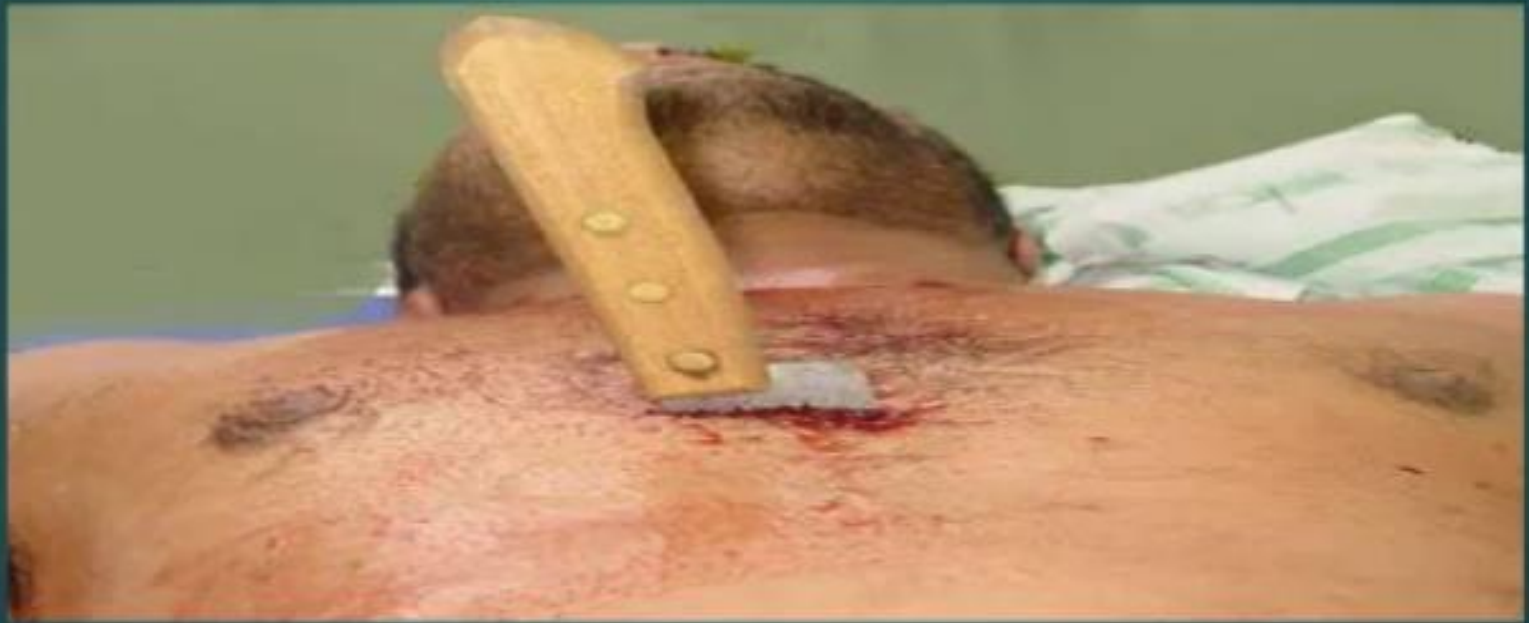# Introduction:

- Traumatic injuries to the chest contribute to 75% of all traumatic deaths.
- Thoracic injuries range from simple rib fractures to complex life-threatening rupture of organs.
- The mechanisms of injuries causing chest trauma are separated into two categories: blunt trauma and penetrating trauma.



- 
- Chest injuries are potentially life-threatening because of immediate disturbances of cardiorespiratory physiology and haemorrhage and later developments of infection, damaged lung and thoracic cage.

# Definition



# Definition:

---

- A chest injury is define as, “it is a form of injury to the chest including the ribs, heart and lungs, great vessels, trachea and esophagus.”

# Incidence



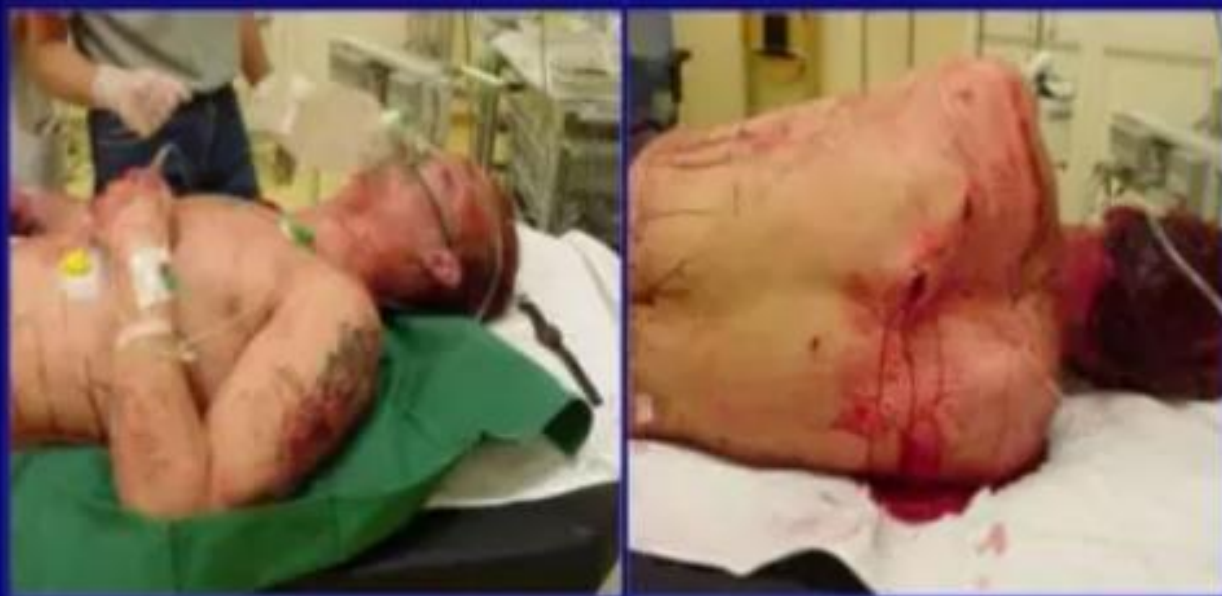

# Incidence:

---

- 25% of all death form traumatic injury.

# Causes





**Causes:**

**BLUNT INJURY  
CAUSES**

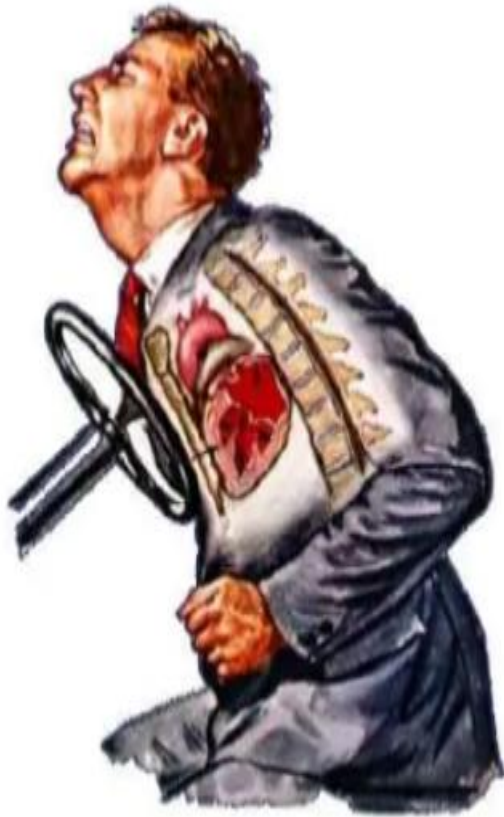**PENETRATING  
INJURY CAUSES**



## ❖ BLUNT INJURY CAUSES:

- ❑ Motor vehicle accident
  - ❑ Pedestrian accident
  - ❑ Fall
  - ❑ Sports injury
  - ❑ Assault with blunt object or Altercations
  - ❑ Crush injury
  - ❑ Explosion
-

## Blunt Trauma to the Chest

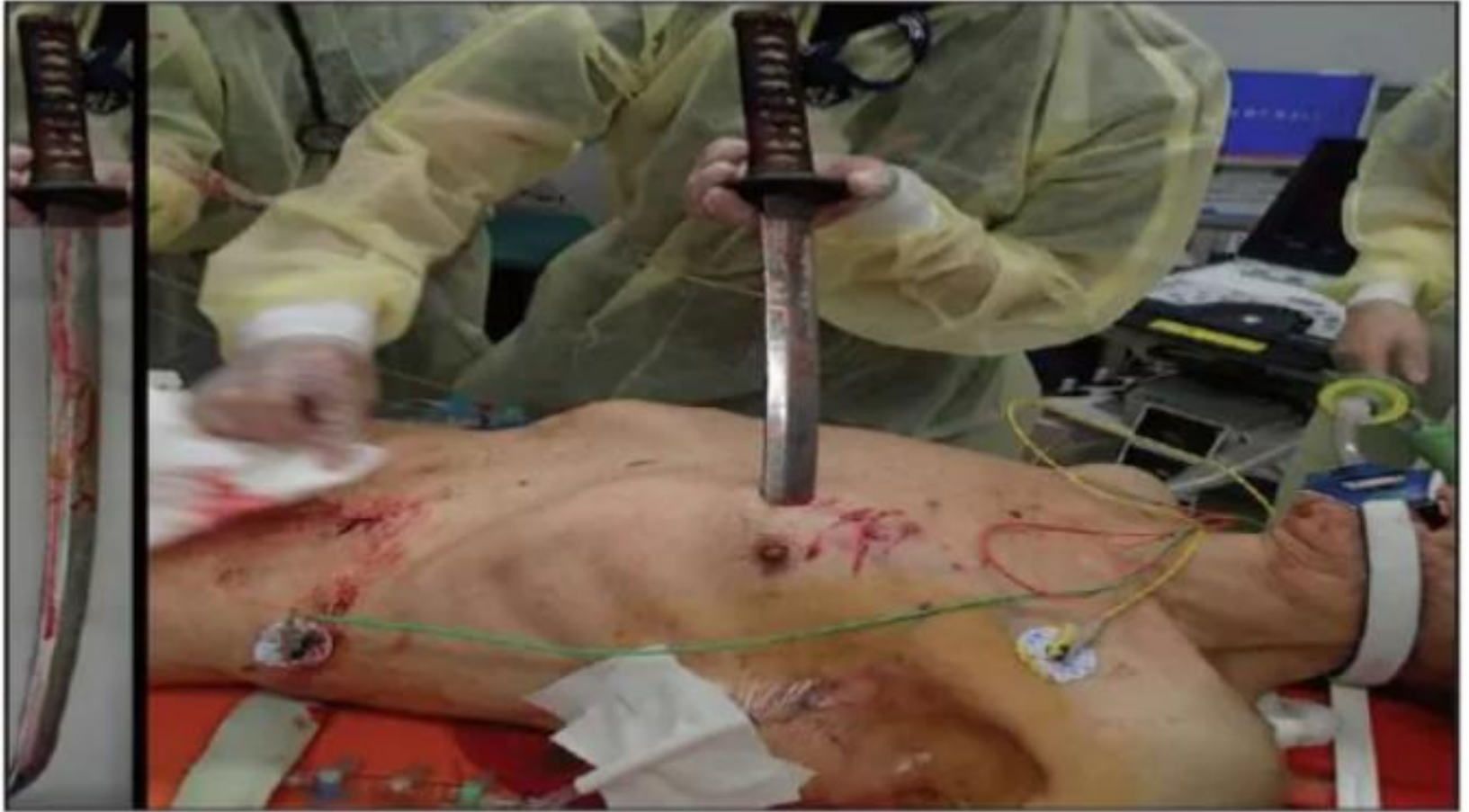





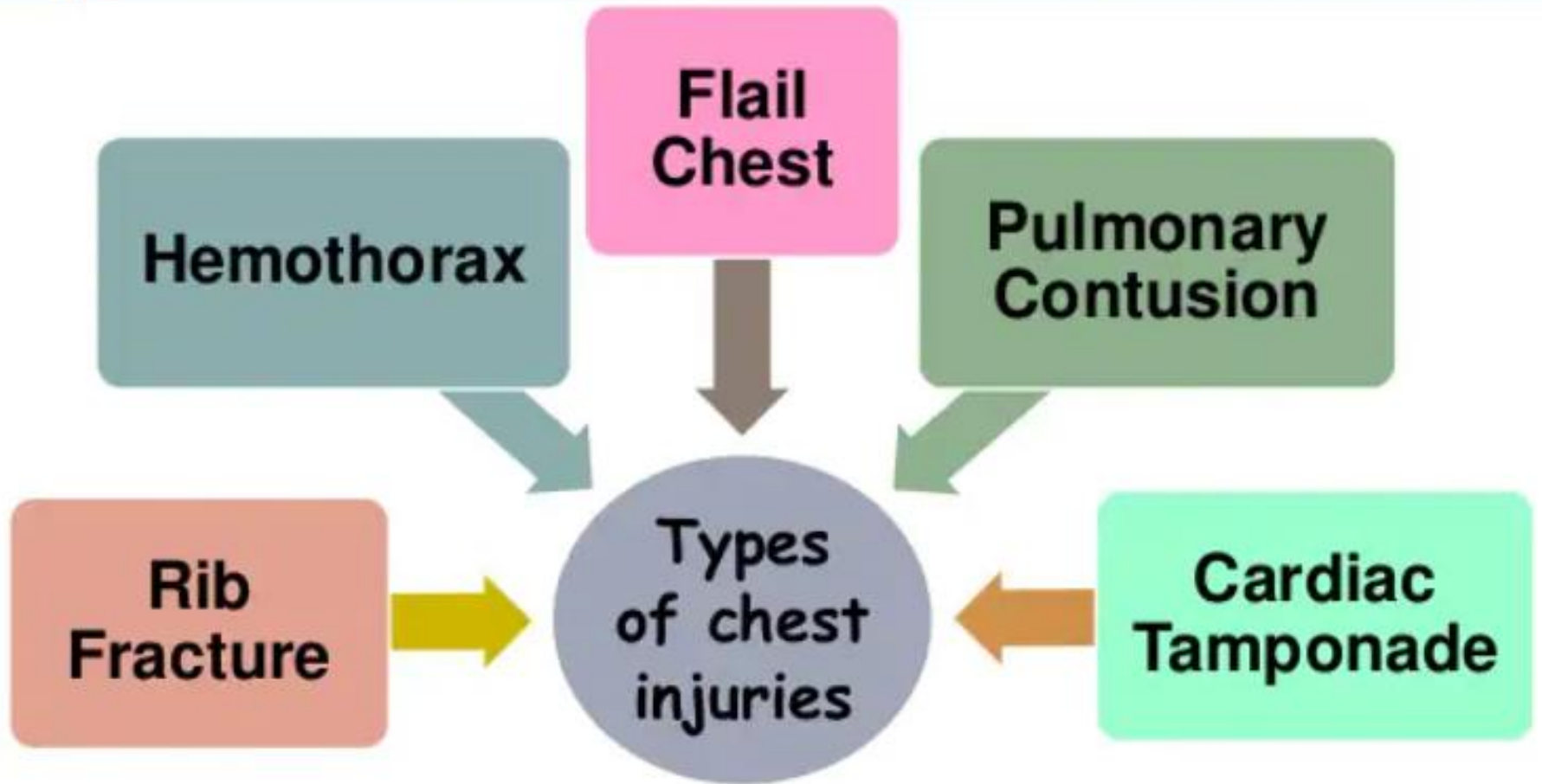
❖ PENETRATING INJURY CAUSES:

- ❑ Knife
- ❑ Gunshot
- ❑ Stick
- ❑ Arrow
- ❑ Occupational injury





# Types of chest injuries

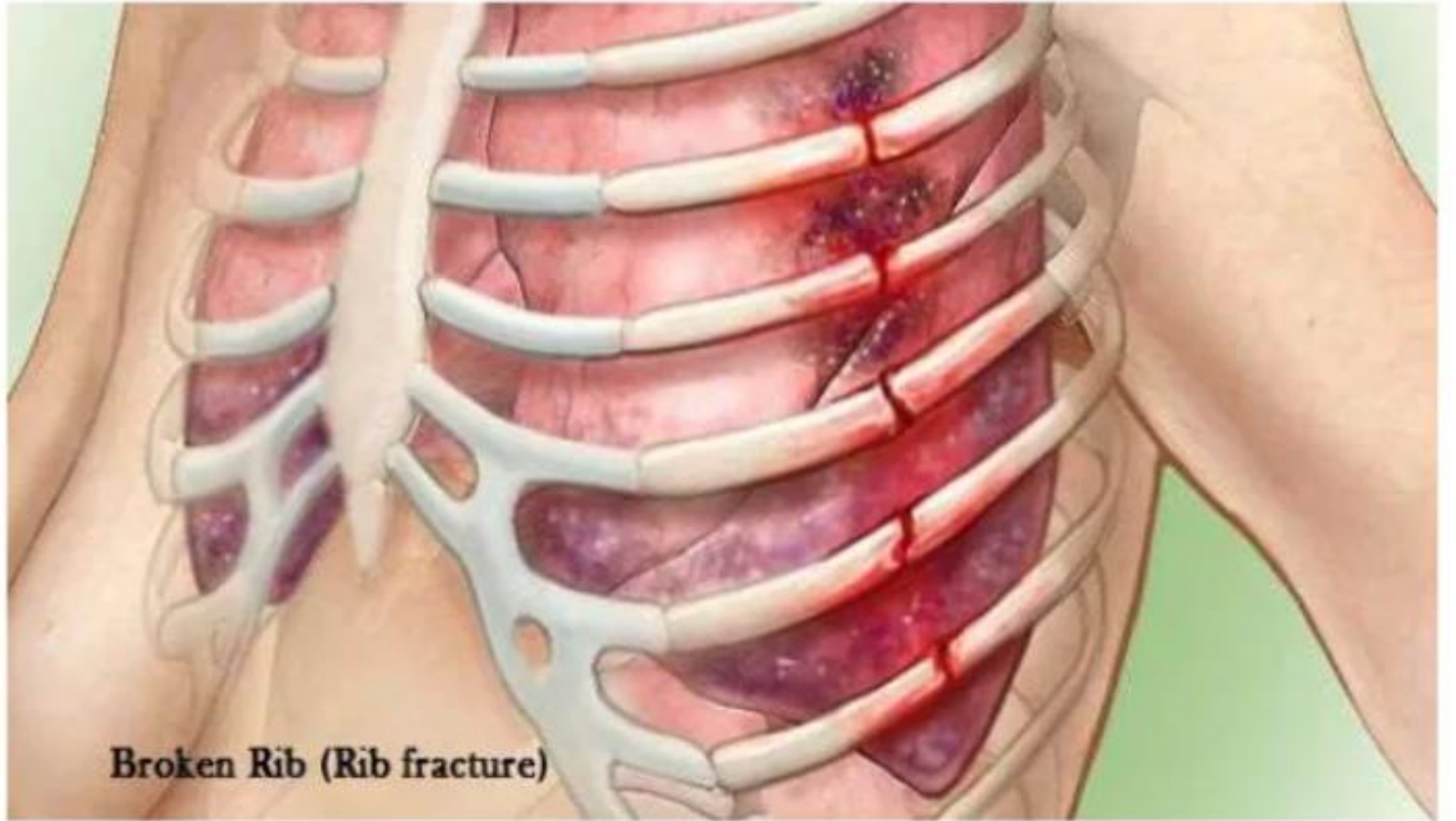


# Rib Fracture:

---

- Most common chest injury.
- May interfere with ventilation and may lacerate underlying lung.





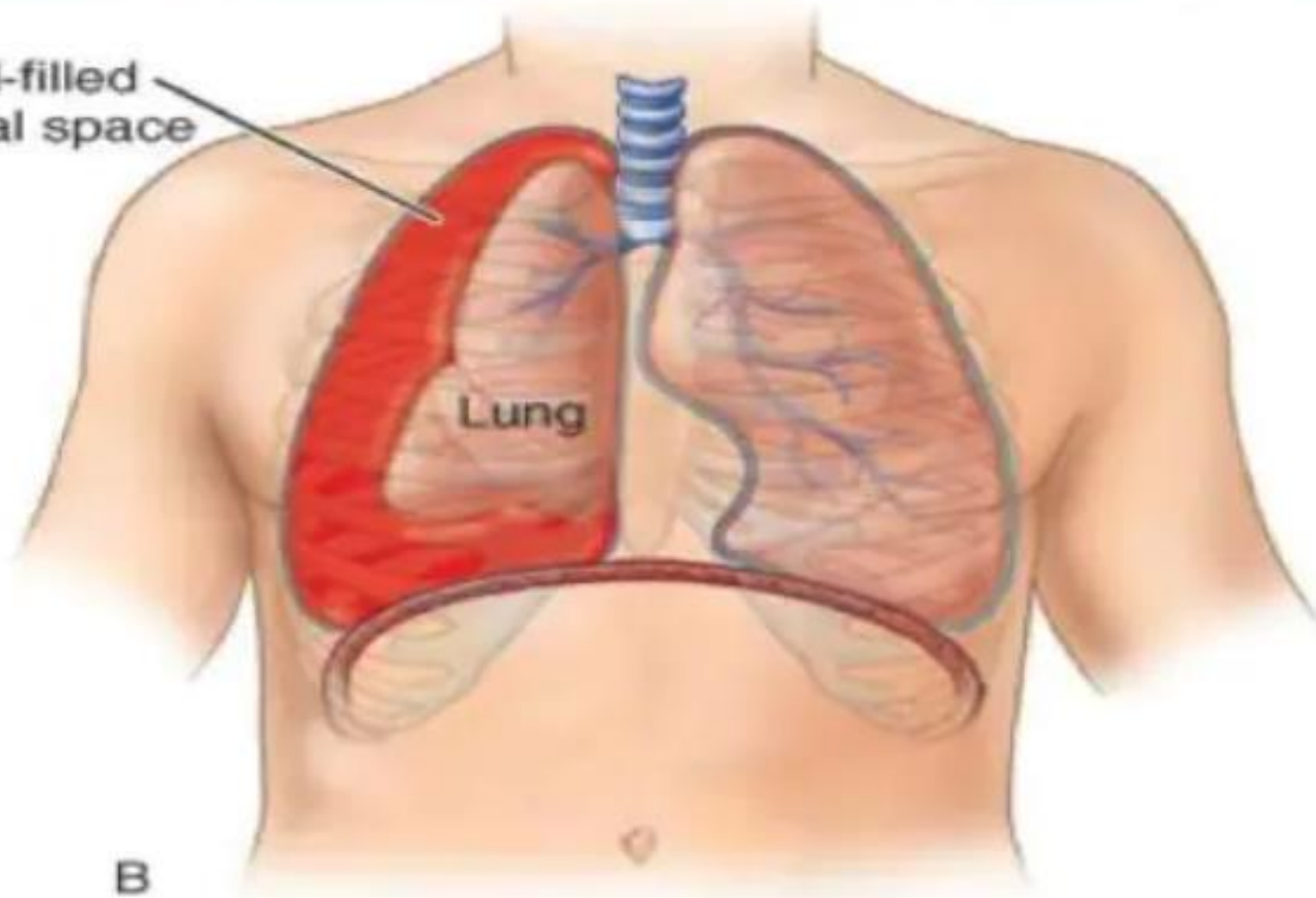
**Broken Rib (Rib fracture)**

# Hemothorax:

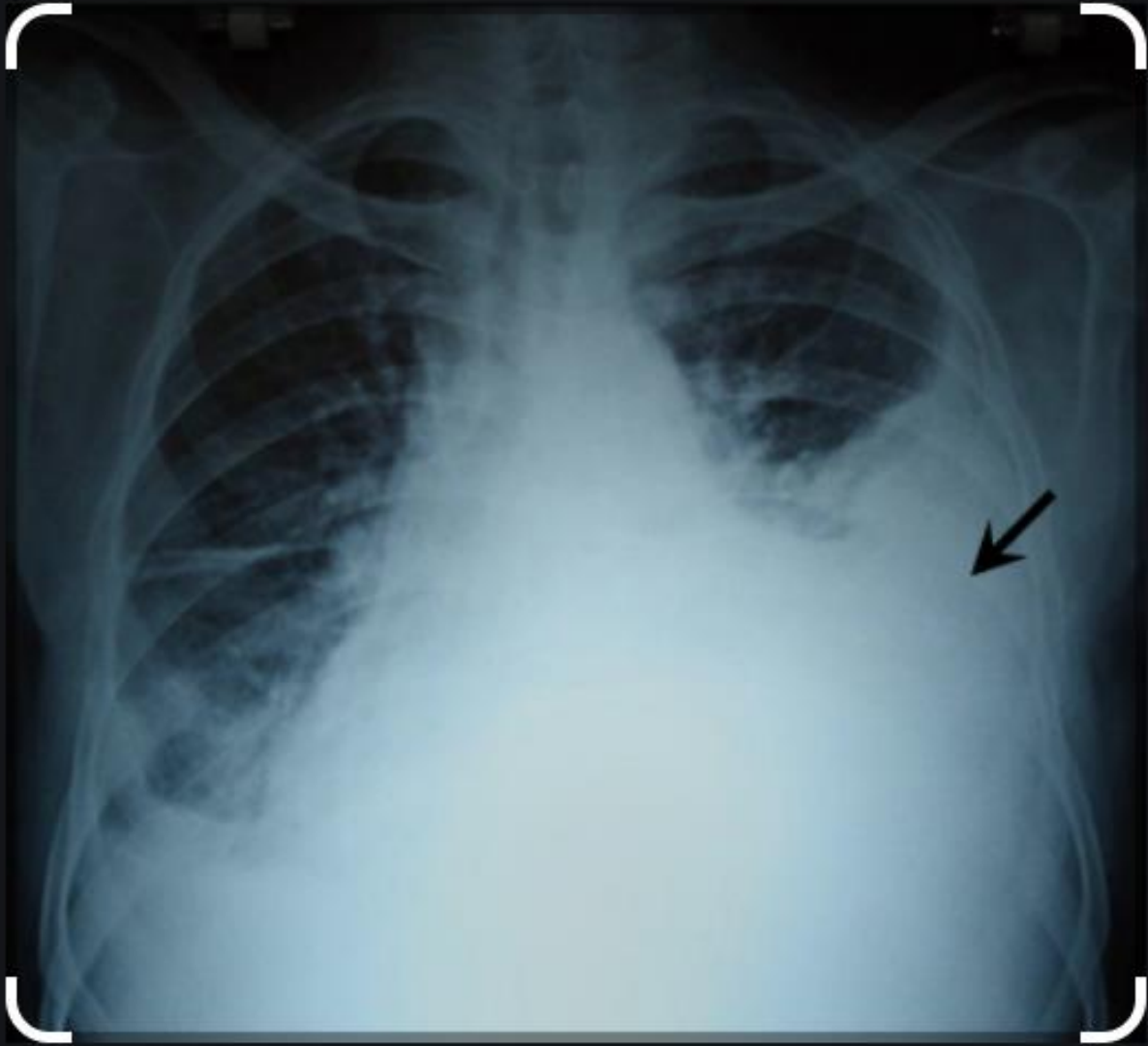
---

- Blood in pleural space as a result of penetrating or blunt chest trauma.
- Accompanies a high percentage of chest injuries.
- Can result in hidden blood loss.

Blood-filled  
pleural space



B




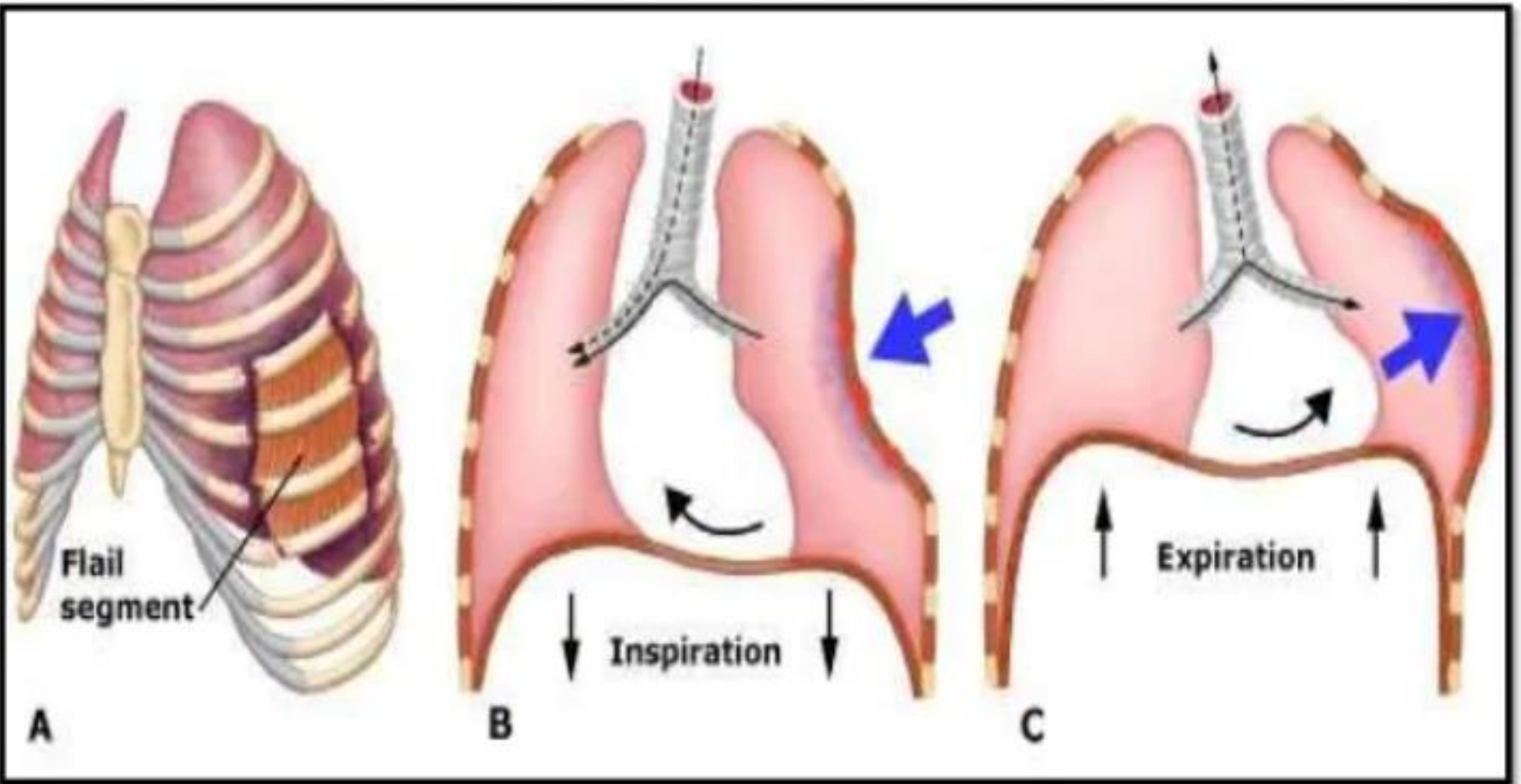
# Flail Chest:

---

- Loss of stability of chest wall as a result of multiple rib fractures, or combined rib and sternum fractures.
- When this occurs, one portion of the chest has lost its bony connection to the rest of the rib cage.



- 
- During respiration, the detached part of the chest will be pulled in on inspiration and blown out on expiration (**PARADOXICAL MOVEMENT**)
  - Normal mechanics of breathing are impaired to a degree that seriously jeopardizes ventilation, causing dyspnea and cyanosis.



# Pulmonary Contusion:

---

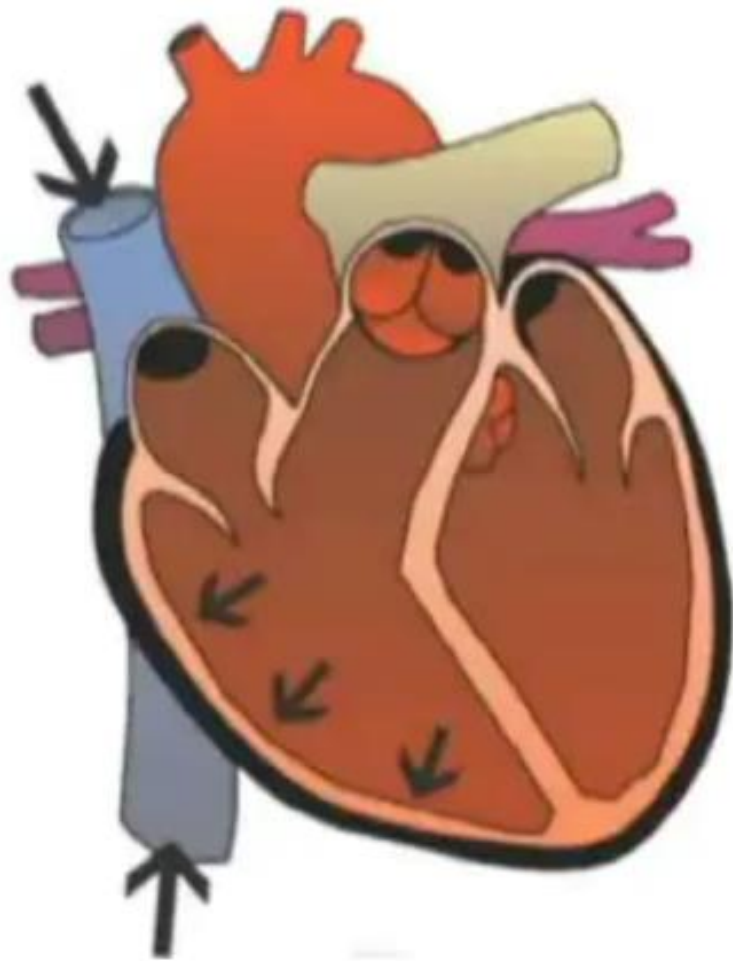
- Bruise of the lung parenchyma those results in leakage of blood and edema fluid into the alveolar and interstitial spaces of the lung.
- May not be fully developed for 24 to 72 hours.

# Cardiac Tamponade:

---

- Compression of the heart as a result of accumulation of fluid within the pericardial space.
- Caused by penetrating injuries, metastasis, and other disorders.

Healthy



Tamponade

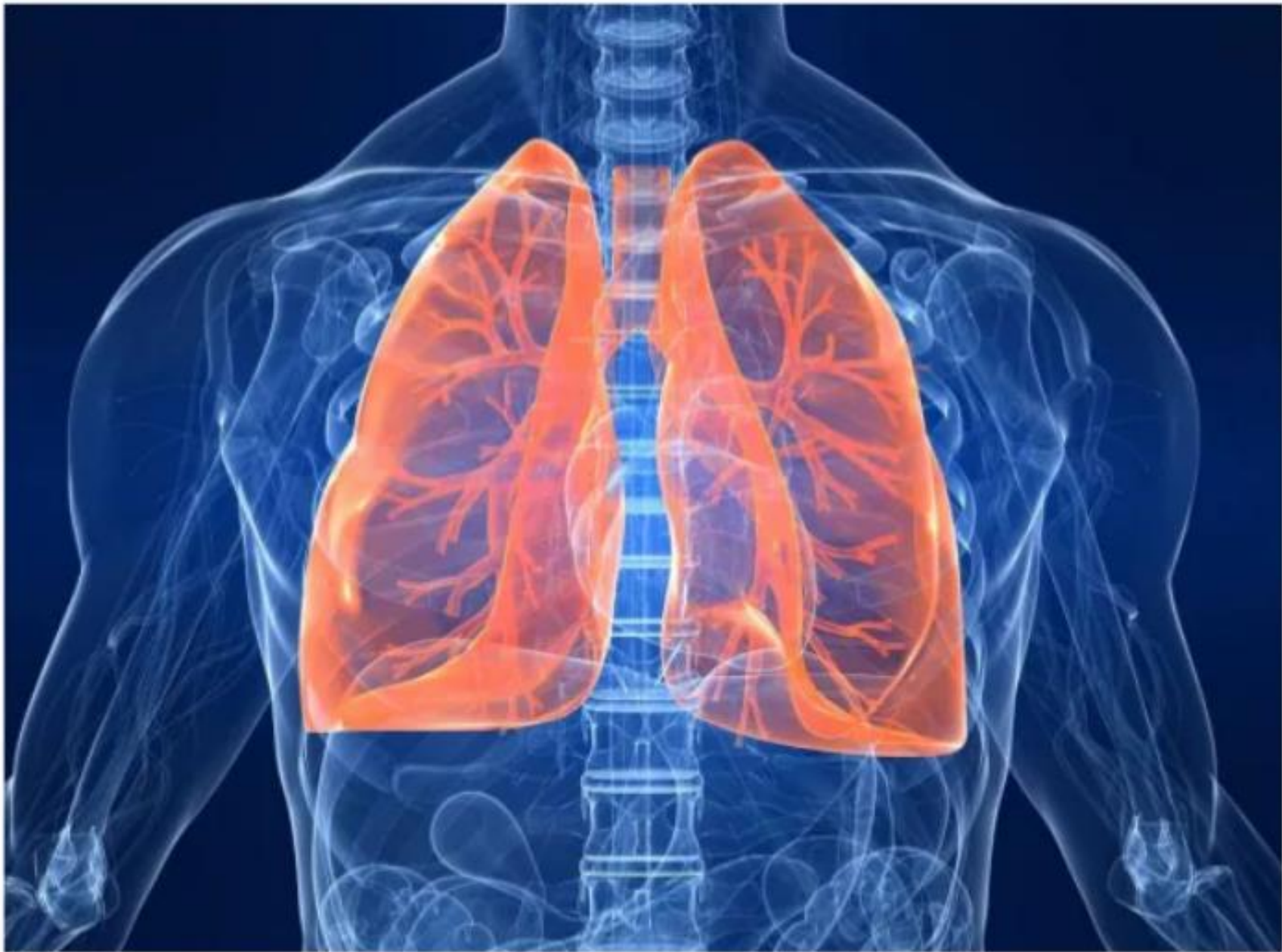



# Clinical manifestation:



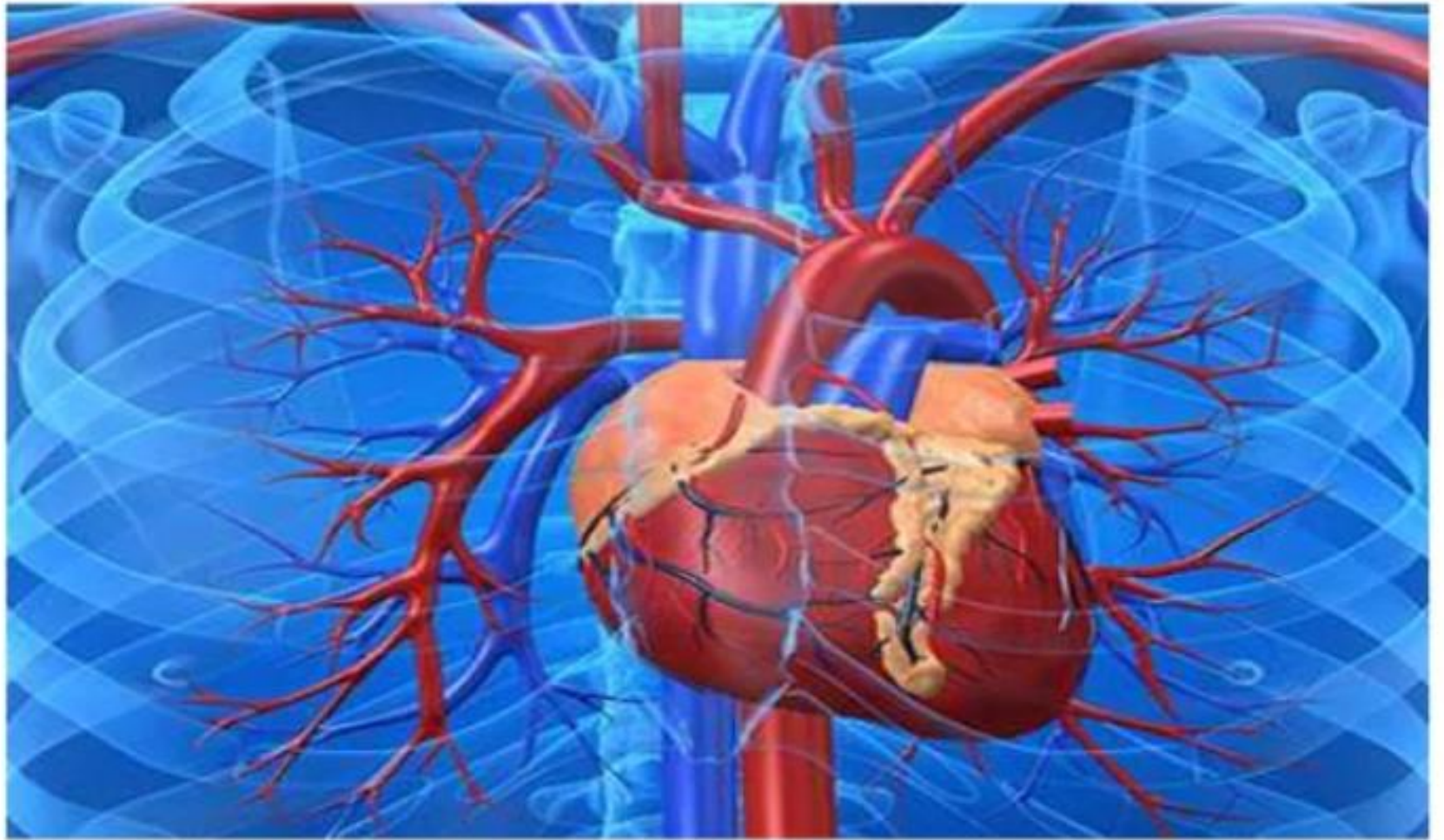



# Respiratory

---

- Dyspnea, respiratory distress
- Cough with or without haemoptysis
- Cyanosis of mouth, face, nail beds, mucous membranes
- Tracheal deviation
- Audible air escaping from chest wound
- Decreased breath sounds on side of injury
- Decreased O<sub>2</sub> saturation
- Frothy secretions






# Cardiovascular

---

- Rapid, thready pulse
- Decreased BP
- Narrowed pulse pressure
- Asymmetric BP values in arms
- Distended neck veins
- Muffled heart sounds

- 
- Chest pain
  - Crunching sound synchronous with heart sounds
  - Dysrhythmias

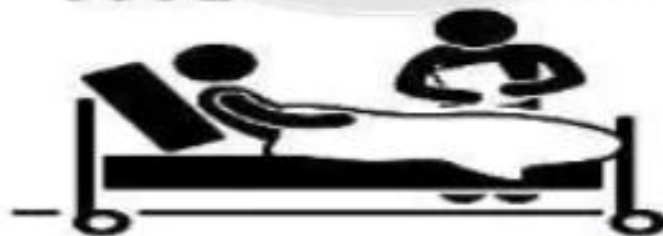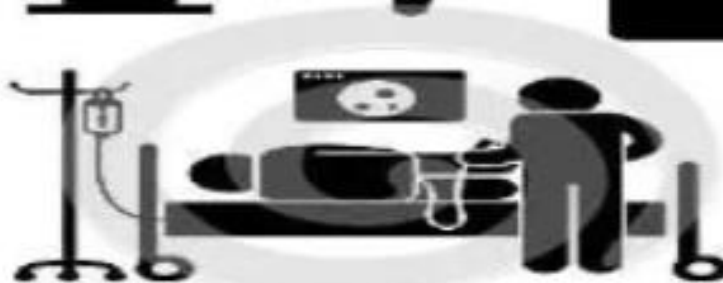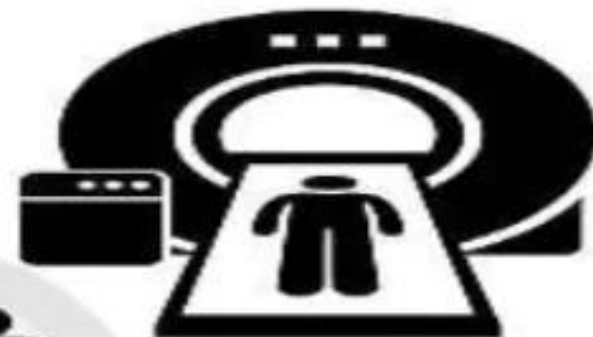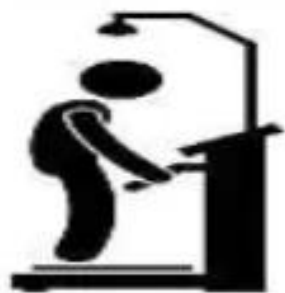# Surface Findings


---

- Bruising
- Abrasions
- Open chest wound
- Asymmetric chest movement
- Subcutaneous emphysema



# Diagnostic evaluation




- 
- **History collection**
  - **Physical examination**
  - While doing physical examination assess for abdominal tenderness, chest tenderness, chest bruising, chest swelling, decrease lung sound, wheezing, rapid pulse and rapid breathing, chest crepitation, cyanosis, dyspnea.
  - X- Ray
  - CT Scan and MRI


# Management



Personal / Commercial Use

300 dpi PNG and EPS format

- 
- The goal is to restore normal **cardiorespiratory** function as quickly as possible.
  - This is accomplished by,
    - Performing effective resuscitation
    - While simultaneously assessing the patient,
    - Restoring chest wall integrity,
    - Reexpanding the lung.

- 
- Assist with intercostal nerve block to relieve pain so coughing and deep breathing may be accomplished. An **intercostal nerve block is the injection of a local anesthetic** into the area around the intercostal nerves to relieve pain temporarily after rib fractures, chest wall injury, or thoracotomy.
  - For multiple rib fractures, **epidural anesthesia** may be used.



# Rib Fracture:

---

- Give analgesics (usually nonopioid) to assist in effective coughing and deep breathing.
- Encourage deep breathing with strong inspiration; give local support to injured area by splinting with hands.



# Hemothorax:

- Assist with **thoracentesis** to aspirate blood from pleural space, if being done before a chest tube insertion.
- Assist with **chest tube insertion** and set up drainage system for complete and continuous removal of blood and air.
  - ▣ Auscultate lungs and monitor for relief of dyspnea.
  - ▣ Monitor amount of blood loss in drainage.
- Replace volume with I.V. fluids or blood products.

# Flail Chest:


---

- Stabilize the flail portion of the chest with hands; apply a pressure dressing and turn the patient on injured side, or place 10-lb sandbag at site of flail.
- Thoracic epidural analgesia may be used for some patients to relieve pain and improve ventilation.

# Pulmonary Contusion:

---

- Employ mechanical ventilation to keep lungs inflated.
- Administer diuretics to reduce edema.
- Correct metabolic acidosis with I.V. sodium bicarbonate.
- Use PAP monitoring.
- Monitor for development of pneumonia.

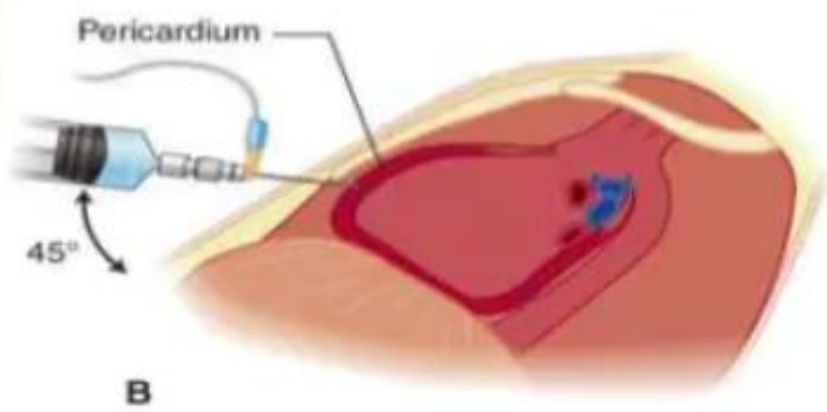
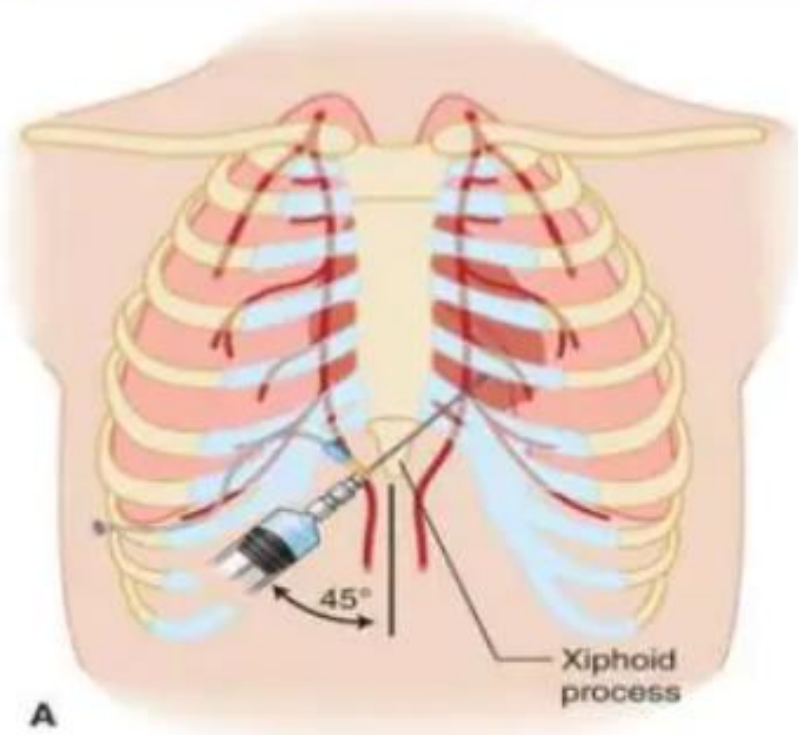
- 
- If respiratory failure is present, prepare for immediate **ET intubation** and mechanical ventilation treats underlying pulmonary contusion and serves to stabilize the thoracic cage for healing of fractures, improves alveolar ventilation, and restores thoracic cage stability and intrathoracic volume by decreasing work of breathing.
  - Prepare for **operative stabilization** of chest wall in select patients.

# Cardiac Tamponade:

---

- Assist with pericardiocentesis to provide emergency relief and improve hemodynamic function until surgery can be undertaken.
- Prepare for emergency thoracotomy to control bleeding and to repair cardiac injury.






Source: J.E. Tintinalli, J.S. Stapczynski, O.J. Ma, D.M. Yealy, G.D. Meckler, D.M. Cline:  
Tintinalli's Emergency Medicine: A Comprehensive Study Guide, 8th Edition  
www.accessmedicine.com  
Copyright © McGraw-Hill Education. All rights reserved.





# ADDITIONAL RESPONSIBILITIES:


---

- Secure and support the airway as indicated.

- 
- Prepare for tracheostomy if indicated.
    - ▣ Tracheostomy helps to clear tracheobronchial tree, helps the patient breathe with less effort, decreases the amount of dead airspace in the respiratory tree, and helps reduce paradoxical motion.
    - ▣ When used with mechanical ventilation, provides a closed system and stabilizes the chest.

- 
- Secure one or more I.V. lines for fluid replacement, and obtain blood for baseline studies, such as hemoglobin level and hematocrit.
  - Monitor serial CVP readings to prevent hypovolemia and circulatory overload.
  - Monitor ABG/Spo<sub>2</sub> results to determine need for supplemental oxygen, mechanical ventilation.

- 
- Obtain urinary output hourly to evaluate tissue perfusion.
  - Continue to monitor thoracic drainage to provide information about rate of blood loss, whether bleeding has stopped, whether surgical intervention is necessary.
-

- 
- Institute ECG monitoring for early detection and treatment of cardiac dysrhythmias (dysrhythmias are a frequent cause of death in chest trauma).



- Maintain ongoing surveillance for complications:
  - Aspiration
  - Atelectasis
  - Pneumonia
  - Mediastinal/subcutaneous emphysema
  - Respiratory failure

Thank You!!!

