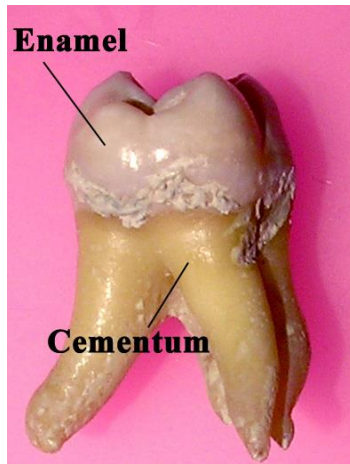


Enamel:



Enamel(E.)

1. is **the hardest calcified tissue in the human body.**
2. It is an ectodermal in origin ,
3. protective covering the crown of the teeth.
4. The cells that formed it called Ameloblasts **which are lost as the tooth erupts in the oral cavity, and so the E, can not renew it self after destruction.**

-Physical characteristics of E.:

1. E, is extremely hard, because of its high mineral content a property that enables it to withstand the mechanical forces applied during mastication.
2. The structure and hardness of the E. render it brittle, which is particularly apparent when the E. loses it's foundation of sound dentin. If this supportive layer of D. is destroyed by caries or improper cavity preparation, **the unsupported E, fractured easily.**
3. E- is translucent, it reflect the color of underlying D. It varies in color from light yellow to gray white

4. It also varies in thickness, from 2.5mm over the cusp tip and incisal region to the **knife edge at cervical region**.

5. E, is permeable, but its permeability depends on the age of the human. Its permeability is higher in children than in the adult, so the **E. can take fluoride ions that fuse with hydroxyapatite crystals** forming **fluorapatite crystals** and give more resistance to the tooth in children.

Chemical composition:

E. consists mainly **96% inorganic** and **4% organic material and water**. The inorganic content is a crystalline calcium phosphate (hydroxyapatite) which is also found in bone, dentine and cementum as in this **formula $\text{Ca}_{10}(\text{PO}_4)_6(\text{OH})_2$** . The organic materials of the E. are amelogenin and enamel proteins.

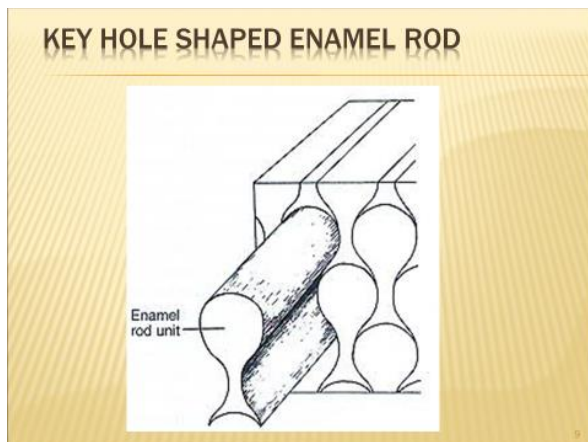
Structure of the E

The basic unit of E- that is composed of E. rod or prism, rod sheath, and inter-rod substance.

- E. is built from closely packed hydroxyapatite crystals measuring 60-70nm in width and 25-30nm in thickness which are arranged in E. rods or prisms. It is believed that the length of the crystals spans the entire thickness of the E. layer.
- The E. rod is shaped like a cylinder and is made up of crystals with long axes that run parallel to the longitudinal axis of the rod,
- **Each E. rod is formed by 4 ameloblasts** and each rod runs from DEJ to the E. surface.
- The direction of E- rod is wavy or oblique so the length of the E. rod is greater than the thickness of E.
- The No. of E. rod is about **5 millions in the lower lateral incisor** and **12 millions in the upper first molars**.
- The rod appears as a **key hole** in **longitudinal section**. Each key hole consists of head and tail, head represents rod and tail represents the inter-rod region.

Head of the key hole is at occlusal or incisal regions and the tail is at the cervical direction. While in **cross section the E. rod appear as hexagonal, or oval, or round , or sometimes as fish-scale appearance.**

- The direction of E. rods in cuspal and incisal areas are vertical but as soon as progress to the cervical part of the crown, they became oblique and then horizontal and finally they Inclined apically.
- Rod sheath it represent the organic matrix(4%) of the E. It surround the head of E, rod, but not completely encircle it, only $\frac{2}{3}$ of it- Rod sheath develops due to irregular arrangement of the crystals and its less calcified than E, rod. So dental caries when first attack the E., they invade the rod sheath,
- The inter rod substance is a region between 2 rods and it represent the tail ,and its crystals are oriented in direction different from those making up the rod.



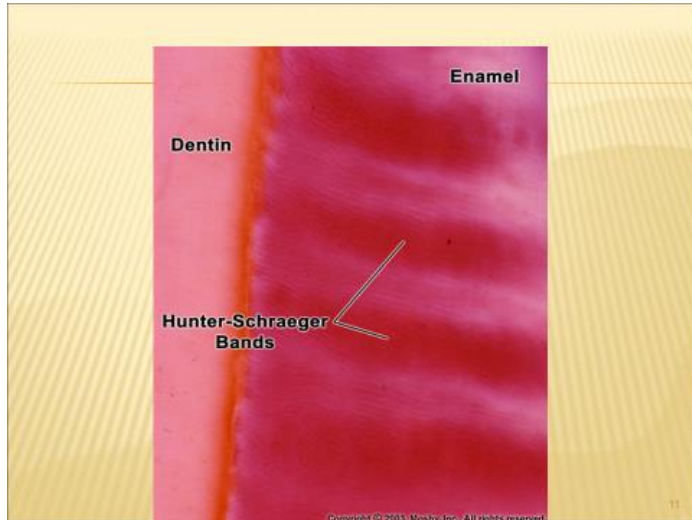
Gnarled E:

It's the **hardest type of E. present in the crown to with stand the force of mastication applied on the cusps and the incisal edge.** The direction of E. Rods is much complicated in the E, of the cusp tips and the incisal edge. At these regions the **E- rods are interwine more irregularly** as an optical appearance.

Hunter- Schreger bands:

They are **an optical phenomenon produced by changes in the direction between adjacent groups of rods.** These bands are seen most clearly in

longitudinal ground section viewed by reflecting light and are found in the inner $\frac{2}{3}$ of the E, These bands appear as dark and light alternating zones.



Hypocalcified structures in E :

1. E. tufts

They are best seen in the transverse ground section of the tooth. E. tufts project from DEJ for a short distance into the E, They appear to be branched and contain greater concentrations of E. protein than the rest of the enamel E, tufts are believed to occur developmentally because of **abrupt changes in the direction of E. rods.**


2. E. lamellae

extend for varying depths from the surface of E. and consist of linear longitudinally oriented defects filled with organic materials. So it represent a **site of weakness in the tooth** and may act as a way for the iteration of bacteria that initiate dental caries,

3.E. spindle

Its a finger- like extensions arise from DEJ into E, about few micron length, they represent extensions of the odontoblastic process of dentinal

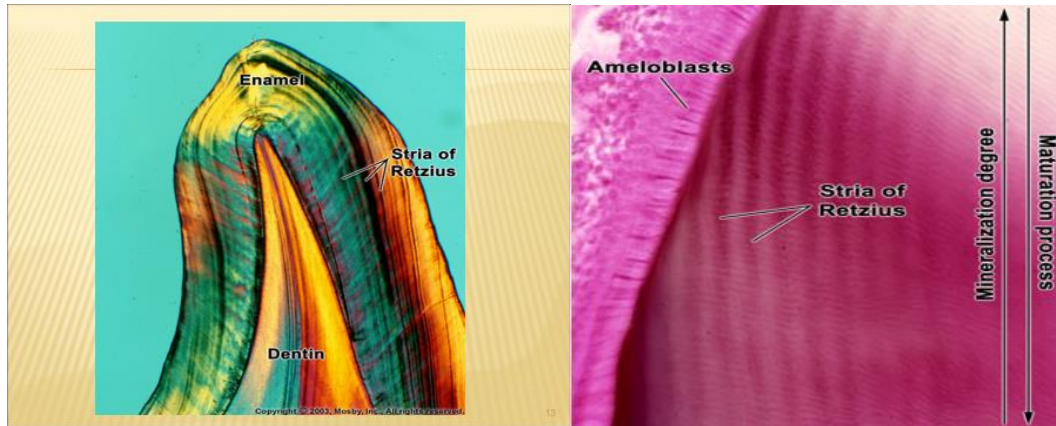
tubules that penetrate the DEJ and because D. formed before E. So these odontoblastic process penetrates the junction and then E- formed around it and so these **spindle represent the only mesenchymal structure in E.**



Incremental lines of the E:

1- Striae of Retzius:

They are identity in ground section of the teeth. **In longitudinal ground section, they are seen as a series of dark or brown lines extending from DEJ toward tooth surface.** While in cross ground section they appear as concentric rings. Although Striae of Retzius generally are ascribed to a weekly rhythm in E. production resulting in a structural alteration of rod, the basis for their production is still not clear.



2-Cross. striation:

They are fine growth lines seen in ground section of E. In longitudinal section the rods appear segmented by these periodic bands or cross striations. These striations **indicating that the E. matrix is formed by periodic manner of ameloblasts at about 4 micrometer per day.**

3-Neonatal line;

Its an enlarged striae of retzius that apparently reflects the great physiologic changes occurring at birth. So these **lines demarcating the boundary between E. formed before and after birth.**