



Medical Laboratory Techniques Department

Lab 2 : Protozoa

Phylum: Protozoa : Protozoa classes in to a-Amebas , b-Flagellates
c-Ciliates , d-Sporozoa

Class : Sarcodina (Amoebae)

Introduction:

Amoebae , primitive unicellular microorganisms with a relatively simple life cycle which **can be divided into two stage:**

-**Trophozoite :** actively motile feeding stage.

-**Cyst :** quiescent , resistant , infection stage.

* Motility is accomplished by extension of pseudopodia (false foot).

1-Entamoeba histolytica (Amoebiasis)

Morphological Feature:

a)Trophozoite :Viable trophozoite is vary in size, motility is rapid, progressive and unidirectional, through psedopoda.

b) Cyst :Intestinal infections occur through the ingestion of a mature quadrinucleate cyst.

Laboratory diagnosis :

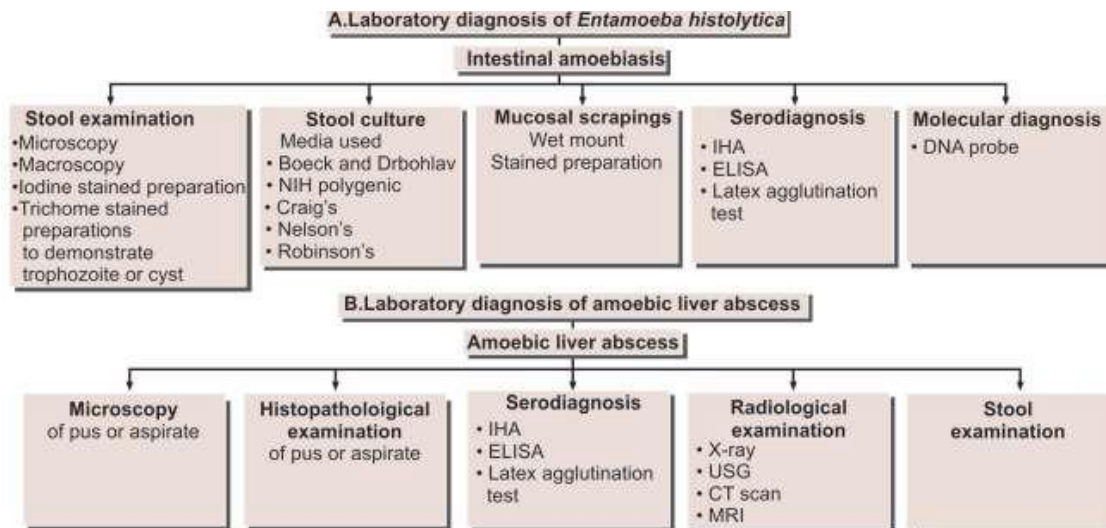
Examination of a fresh dysenteric faecal specimen. In the case of dysentery, however, RBC may be visible in the cytoplasm, and this feature is diagnostic for E. histolytica.

-Causes → amoebiasis disease.

-Habitat → large intestine.

-Mode of transmission→ Man acquires infection by swallowing food and water contaminated with cysts.

-Infection stage → mature cyst.



2-*Entamoeba coli* (non-pathogenic)

It is considered to be a **nonpathogenic** with worldwide distribution. That frequently exists as a **commensal parasite** in the human gastrointestinal tract

Morphological Features:

a) **Trophozoite** : Typically the movements of trophozoite are sluggish, with broad short pseudopodia and little locomotion.

b) **Cyst** : The mature cyst (with more than four nuclei) having **(1-8) nuclei** is the distinctive stage to differentiate *E. coli* from the pathogenic *E. histolytica*.

-Habitat → large intestine

-Infection stage → mature cyst

-Mode of infection → ingested food or water contaminated with cyst

-Sample → stool

-Diagnostic stage → cyst , trophozoite in stool.

3-*Entamoeba gingivalis*

E. gingivalis occurring both in the mouth and in the genital tract.

Nonpathogenic , there is **no clinical symptoms** during and after infection by this parasite.

Cyst formation is not present, only the trophozoites are formed

-Habitat → gum.

-Infection stage → trophozoite.

-Mode of infection → **1.** contracted via mouth to mouth (kissing) . **2.** droplet contamination . **3.** sex intercourse. **4.** by use of (IUDS) = intrauterine devices . which may be **5.** transmitted through contaminated drinking utensils.

-Sample → swab from the margins of the gum.

-Diagnostic stage → trophozoite.

Laboratory diagnosis: Examination of **1.** mouth scraping, particularly from the gingival area. Also material from the **2.** tonsillar crypts **3.** pulmonary abscess as well as sputum may also be examined. In addition the examination of **4.** vaginal / cervical material may be performed to diagnose *E.gingivalis* present in the vaginal / cervical area.

4. Naegleria Fowleri: It is the only species of genus *Naegleria*, which infects man. *N. fowleri* causes the disease primary amoebic meningeal encephalitis (PAM), a brain infection that leads to destruction of brain tissue

Morphology of *N. fowleri* occurs in 3 forms: 1. Cyst 2. Amoeboid trophozoite form 3. Flagellate trophozoite form.

The life cycle of *N. fowleri* is completed in the external environment.

Laboratory Diagnosis: The diagnosis of PAM is based on the finding of motile *Naegleria* trophozoites in wet mounts of freshly-obtained CSF. Cysts are not found in CSF or brain.

5- Acanthamoeba Species

Morphology *Acanthamoeba* exists as active trophozoite form and a resistant cystic form. *After inhalation of aerosol or dust containing trophozoites and cysts, the trophozoites reach the lungs and from there, they invade the central nervous system through the blood stream, producing **granulomatous amoebic encephalitis (GAE)**.

-Causes → **(GAE):** It is a serious infection of the brain and spinal cord that typically occurs in persons with a compromised immune system. GAE is believed to follow inhalation of the dried cysts.

-Mode of transmission → Human beings acquire by inhalation of cyst or trophozoite , ingestion of cysts, or through traumatized skin or eyes.

-Infection stage → Both trophozoites and cysts are infective.

Laboratory Diagnosis ***Diagnosis of amoebic keratitis** :is made by demonstration of the cyst in corneal scrapings by wet mount, histology and culture. Growth can be obtained from corneal scrapings inoculated on nutrient agar, overlaid with live or dead *Escherichia coli* and incubated at 30°C.

***Diagnosis of GAE** :is made by demonstration of trophozoites and cysts in brain biopsy, culture, and immunofluorescence microscopy using monoclonal antibodies. CSF shows lymphocytic pleocytosis, slightly elevated protein levels, and normal or slightly decreased glucose levels. CT scan of brain provides inconclusive findings