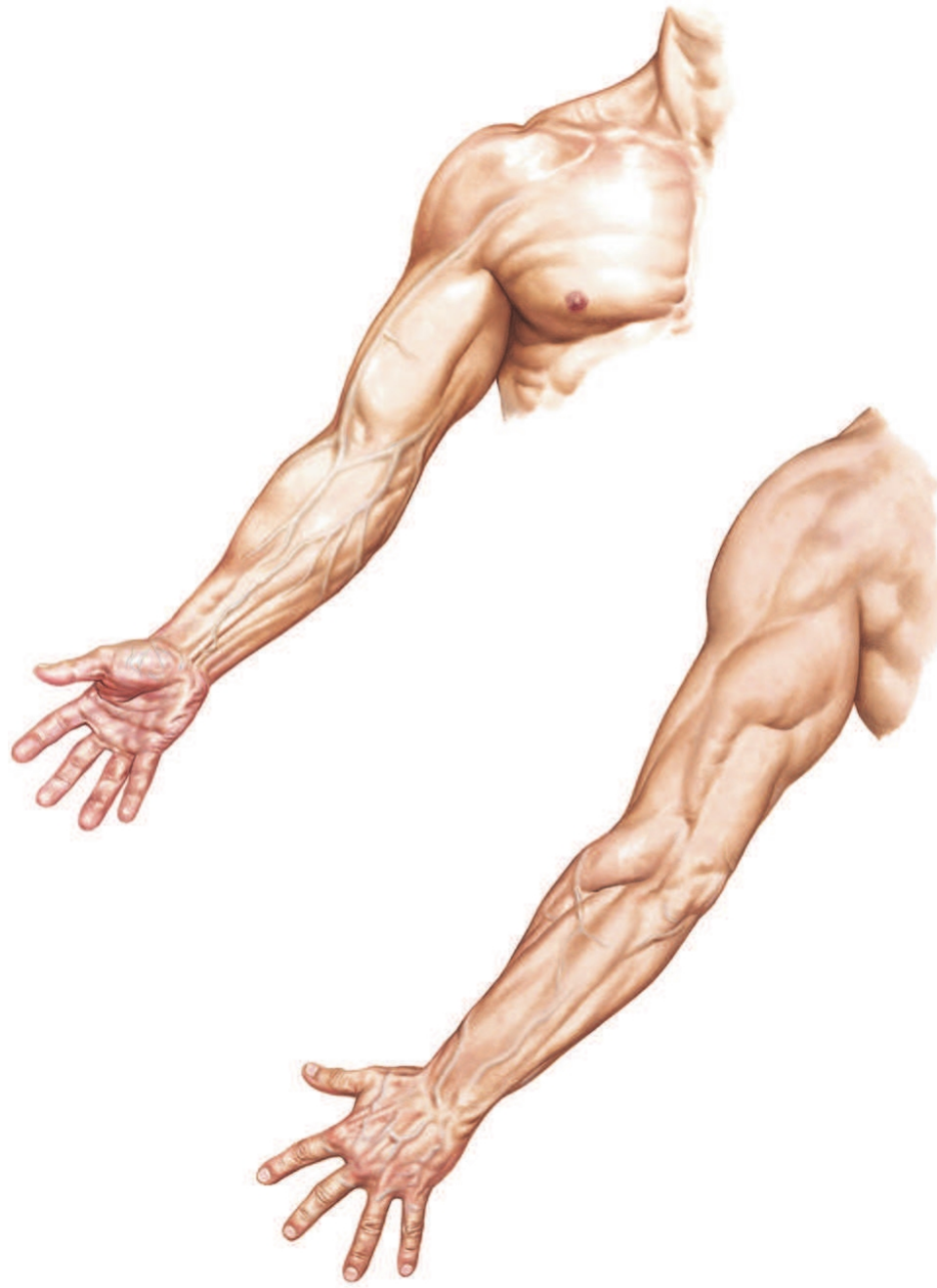


Al-Mustaqbal university college

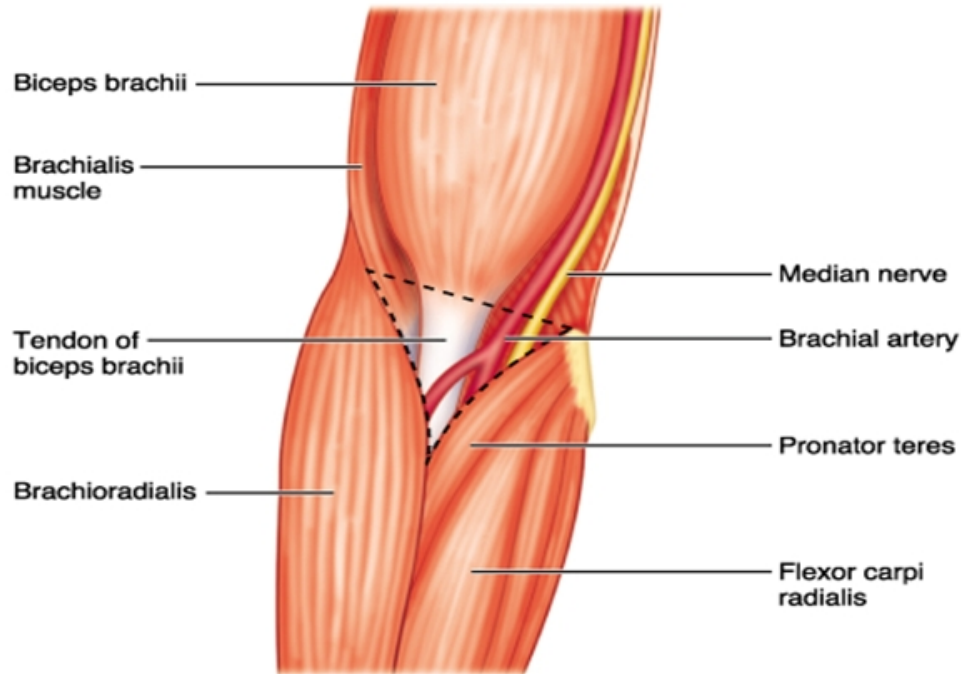
Practical anatomy lab.3: Upper limb anatomy

Ahmed Yusif Ajam
(M.B.Ch.B)

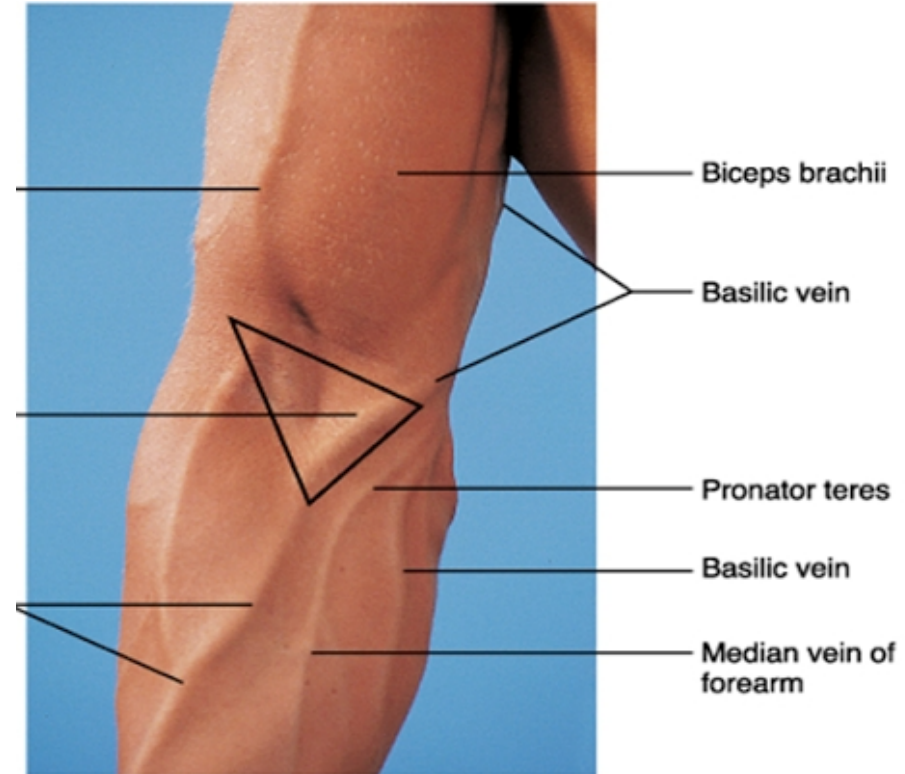
Surface



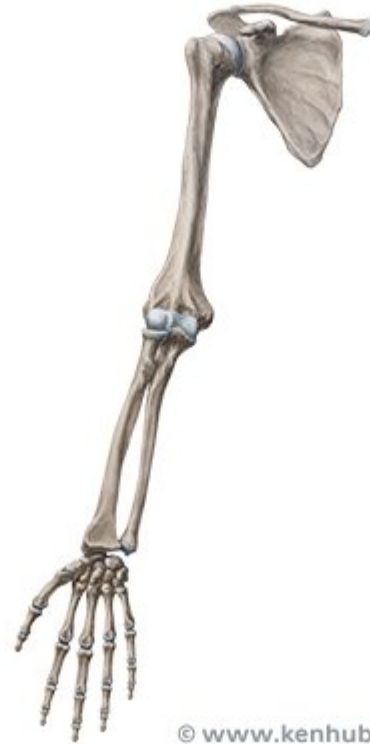Cubital fossa



(b)



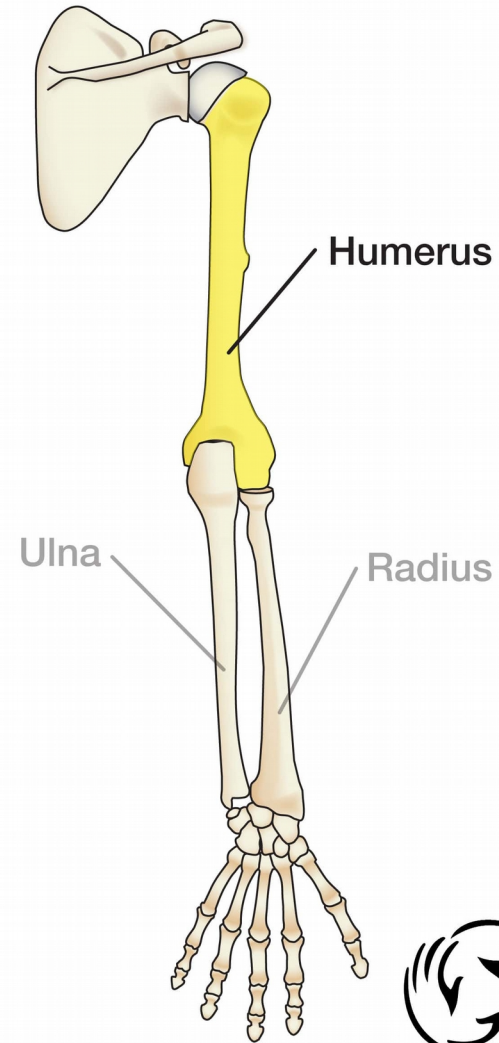
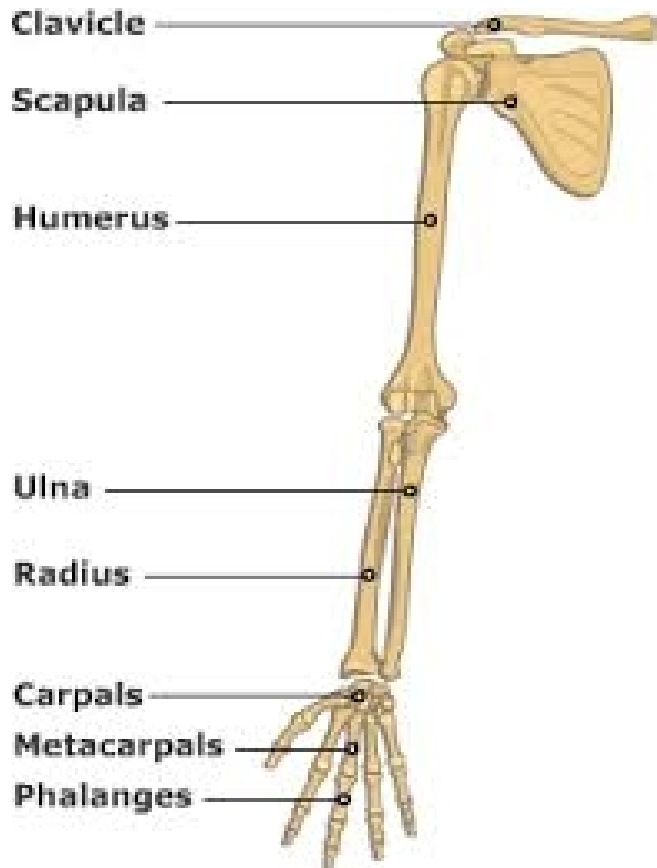
Bones



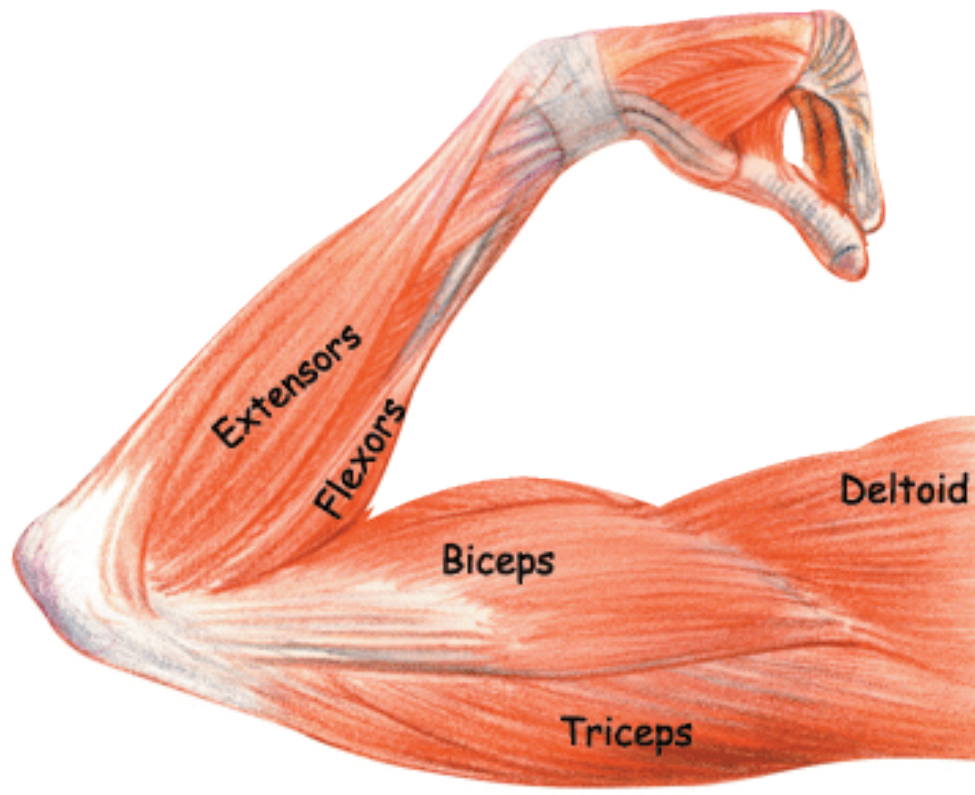
© www.kenhub.com



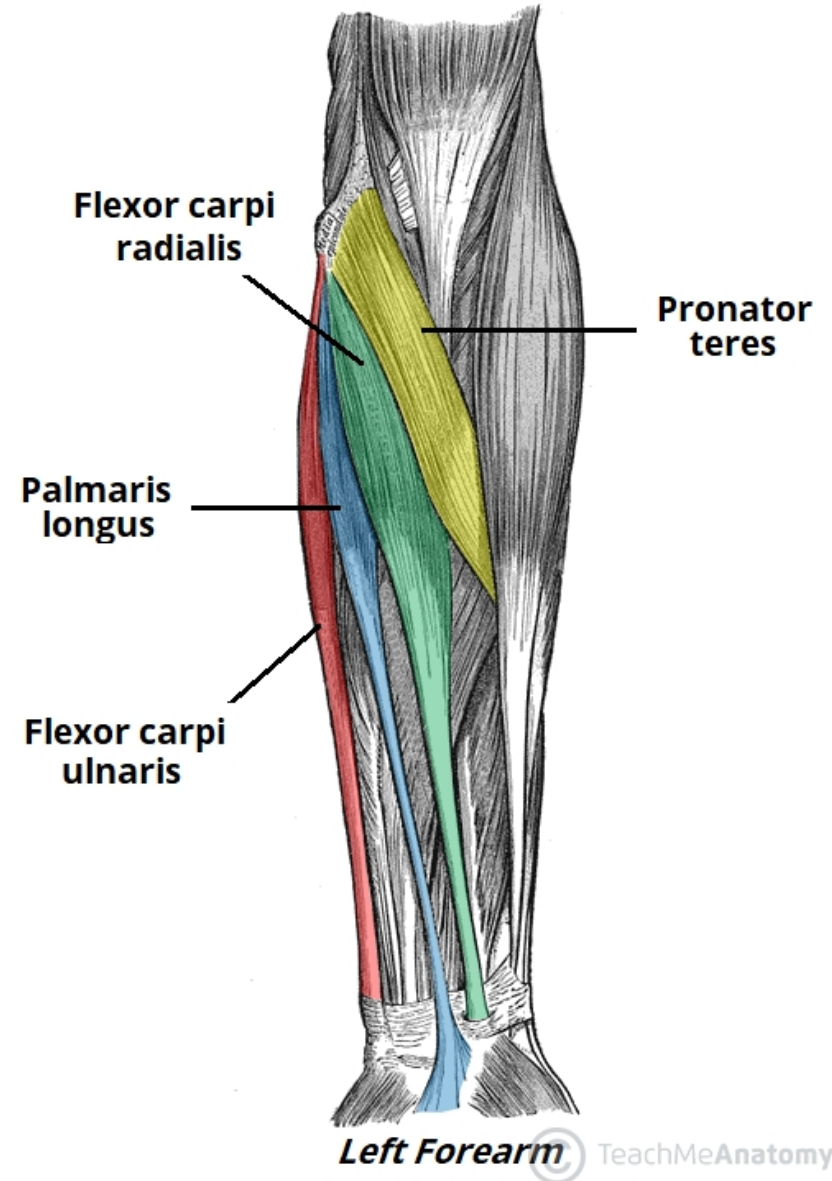
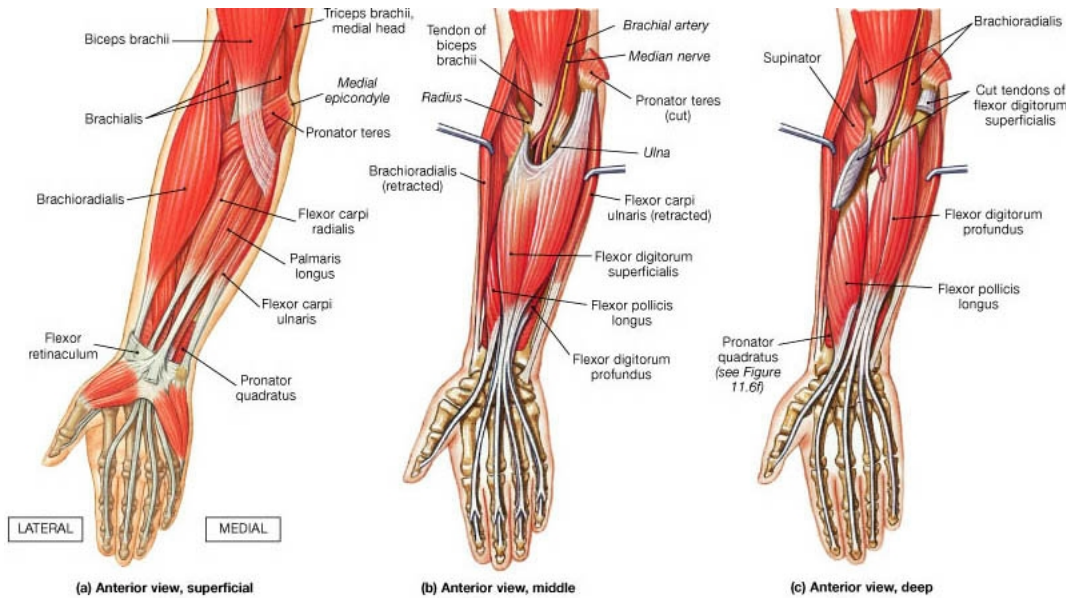
Skeleton of upper limb



Muscles

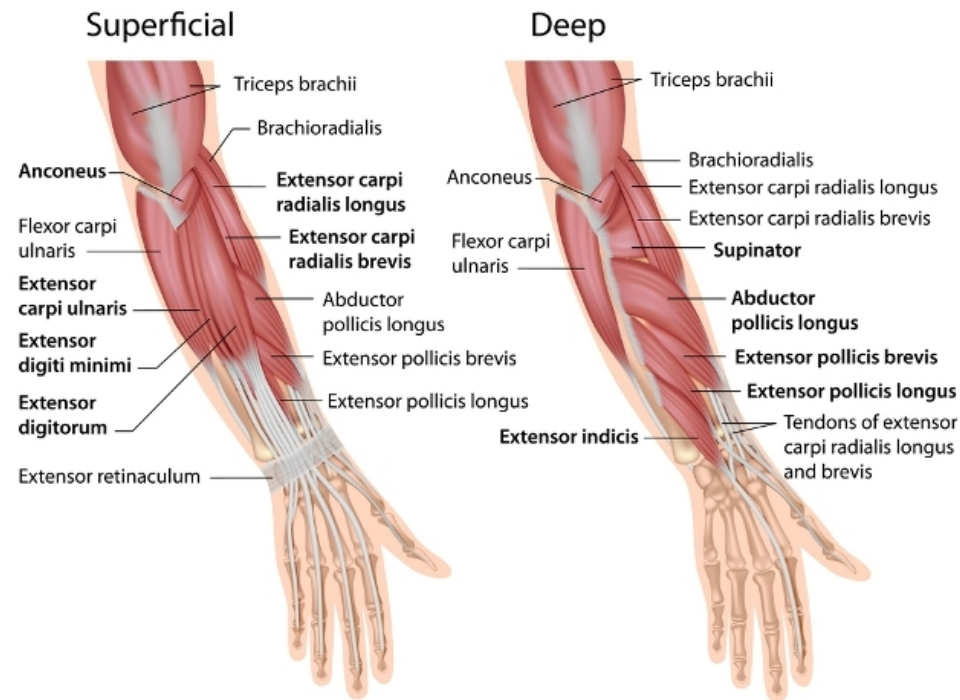


Flexor muscles of the forearm

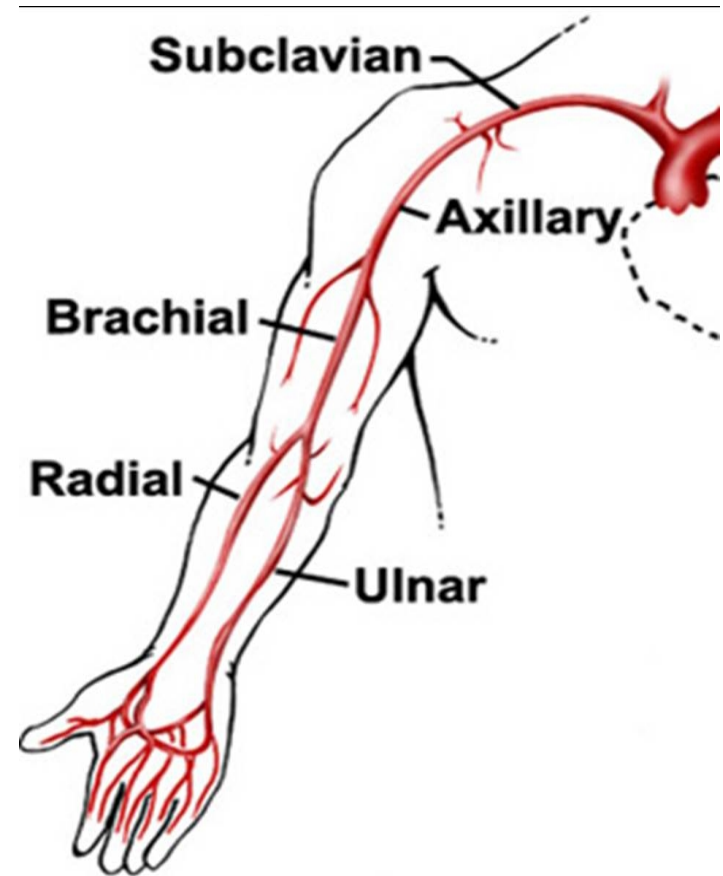
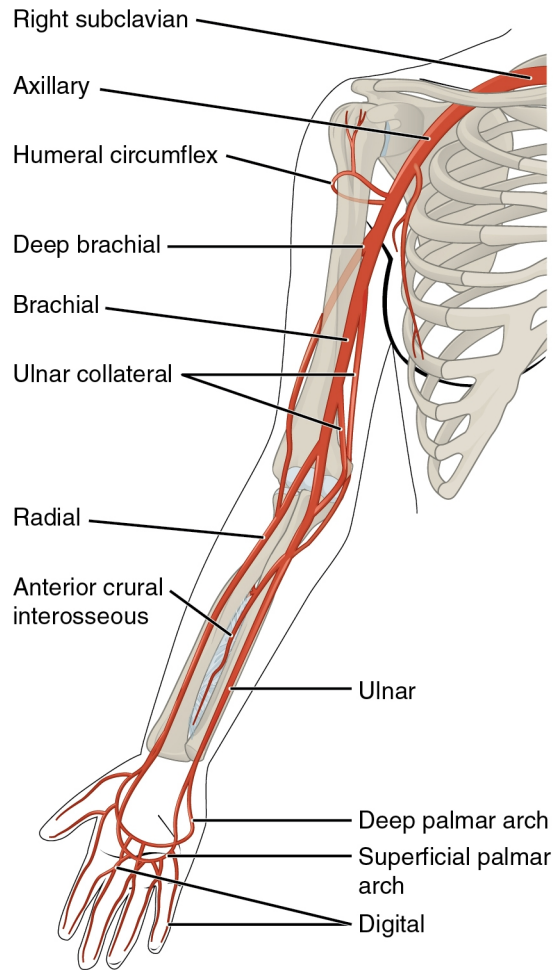


Extensor muscles of the forearm

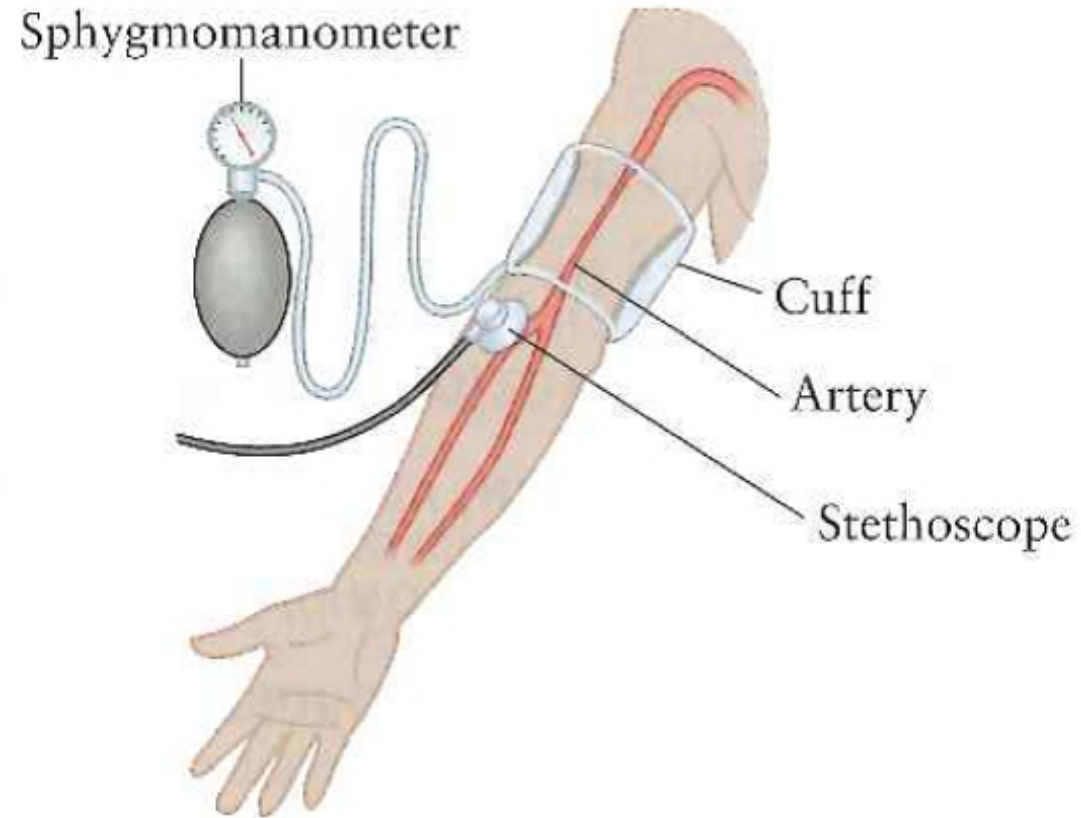
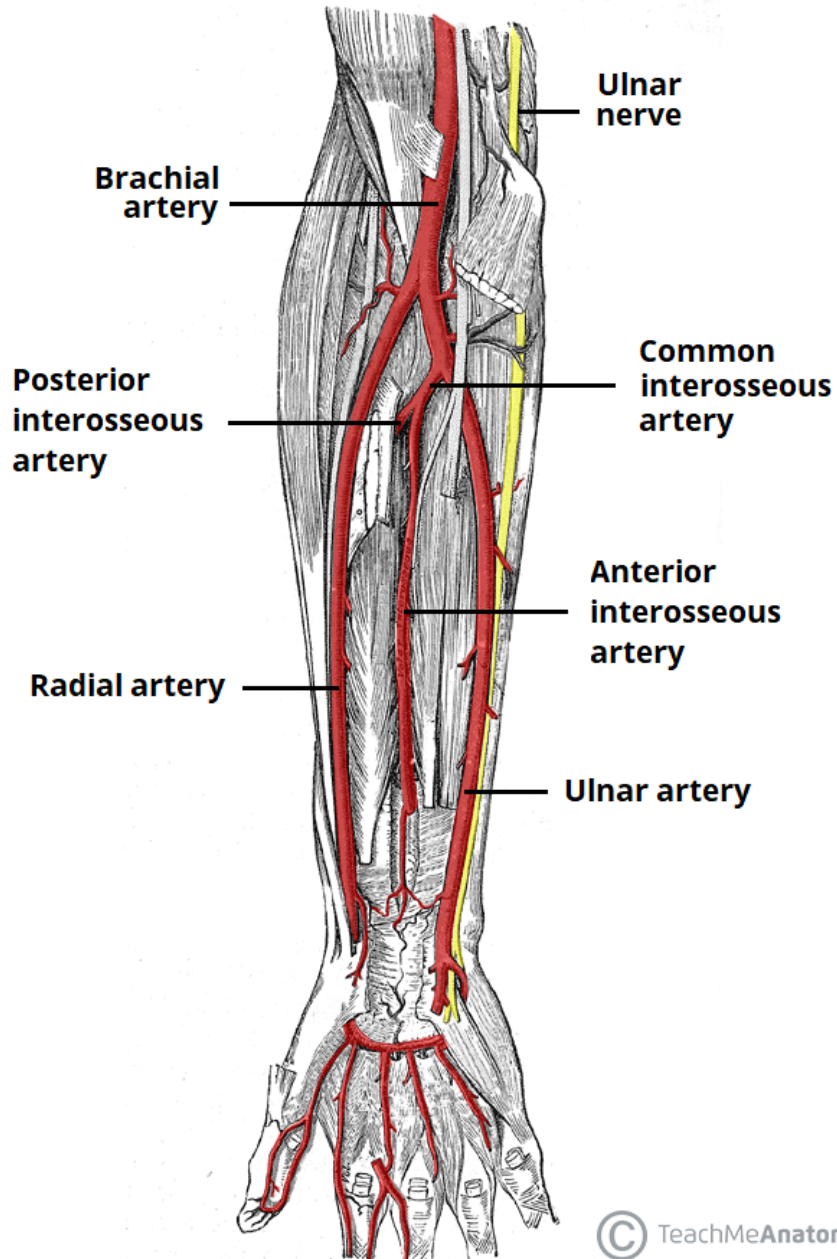
Muscles of the Forearm
(right arm, posterior compartment)



Blood supply

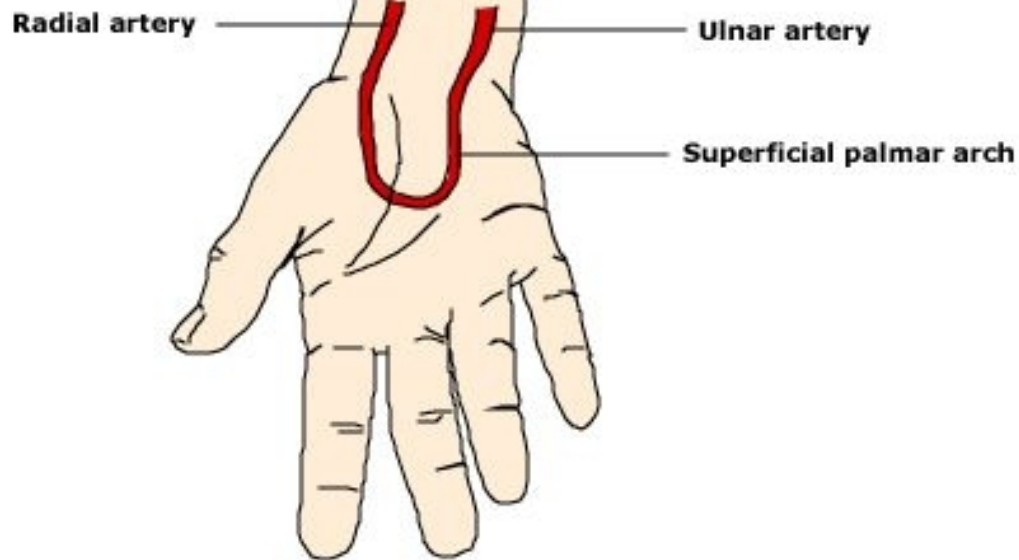
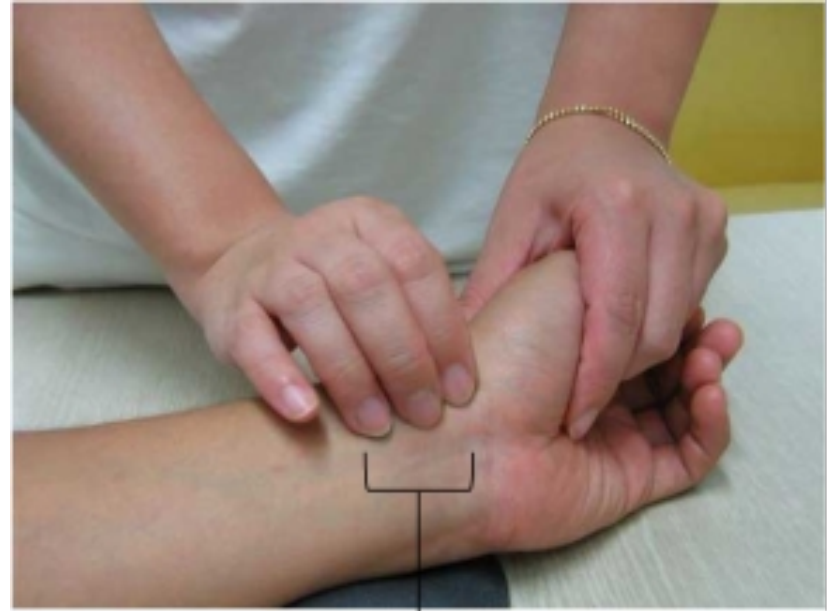
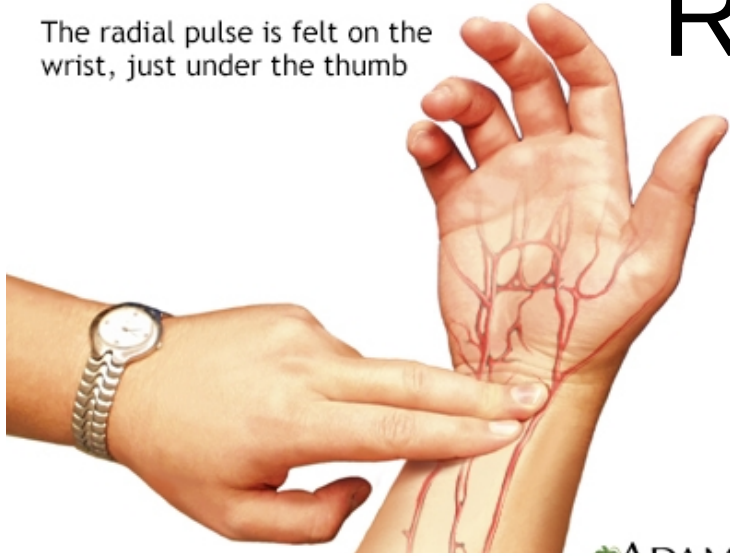
Brachial artery

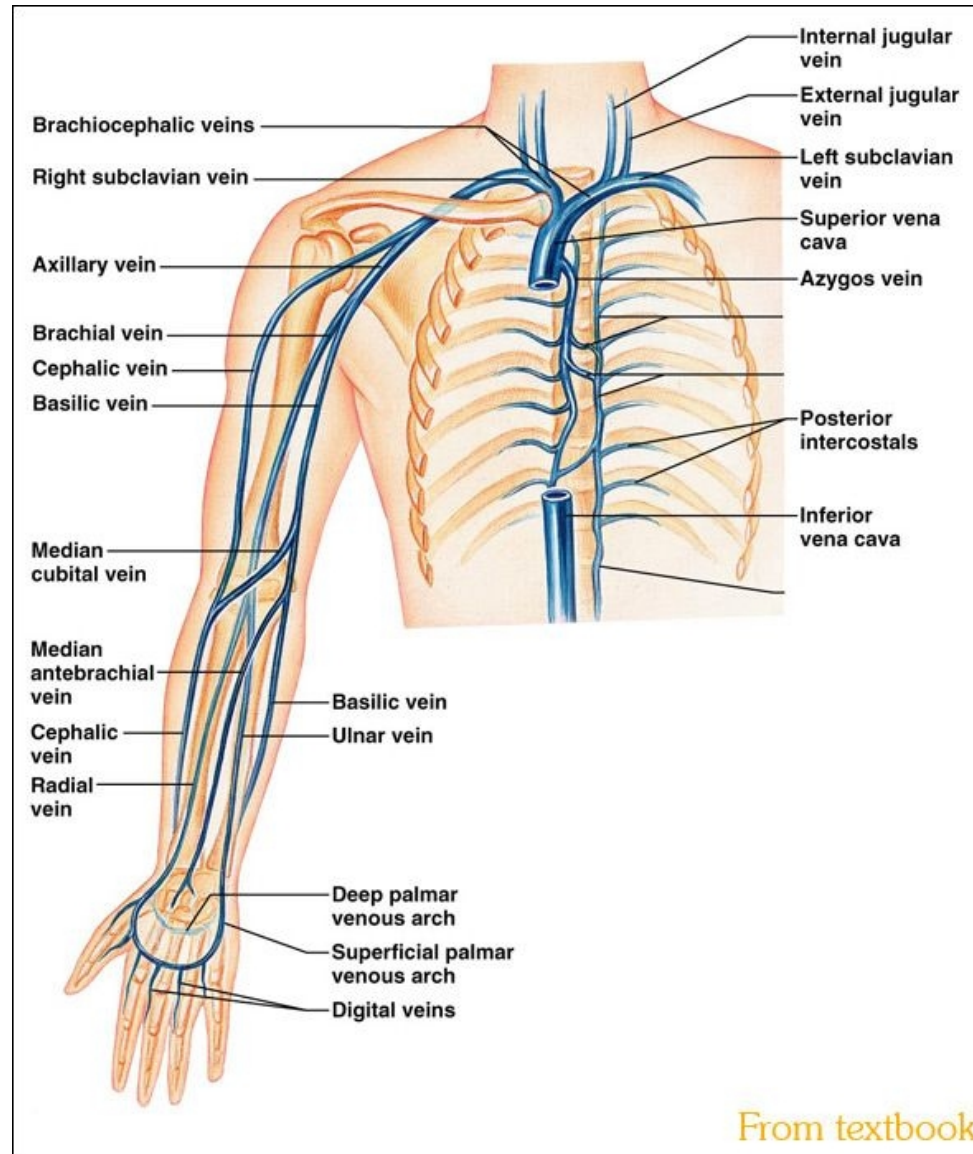


Radial artery

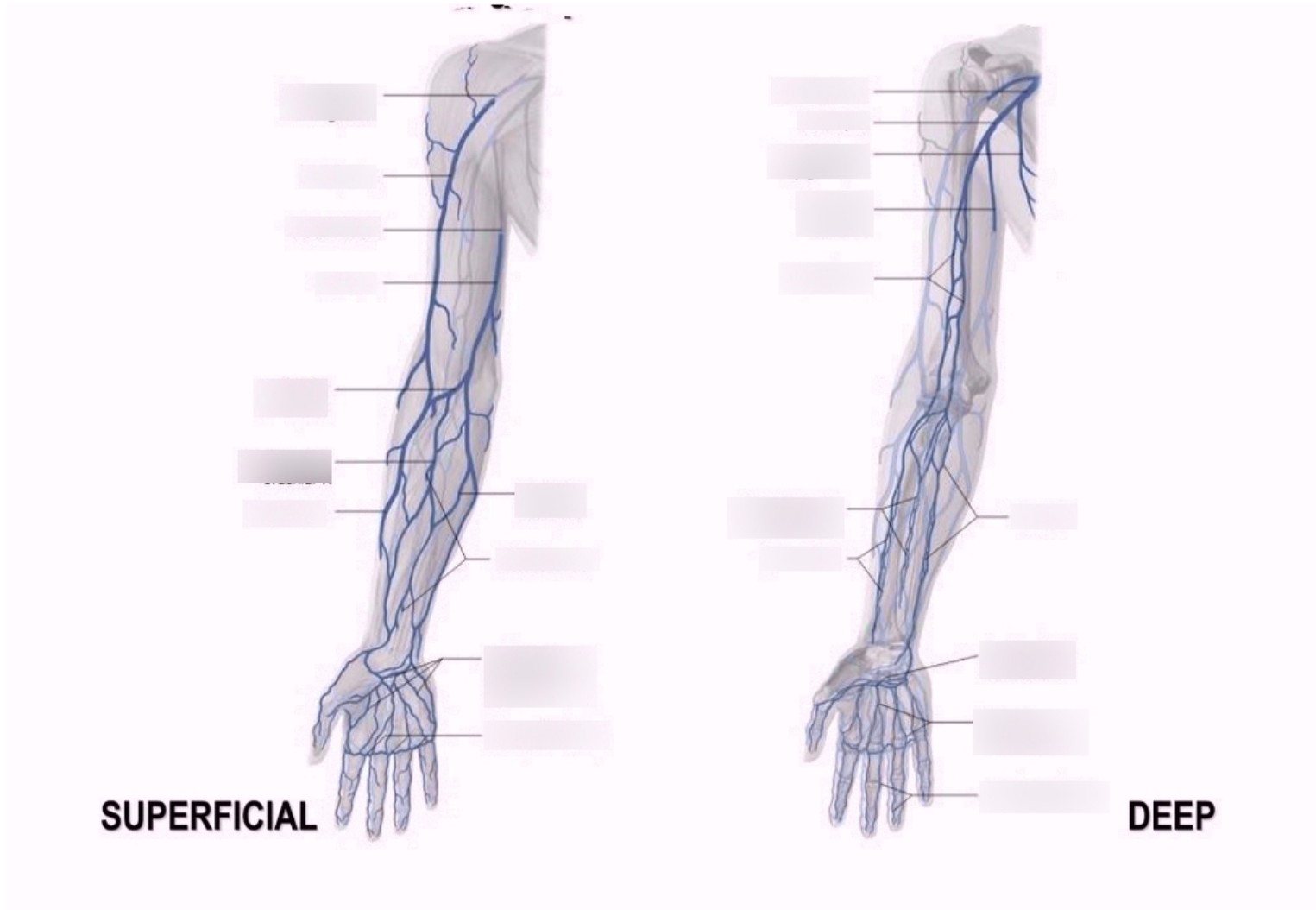
The radial pulse is felt on the wrist, just under the thumb



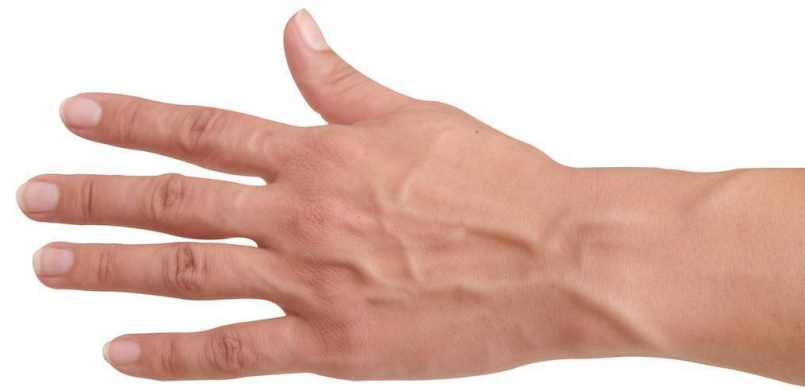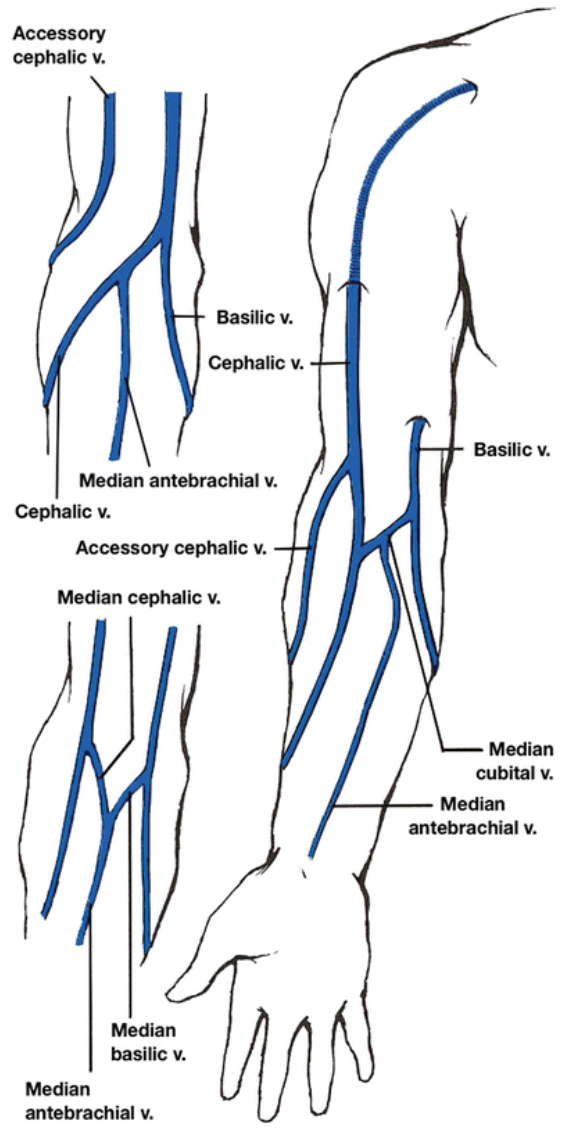
Veins



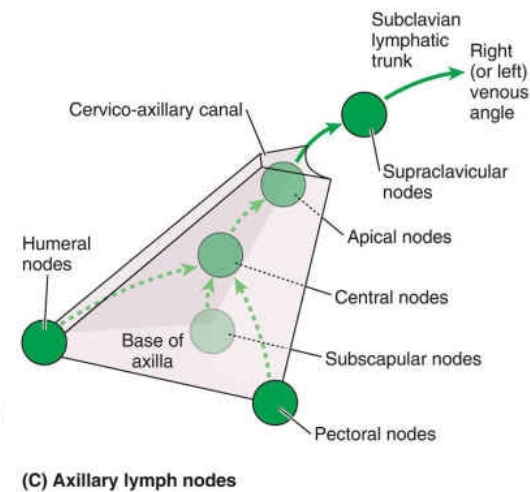
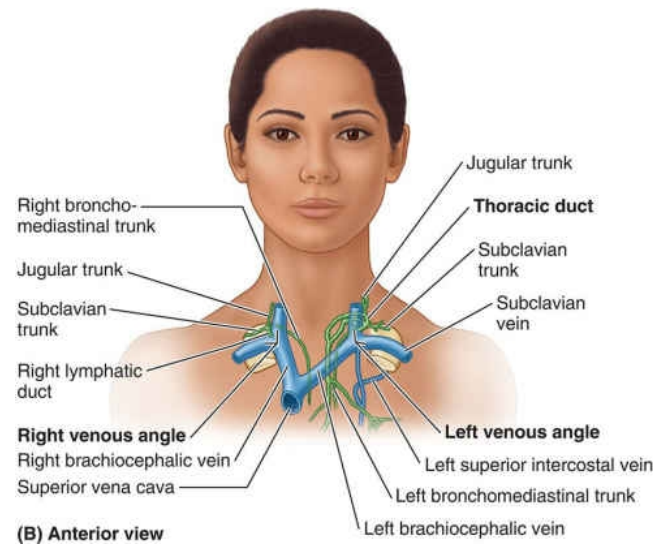
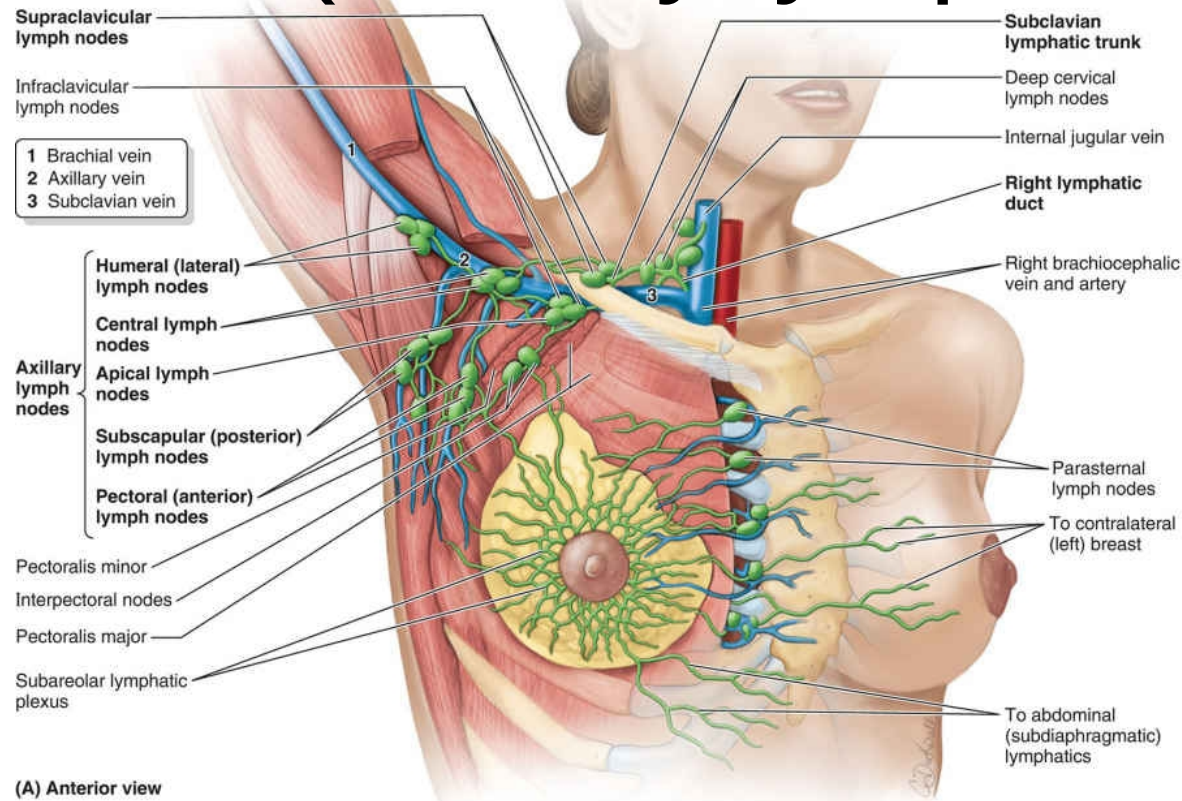
Superficial and deep veins



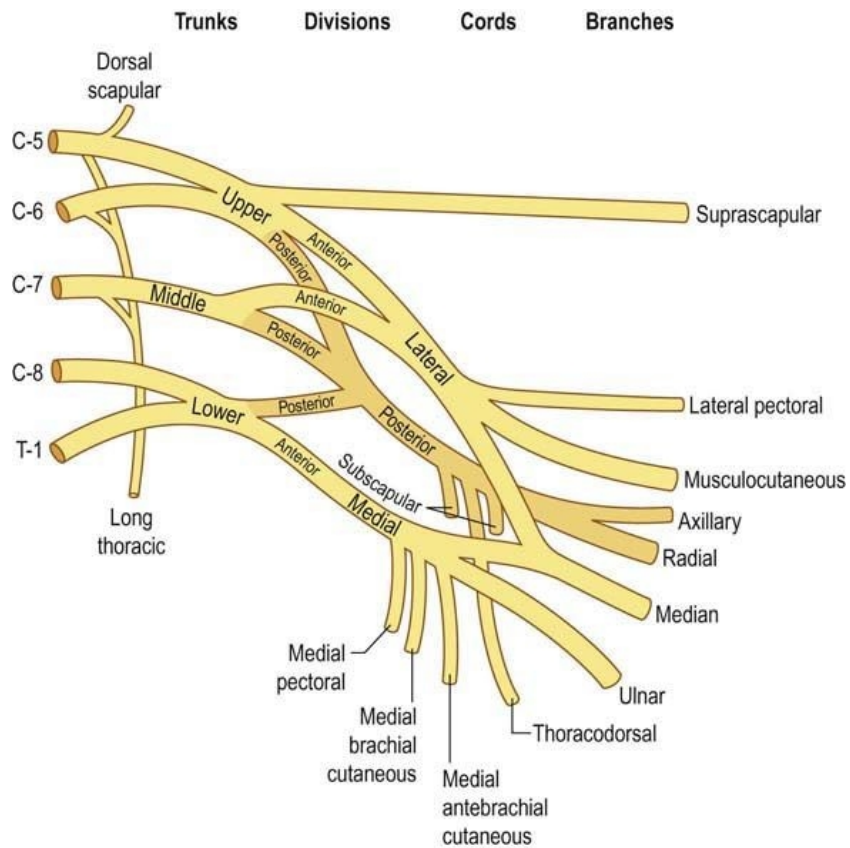
Superficial veins



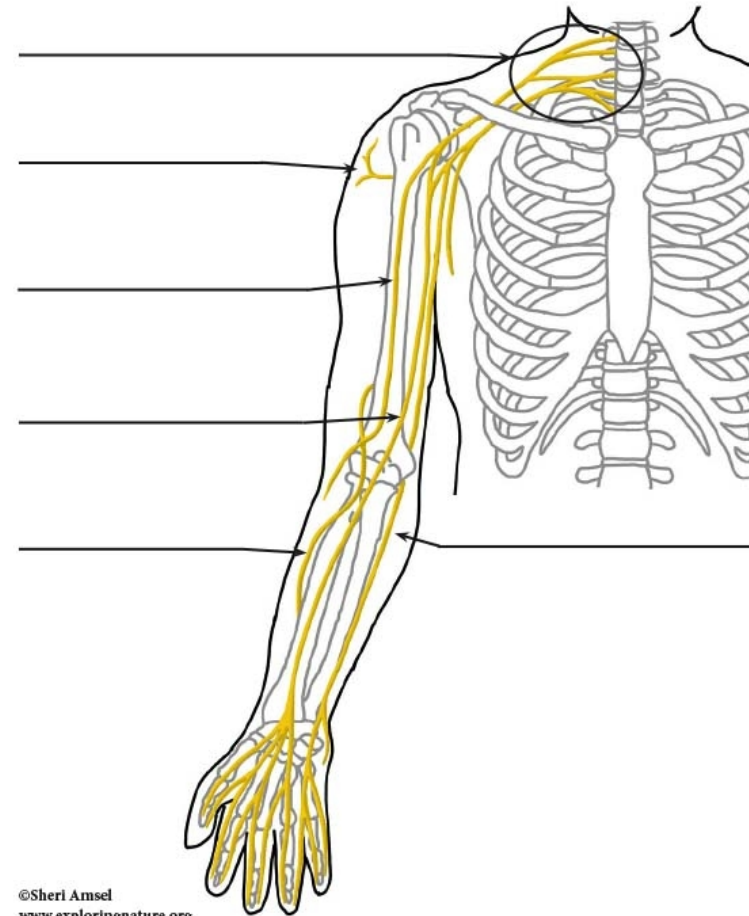
Lymphatics (Axillary lymph nodes)



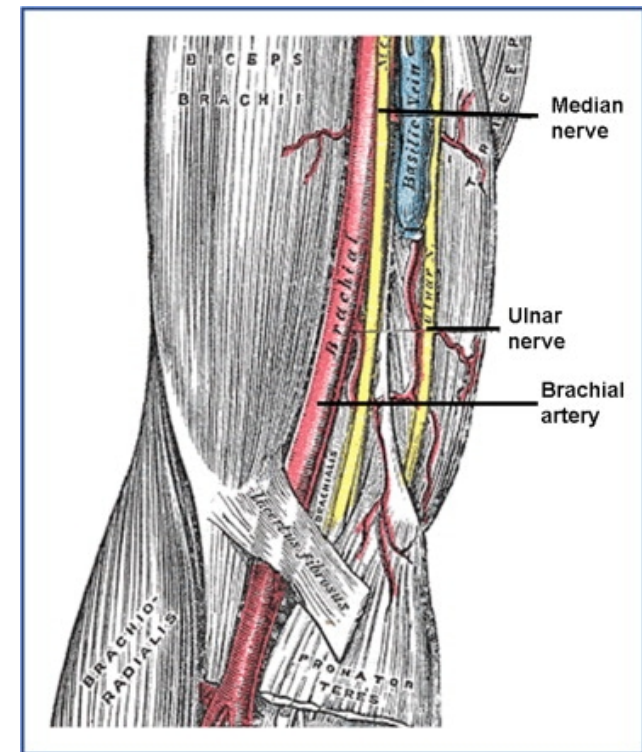
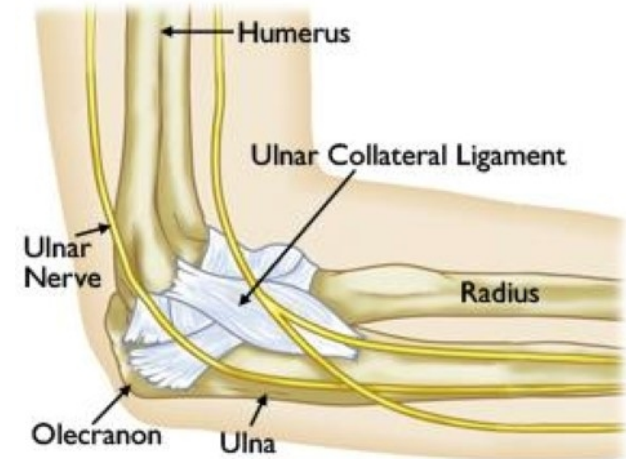
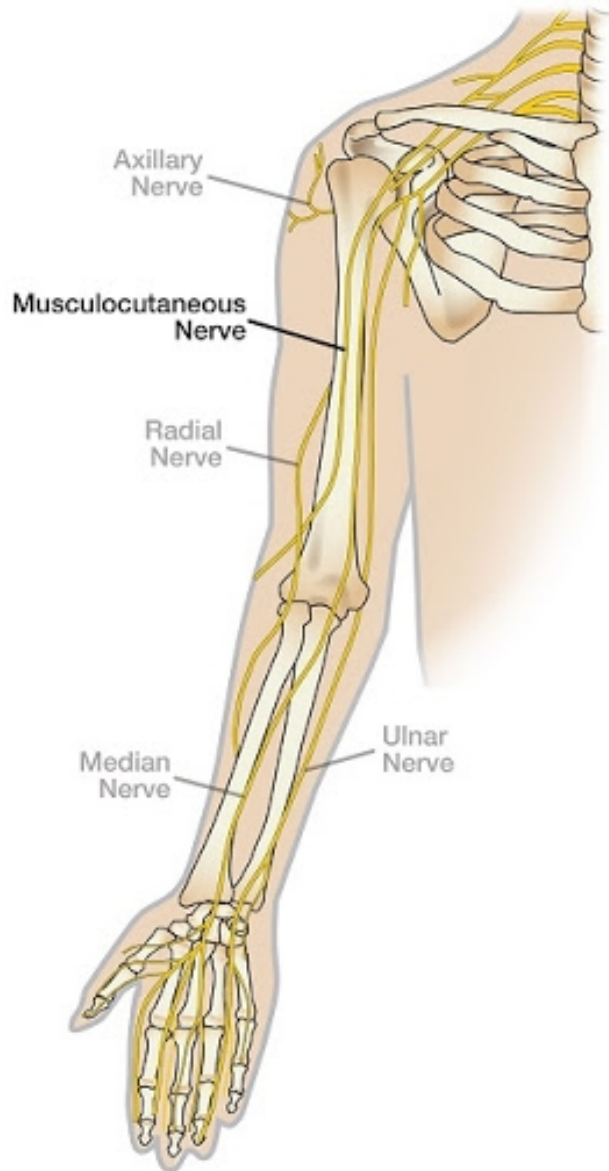
Nerve supply (origin)



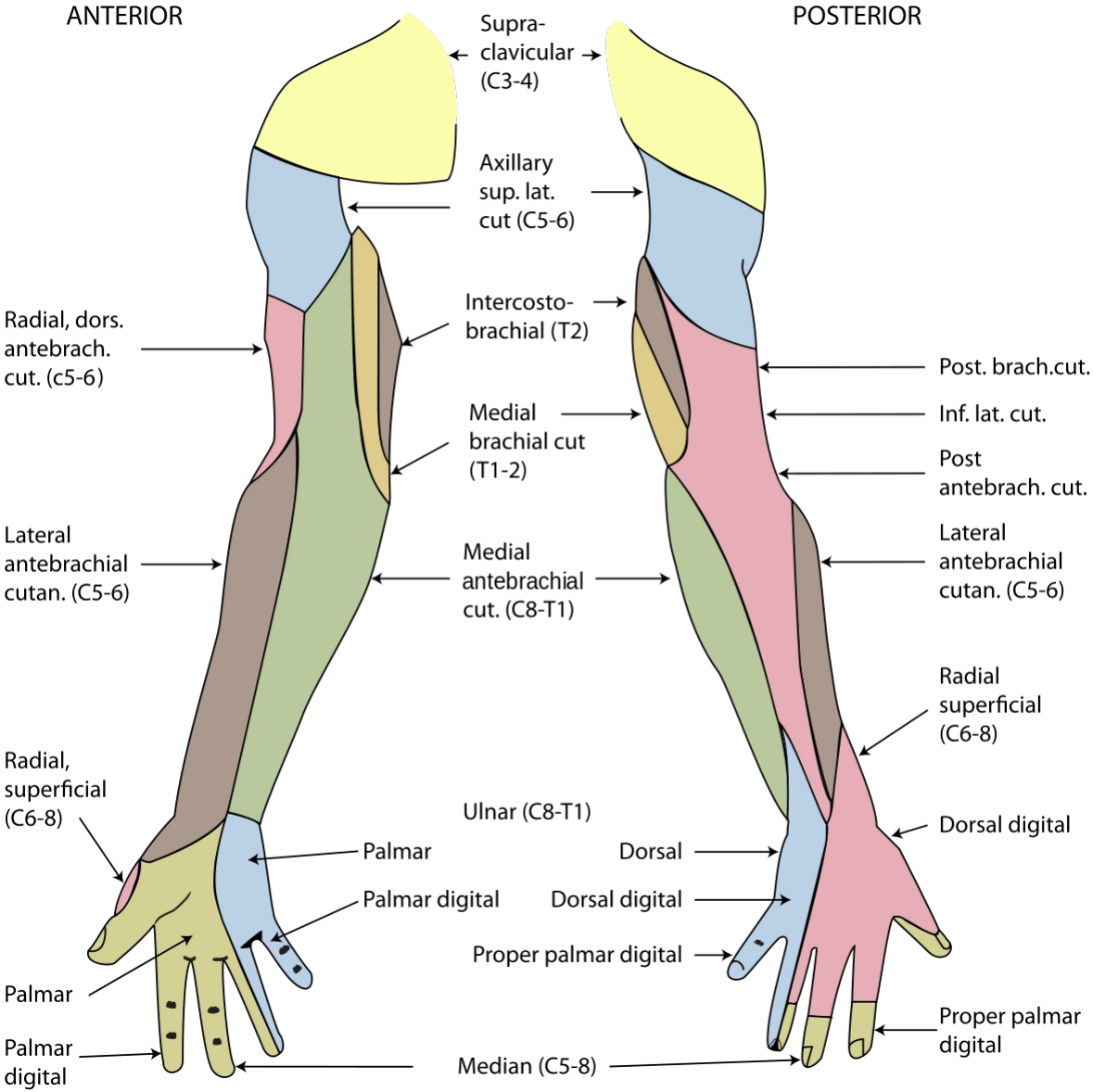
Label the Peripheral Nerves of the Neck, Shoulders and Arms



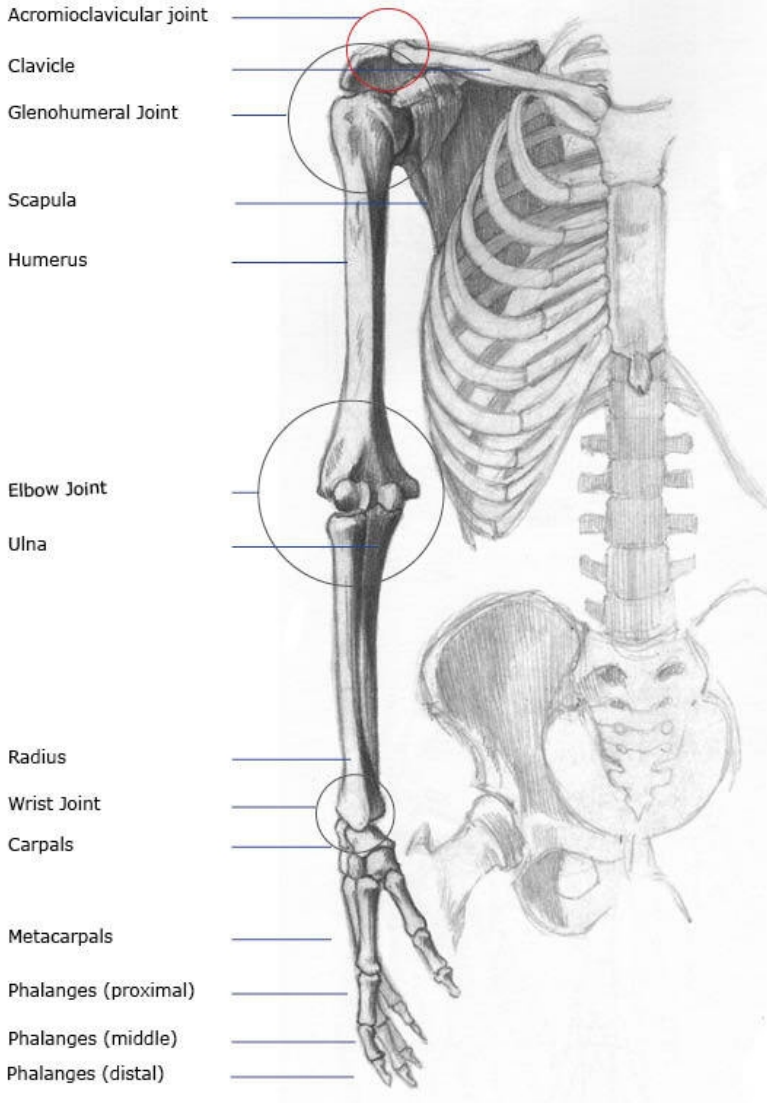
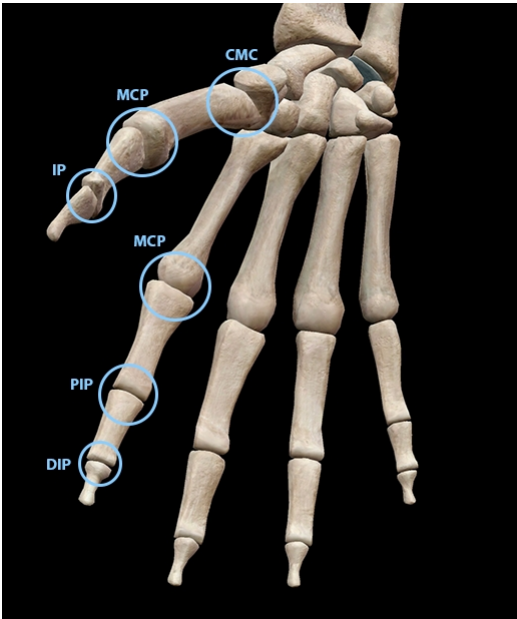
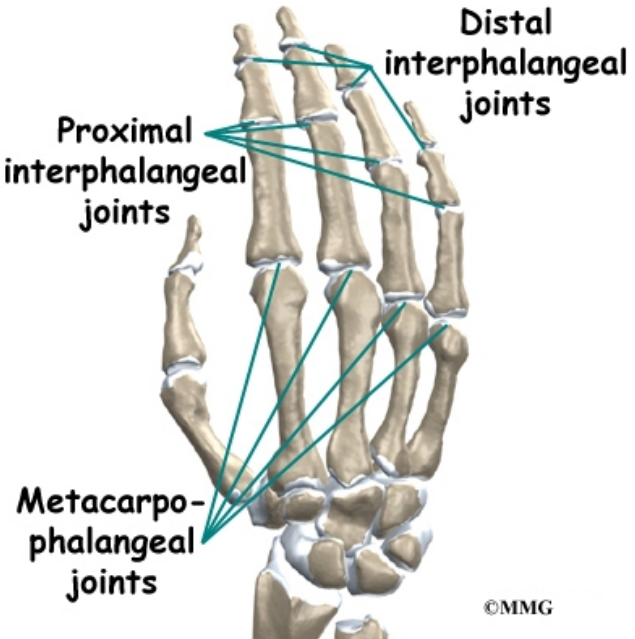
Motor and sensory nerve supply



Dermatomes (sensory nerve supply)



Joints



Thank you