



The human body consists of Four types of tissue:

- 1- Epithelial tissue
- 2- connective tissue
- 3- Muscular tissue
- 4- Nervous tissue

Epithelial tissue: is a sheet of cells that covers a body surface or lines a body cavity.

Functions of epithelia :

- 1- covering ,lining and Protection surfaces (e.g., skin)
- 2-Absorption (e.g., the intestines)
- 3-Secretion (e.g.,the epithelial cell of gland)
- 4-contraction(e.g myoepithelial cells)

Types of epithelia:

Epithelial tissues consist of two types :-

A- Covering or lining epithelial tissues

B- Glandular epithelial tissues

Covering epithelial tissues covers the outer layers or lining of the organs , according to the number of cells layers classified to:-

a-Simple epithelial tissue

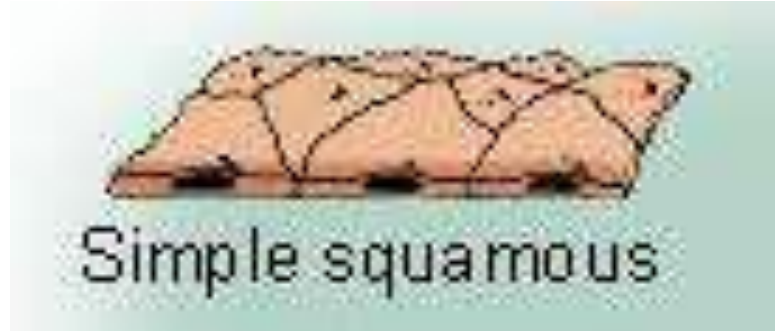
- 1-Simple squamous epithelial tissue.
- 2- Simple cuboidal epithelial tissue.
- 3- Simple columnar epithelial tissue.
- 4-pseudostratified columnar epithelial tissue.

b- Stratified epithelial tissue

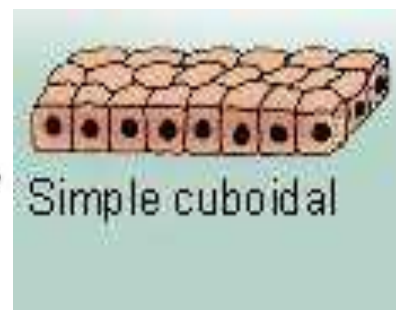
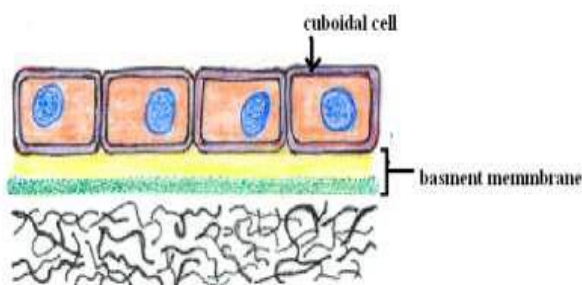
- 1- Stratified squamous epithelial tissue.
- 2- Stratified cuboidal epithelial tissue.
- 3- Stratified columnar epithelial tissue.
- 4-Transitional epithelial.

Simple epithelial tissue: -composed of only one layer based on basement membrane

1-Simple squamous epithelial tissue:- Composed of a single layer of cells which are flat and plate like , lining blood vessels being called endothelium and that lining the abdominal and plural cavities called mesothelium.

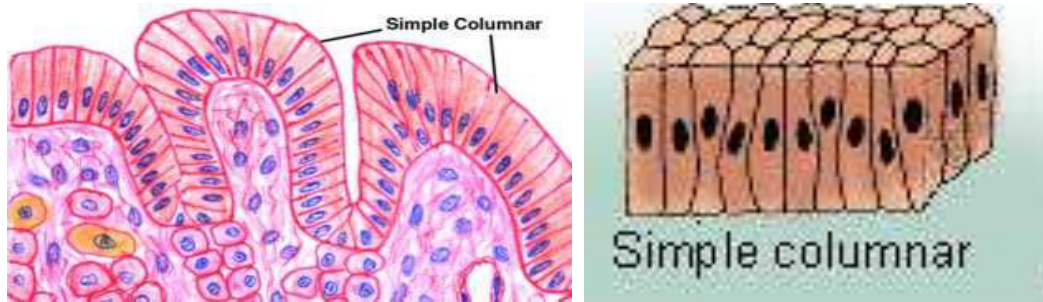


2-Simple cuboidal epithelial tissue:- Composed of a single layer of cells whose height , width and depth are the same and have centrally placed nucleus . Line small excretory ducts like proximal convoluted tubule kidney ...etc

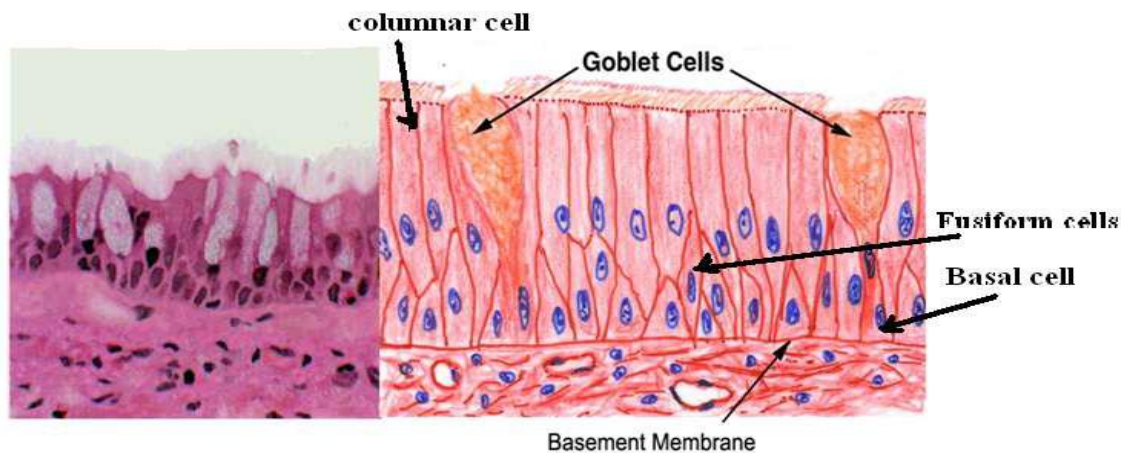


3-Simple columnar epithelial tissue :-

Composed of cells whose height 2-3 times greater than there width , the nuclei of columnar cell are basal layer ,covers the digestive organs (stomach, small and large intestine) in the small intestine its called brush border. Ciliated Simple columnar epithelial tissue found in oviducts .



4-pseudostratified columnar epithelial tissue :- Several layers of nuclei suggest several layers of cells but in fact all cells are in contact with underlining extracellular matrix and show several layer of nuclei , composed of four types of cell.



Stratified epithelial tissue :- Composed of more than one layer based on basement membrane , classified to :-

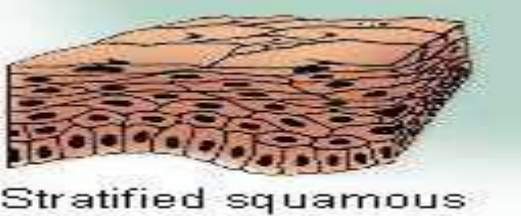
1-Stratified squamous epithelial tissue

Contains multiple cell layers , the basal cell are cuboidal to columnar , these cells give rise to cells that migrate to word the surface and become squamous .

There are two types of stratified squamous epithelial tissue:

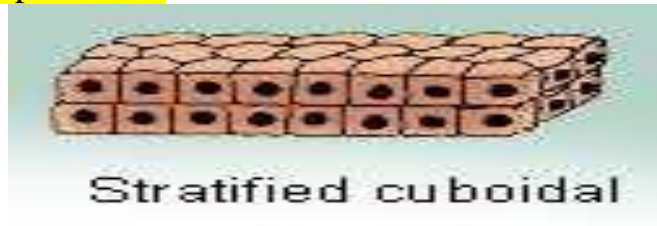-Non keratinized squamous epithelial tissue which is covering moist cavities such as mouth , esophagus , pharynxetc.

- Keratinized squamous epithelial tissue found on exposed surface of the body such as the skin .



2- Stratified cuboidal epithelial tissue :-

The surface layer cuboidal in shape , found in the large excretory ducts in the salivary glands and pancreas .

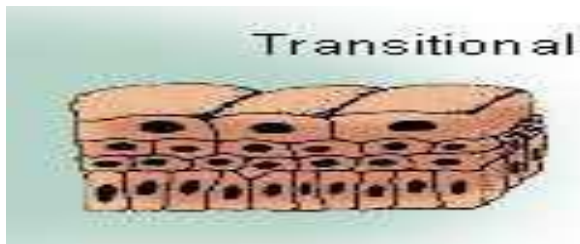


3- Stratified columnar epithelial tissue

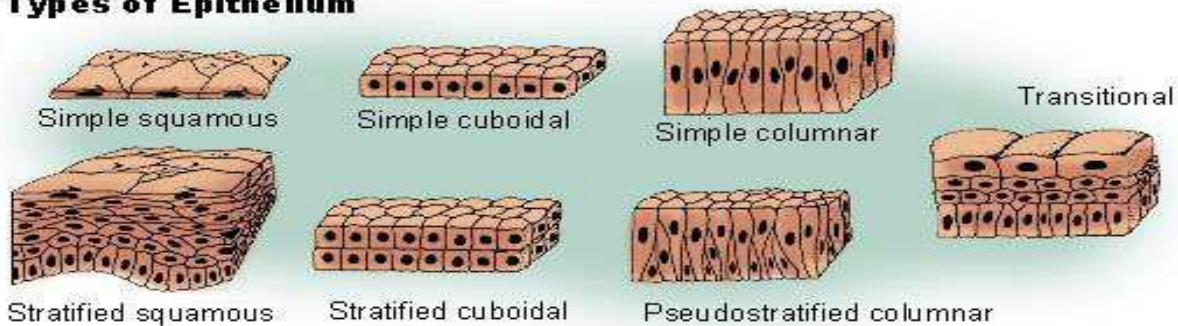
Is found in the fornix of conjunctiva while the ciliated Stratified columnar epithelial tissue is found in the larynx .

4-Transitional epithelial tissue

Is found exclusively in the passages of the urinary system . Its composed of several layer of similar cells . this type of tissue allows distention of urinary organs during urine accumulation .



Types of Epithelium



Glandular tissue :

cells or parenchyma of the glands developed from epithelial tissue , according to the methods of secreted products of gland the glandular epithelial tissues classified to :

A-Exocrine glands(excrete their product into ducts)like skin

B- Endocrine glands(secret their products direct into circulatory system)

C-Mixed glands (like pancreas)

A- **Exocrine gland** :have a secretory portion which contains the cells specialized for secretion and ducts which transport the secretion out of the gland .

According to the structure of the ducts:

- Simple(un branched).
- Compound (two or more branched).

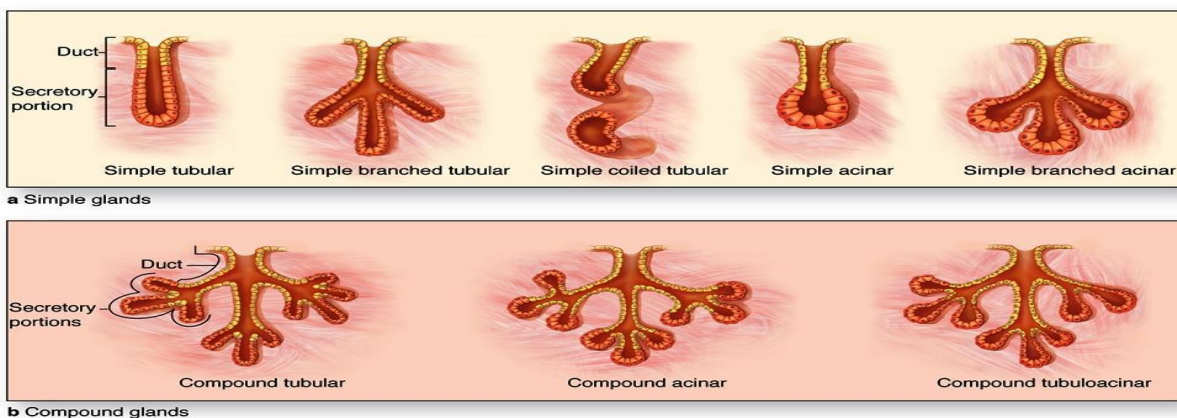
According to the structure of secretory portion :

Tubular (either short or long and coiled)

Acinar (round or globular).

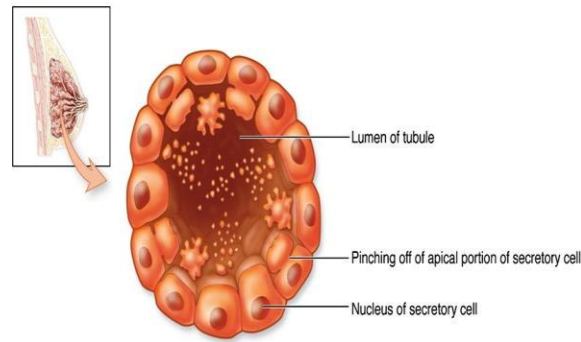
Either type of secretory portion may be branched .

Compound gland can have tubular ,acinar, tubuloacinar secretory portion

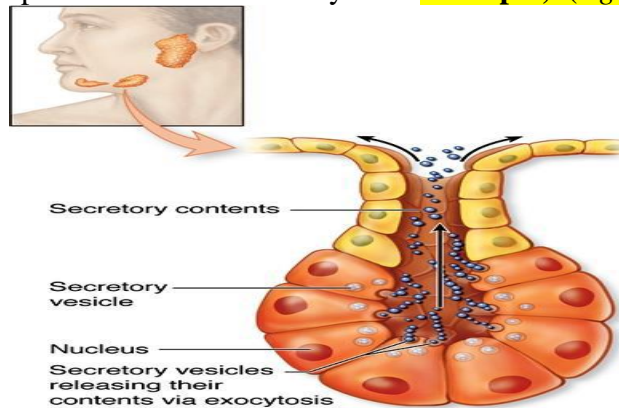


According to the way the secretory products leave the cell :

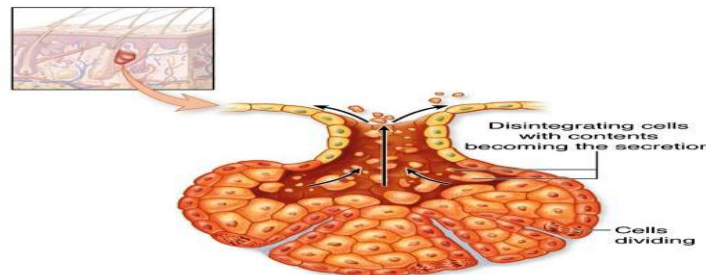
- **Apocrine** ; the secretory products is typically a large lipid droplet and is discharged together with some of the apical cytoplasm **Example; Mammary glands**



- **Merocrine / Eccrine**: secrete product usually containing proteins by means of exocytosis at the apical end of the secretory cells **Example; (e.g. salivary glands)**



- **Holocrine**: the cell filling with secretory product and then the whole cell being disrupted and shed .**Example: Sebaceous glands of skin.**



B. ENDOCRINE GLANDS

- endocrine glands have not any ducts - *ductless*
- their specific products – hormones are released directly into the bloodstream .

The major endocrine glands include:

- Pituitary, Hypothalamus, thyroid, Parathyroid, Adrenal, Pancreas, Ovary (females), Testis (males)